

Predictors of a need for cholangioscopy-guided electrohydraulic lithotripsy in the management of difficult common bile duct stones

Dionysios Kogias^a, Nikolaos Kafalis^a, Vaia Karapepera^b, Vasileios Papadopoulos^c, Georgios Kouklakis^a

Democritus University of Thrace, University Hospital of Alexandroupolis; Chatzikosta Hospital of Ioannina, Greece

Abstract

Background While standard endoscopic methods effectively clear most common bile duct stones, complex cases require specialized management. This study compared the effectiveness of cholangioscopy-guided electrohydraulic lithotripsy (EHL) against conventional techniques for treating difficult common bile duct stones (DBS).

Methods This retrospective study included 436 patients who underwent endoscopic retrograde cholangiopancreatography between April 2020 and April 2024. Demographic, laboratory and procedural data were recorded. Categorical regression identified predictors for EHL, and classification tree analysis was used to develop a prioritization algorithm.

Results Among patients with DBS (305/436, 70%), conventional methods succeeded in 28.9% (88/305). Endoscopic papillary large balloon dilation followed failed first-line techniques in 115 cases, with a 21.7% success rate. EHL was used in 192 patients, achieving a 98.4% success rate. Multivariate analysis showed that DBS ($P<0.001$), absence of wedged stones in the ampulla of Vater ($P<0.001$), and small papillae ($P=0.002$) were strong independent predictors for EHL use, with DBS being the most significant.

Conclusions DBS, absence of wedged stones in Vater and small papillae are key predictors of the need for cholangioscopy-guided EHL. Given its high success rate and comparable safety profile, EHL should be considered an early-line treatment in selected cases.

Keywords Electrohydraulic, lithotripsy, endoscopic retrograde cholangiopancreatography, choledocholithiasis, common bile duct stone

Ann Gastroenterol 2026; 39 (1): 32-39

^aFirst Department of Internal Medicine, Democritus University of Thrace, University Hospital of Alexandroupolis, Greece (Dionysios Kogias, Nikolaos Kafalis, Georgios Kouklakis); ^bOtolaryngology – Head and Neck, Chatzikosta Hospital of Ioannina, Greece (Vaia Karapepera); ^cLaboratory of Anatomy, Department of Medicine, Democritus University of Thrace, Greece (Vasileios Papadopoulos)

Conflict of Interest: None

Correspondence to: Dionysios Kogias, First Department of Internal Medicine, Democritus University of Thrace, Department of Medicine, Dragana 1, General University Hospital of Alexandroupolis, 68100, Greece, e-mail: dionkogi@gmail.com

Received 19 August 2025; accepted 27 November 2025; published online 12 December 2025

DOI: <https://doi.org/10.20524/aog.2026.1026>

This is an open access journal, and articles are distributed under the terms of the Creative Commons Attribution-NonCommercial-ShareAlike 4.0 License, which allows others to remix, tweak, and build upon the work non-commercially, as long as appropriate credit is given and the new creations are licensed under the identical terms.

Introduction

Endoscopic retrograde cholangiopancreatography (ERCP) was first described 55 years ago as the primary intervention for biliopancreatic diseases [1]. However, its reliance on fluoroscopy limits direct visualization of the biliary tree. Peroral cholangioscopy offers direct visualization of the biliopancreatic tree [2,3], while the digital SpyGlass system (Boston Scientific Endoscopy, Marlborough, MA, USA) offers enhanced image quality and a wider field of view [4,5].

Choledocholithiasis, the most frequently encountered biliary disorder managed by endoscopists, is observed in approximately 10-18% of individuals presenting with symptoms of cholelithiasis [6]. The standard treatment involves ERCP with endoscopic sphincterotomy, followed by stone extraction via balloon or basket [7]. Some cases require additional techniques, including extended sphincterotomy, ampullary dilation or smaller catheters [6]. Difficult bile duct stones (DBS) are characterized by their large size (>1.5 cm), impaction, intrahepatic location, hardness, strictures or anatomical anomalies [8].

Electrohydraulic lithotripsy (EHL) performed under cholangioscopic guidance is a viable option for the management of DBS [9,10]. Indications for cholangioscopy-guided EHL include large or multiple bile duct stones, intrahepatic bile duct stones, stones at the bile duct confluence, and the presence of bile duct strictures. Once fragmentation is achieved, the bile duct stones are removed using conventional techniques, such as balloon or basket catheters [11]. In this study, considering the increasing use of cholangioscopy and EHL, we analyzed the characteristics of patients with choledocholithiasis and proposed an algorithm to prioritize cholangioscopy-guided EHL over conventional techniques for bile duct clearance.

Patients and methods

Study population and data collection

This retrospective analysis of prospectively collected data included all consecutive patients who underwent ERCP for choledocholithiasis at the First Department of Internal Medicine or the Gastroenterology Outpatient Clinic of the University General Hospital of Alexandroupolis (Greece) between April 2020 and April 2024. Patients presenting with symptoms of choledocholithiasis or cholangitis were initially evaluated using abdominal ultrasound and/or magnetic resonance cholangiopancreatography (MRCP) prior to ERCP. A total of 436 patients met the inclusion criteria. Comprehensive records were kept of all procedures, demographics, imaging and laboratory findings. The study was conducted in accordance with the regulations of the Bioethics Committee of the University General Hospital of Alexandroupolis (Ethics Approval No. 13619), and informed consent was obtained from all participants.

ERCP and cholangioscopy-guided EHL procedure

The size and impaction of the stones were initially evaluated using MRCP in all patients. Extraction of common bile duct stones that were not classified as difficult (size >1.5 cm and/or impaction) was initially managed through endoscopic sphincterotomy, followed by conventional techniques, such as balloon and basket extraction [12-14]. When standard methods failed to clear DBS, multiple sessions and advanced interventions were employed, including large-balloon dilation, cholangioscopy-assisted EHL, or temporary plastic stent placement followed by repeat ERCP. Standard sphincterotomy, with or without subsequent endoscopic papillary large-balloon dilation (EPLBD), served as a second-line approach. If unsuccessful, cholangioscopy-guided EHL was used as third-line therapy. Stent placement with delayed ERCP was reserved for cases in which EHL failed. Complications were monitored via laboratory assessments, including amylase, lipase and hemoglobin levels. Pancreatitis was defined by characteristic pain and enzyme levels exceeding 3 times the normal upper limit. Bleeding was identified through endoscopic observation

or a hemoglobin drop >2 g, with or without hematemesis or melena [15]. No cases of cholangitis were reported among the study participants. Anatomical variations included duodenal diverticula, small papillae, and papillae located behind mucosal folds. No patients presented with surgically altered anatomy or other structural anomalies that affected endoscopic evaluation. Cholangioscopy-guided EHL was performed using the SpyGlass™ DS II Direct Visualization System (Boston Scientific Endoscopy, Marlborough, MA, USA). Both patient preparation and procedural technique followed established clinical guidelines and the manufacturer's instructions for use of the SpyGlass system.

Statistical analysis

Continuous variables were expressed as means and standard deviations (SD), and compared using Student's *t*-test when equal variances could be assumed; otherwise, Welch's *t*-test was preferred. Discrete variables were expressed as percentages and compared using the chi-square test; in case of expected frequencies <5 in ≥25% of cells, Fisher's exact test was applied. In a multivariate analysis, categorical regression was used to assess the use of age, sex, regional anatomy and stone type as potential prognosticators in prioritizing cholangioscopy-guided EHL. More specifically, optimal scaling after maximal discretization (up to 7 categories), ridge regression, and 10× cross-validation was implemented with the aid of the CATREG SPSS procedure; to avoid multicollinearity issues, the minimum tolerance was set to 0.8. The formula that calculates the probability *p* of a need for cholangioscopy-guided EHL is $p = 1/[1 + e^{-LP}]$, where LP is the linear predictor, such as $LP = (b_1 \times q_1) + (b_2 \times q_2) + \dots + (b_n \times q_n)$, and b_1, b_2, \dots, b_n and q_1, q_2, \dots, q_n are the standardized coefficients and quantification factors, respectively. Consequently, the odds ratio (OR) of the need for cholangioscopy-guided EHL vs. the need for the other techniques is given by the formula $OR = e^{LP}$, while the 95% confidence intervals lie between $e^{(LP-1.96SE)}$ and $e^{(LP+1.96SE)}$; SE is given by the formula $\{ [SE(b_1) \times q_1]^{1/2} + [SE(b_2) \times q_2]^{1/2} + \dots + [SE(b_n) \times q_n]^{1/2} \}^{1/2}$, where SE₁, SE₂, ..., SE_n are the standard errors of the standardized coefficients. A classification tree was further used to develop an algorithm for proposing cholangioscopy-guided EHL as first-choice treatment, based on prognosticators assessed by the most parsimonious multivariate categorical regression model, as described above. The level of statistical significance was set to 0.05. All tests were performed using SPSS 26.0. Forest plot visualization was generated using RevMan 5.3.

Results

Overall characteristics of patients

Of the 436 patients included in the study, 206 (47.2%) were male and 230 (52.8%) were female. The mean age was

62.3±14.3 years, with a range of 24-90 years. Anatomical variations included the presence of a duodenal diverticulum in 94 patients (21.6%), a small papilla in 39 patients (8.9%), and a papilla located behind a fold in 44 patients (10.1%). DBS were identified in 305 patients (70.0%) and a wedged stone in the ampulla of Vater was observed in 54 patients (12.4%). For patients with non-difficult bile duct stones, treatment with conventional techniques was predominantly successful (93.9%) (Supplementary Fig. 1).

Cannulation

Standard cannulation was successful in 348 of 436 patients (79.8%). A small catheter was used in 25 patients with a 64% success rate. In 87 patients where both standard and small-catheter cannulation failed, precut sphincterotomy was effectively applied. Extended sphincterotomy was required in 33 patients following unsuccessful standard sphincterotomy, achieving stone clearance in 16 cases (48.5%).

DBS

Among 305 patients with DBS, conventional techniques achieved successful stone extraction in 88 cases (28.9%). The remaining 217 underwent second-line interventions—EPLBD (n=115) or cholangioscopy-guided EHL (n=97)—with an additional 90 patients receiving EHL after failed EPLBD, totaling 187 EHL procedures. The 2 groups were comparable in size, with a ratio of approximately 1.19:1. A temporary plastic

stent was used in 5 cases (Supplementary Fig. 1). EPLBD achieved success in 25 of 115 patients (21.7%). All 90 patients who required EHL post-EPLBD had successful outcomes (100%). As a second-line intervention, EHL was successful in 94 of 97 cases (96.9%). Stent placement was successful in all cases where used. Stone analysis showed 141 patients (46.2%) had large stones only, 140 (45.9%) had multiple or impacted stones, and 24 (7.9%) had both. Conventional techniques succeeded in 13.5% of patients with large stones, 42.9% with multiple/impacted stones, and 37.5% with both (Supplementary Fig. 1).

Cholangioscopy-guided EHL

To assess the impact of cholangioscopy-guided EHL, patients were divided into 2 groups: those in whom the technique was not attempted (n=244) and those in whom it was (n=192) (Table 1). Conventional techniques were used in 86% of the non-EHL group and all cases in the EHL group (P<0.001). EPLBD was attempted in 11% and 77%, respectively (P<0.001). No significant differences were found in age (P=0.070), sex (P=0.194) or the presence of duodenal diverticula (P=0.574). Anatomical factors, such as a papilla behind a fold (P=0.034), small papilla (P=0.003) and DBS (P<0.001), were more common in the EHL group. Large stones (P<0.001) and multiple or impacted stones (P<0.001) were also more frequent in this group. Wedged stones in the ampulla of Vater were more prevalent in the non-EHL group (65% vs. 10%, P=0.162). There were no significant differences in complications, including amylasemia (P=0.503), pancreatitis (P=0.460) or bleeding (P=0.249). Categorical regression with

Table 1 Characteristics of patients (n; %) according to attempted cholangioscopy-guided electrohydraulic lithotripsy (EHL)

Characteristics	Cholangioscopy-guided EHL not attempted (n=244)	Cholangioscopy-guided EHL attempted (n=192)	Total (n=436)	P-value
Prior attempted techniques				
Conventional techniques	211 (86)	192 (100)	403 (92)	<0.001
EPLDB	27 (11)	92 (77)	119 (27)	<0.001
Demographics				
Age	61.2±14.2	63.8±14.4	62.3±14.3	0.070
Male sex	122 (50)	108 (56)	230 (53)	0.194
Anatomical characteristics				
Duodenal diverticulum	55 (23)	39 (20)	94 (22)	0.574
Papilla behind a fold	18 (7)	26 (14)	44 (10)	0.034
Small papilla	13 (5)	26 (13)	39 (9)	0.003
Bile duct stone characteristics				
Difficult bile duct stones	118 (48)	187 (97)	305 (70)	<0.001
Large stones	53 (22)	112 (58)	165 (38)	<0.001
Multiple/impacted stones	74 (30)	90 (47)	164 (38)	<0.001
Large and multiple/impacted stones	9 (4)	15 (8)	24 (6)	0.061
Wedged stone in Vater	35 (65)	19 (10)	54 (12)	0.162
Complications				
Amylasemia	40 (16)	27 (14)	67 (15)	0.503
Pancreatitis	7 (2)	8 (4)	15 (3)	0.460
Bleeding	2 (1)	5 (3)	7 (2)	0.249 [†]

[†]Fisher's exact test

optimal scaling (Table 2) identified DBS ($P<0.001$), absence of wedged stones ($P<0.001$), and small papillae ($P=0.002$) as independent predictors for cholangioscopy-guided EHL. Age, sex, duodenal diverticulum and papilla position were not significantly associated.

Prioritizing cholangioscopy-guided EHL

The classification tree in Fig. 1 illustrates a stepwise decision model prioritizing the parameters for selecting cholangioscopy-guided EHL as the first-choice treatment for bile duct stones. This model evaluates clinical and anatomical factors, identifying patients who benefit most from EHL. Among patients with DBS ($n=305$), the presence of a stone wedged in the ampulla of Vater emerged as the next critical factor ($P<0.001$), while for patients without wedged stones ($n=251$) the presence of a small papilla was the next significant predictor ($P<0.001$), confirming the hierarchical significance of DBS, wedged stones in Vater and small papilla in predicting the need for cholangioscopy-guided EHL.

Supplementary Table 1 displays the ORs for the use of cholangioscopy-guided EHL in relation to the presence or absence of each single prognosticator, neglecting the remaining ones. The need for cholangioscopy-guided EHL was positively correlated with the presence of DBS (OR 1.57, 95%CI 1.46-2.02) and small papilla (OR 1.27, 95%CI 1.26-1.37), while the absence of these conditions reduced the probability of EHL use (OR 0.64, 95%CI 0.49-0.69 and OR 0.79, 95%CI 0.73-0.84, respectively). In contrast, the presence of a wedged stone in the ampulla of Vater decreased the EHL likelihood (OR 0.70, 95%CI 0.68-0.75) while its absence elevated it (OR 1.43, 95%CI 1.33-1.48). All 8 unique predictive combinations resulting from the presence or absence of these 3 prognostic factors (DBS, wedged stone, small papilla) are illustrated in Fig. 2. These ORs were calculated from the data presented in Table 2 and implement the clinical strategy presented in Fig. 1. The highest prioritization for EHL was consistently observed in cases combining DBS with the absence of a wedged stone, irrespective of papilla size (OR 1.72, 95%CI 1.46-2.02 and OR 1.32, 95%CI 1.26-1.37).

The independent factors driving the use of cholangioscopy-guided EHL were determined through ridge regression applied to a binary model (Fig. 3). The presence of DBS was the primary determinant, reflected by its largest coefficient across all regularization intensities. A small papilla and a wedged stone in the ampulla of Vater also proved to be significant predictors, with their respective coefficients remaining robust and stable as regularization increased. Papilla located behind a fold and the presence of a duodenal diverticulum showed more moderate coefficients and contributed less to the predictive outcome. In contrast, age and male sex were shown to be minimally influential, as their coefficient values diminished substantially towards zero with increased regularization.

Discussion

This study develops a novel predictive framework that utilizes key pre- and intraprocedural factors to prioritize cholangioscopy-guided EHL. As a European healthcare provider, it adheres to the therapeutic guidelines established by the European Society of Gastrointestinal Endoscopy (ESGE), which are closely aligned with the relevant international guidelines. However, based on extensive experience in managing DBS cases, the institution adopts second- and third-line techniques earlier in treatment.

Extraction of common bile duct stones that are not classified as difficult is typically managed via endoscopic sphincterotomy, followed by balloon and/or basket extraction [12]. However, standard techniques often fail to clear DBS, requiring multiple procedures and advanced methods, such as large-balloon dilation, mechanical lithotripsy, cholangioscopy-assisted electrohydraulic or laser lithotripsy, or extracorporeal shock wave lithotripsy [12]. ESGE guidelines recommend standard sphincterotomy followed by EPLBD—or EPLBD after sphincterotomy—as first-line treatment. If unsuccessful, cholangioscopy-guided EHL is suggested as a third-line option. Should EHL fail, temporary plastic stent insertion with a follow-up ERCP is suggested.

Table 2 Binary regression model with optimal scaling assessing the parameters that are independently correlated with the use of cholangioscopy-guided EHL

Variable	Beta	Quantification factor	SE(b)	F	P-value	Tolerance
Difficult bile duct stones	$b_1=0.383$	$q_1=0.655$ for “Yes”; 1.526 for “No”	0.023	278.980	<0.001	0.865
Wedged stone in Vater	$b_2=0.128$	$q_2=-2.660$ for “Yes”; 0.376 for “No”	0.033	15.505	<0.001	0.842
Small papilla	$b_3=0.076$	$q_3=3.191$ for “Yes”; 0.313 for “No”	0.025	9.404	0.002	0.964
Duodenal diverticulum	0.042	NA	0.027	2.522	0.113	0.953
Age	0.037	NA	0.027	1.855	0.174	0.902
Male sex	0.022	NA	0.021	1.165	0.281	0.907
Papilla behind a fold	0.011	NA	0.020	0.309	0.579	0.842

EHL, electrohydraulic lithotripsy; SE, standard error; NA, not applicable

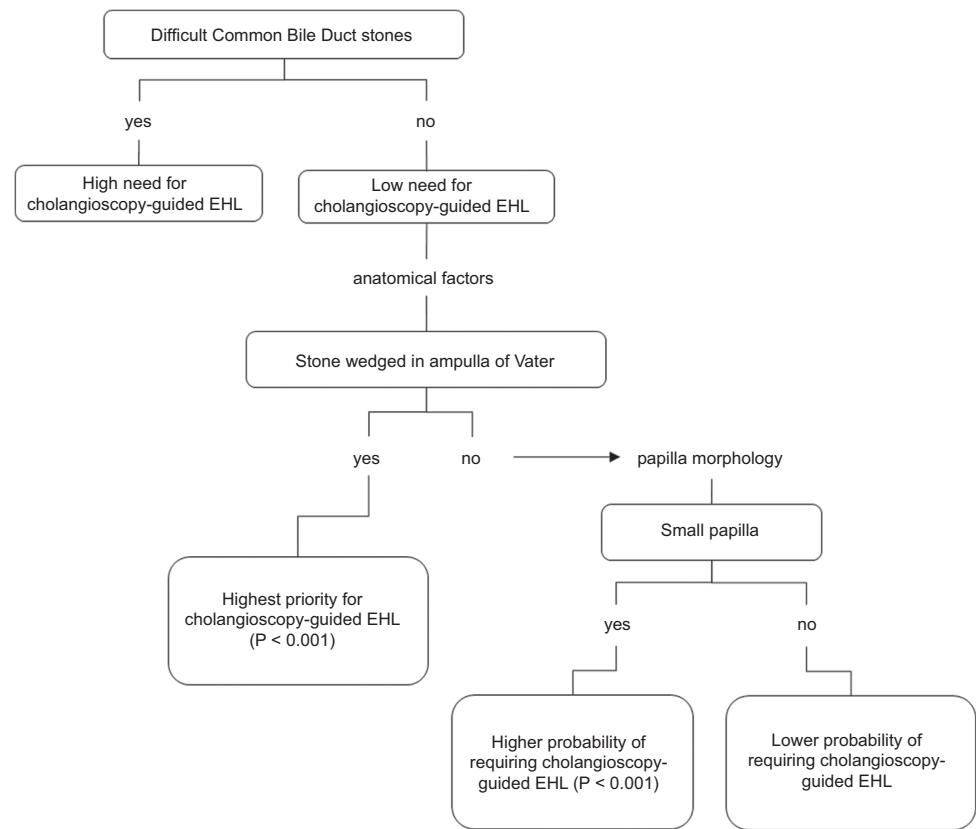


Figure 1 Classification tree prioritizing parameters for assessing cholangioscopy-guided EHL as first choice treatment
EHL, electrohydraulic lithotripsy

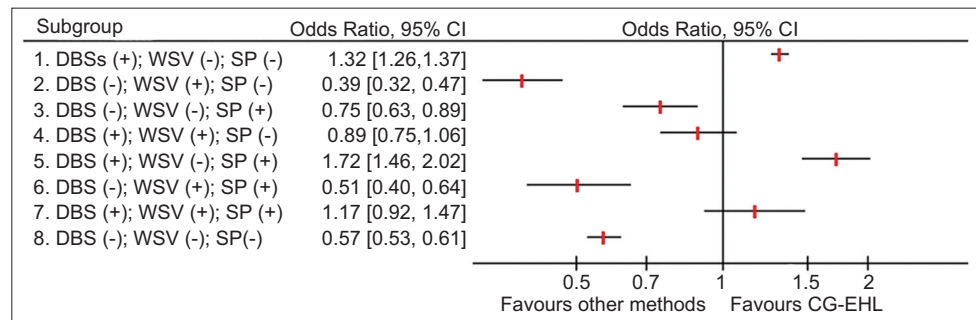


Figure 2 Forest plot depicting odds ratios for cholangioscopy-guided electrohydraulic lithotripsy (CG-EHL) for every possible combination of the 3 prognosticators, namely difficult bile duct stones (DBS), wedged stone in Vater (WSV) and small papilla (SP)
CI, confidence interval

Similarly, the American Society for Gastrointestinal Endoscopy (ASGE) guidelines support ERCP as the primary therapeutic approach for biliary lithiasis. For large choledocholithiasis, ASGE recommends large-balloon dilation after sphincterotomy, based on moderate-quality evidence [13]. For large or difficult stones, intraductal or conventional therapy with papillary dilation is advised, though this is based on low-quality evidence and may be affected by local expertise, cost, and patient or physician preferences. ASGE also notes the need for standardized terminology to classify bile duct stones.

Numerous studies have evaluated the efficacy of cholangioscopy-assisted lithotripsy in the management of DBS.

The Japanese Society of Gastroenterology guidelines for biliary lithiasis emphasize that intraductal treatment using a single-operator cholangioscope (SOC) and EHL is recommended for cases involving endoscopically difficult stones, and for giant stones exceeding 3 cm in diameter [14]. A meta-analysis conducted by Korrapati *et al* that assessed the efficacy of peroral cholangioscopy estimated an overall stone clearance rate of 88% and a stone recurrence rate of 13% [16]. A randomized controlled trial (RCT) by Franzini *et al* found no significant difference in stone clearance between cholangioscopy-guided EHL and conventional therapy ($P>0.05$) [17], although it proposed an evidence-based algorithm for managing large

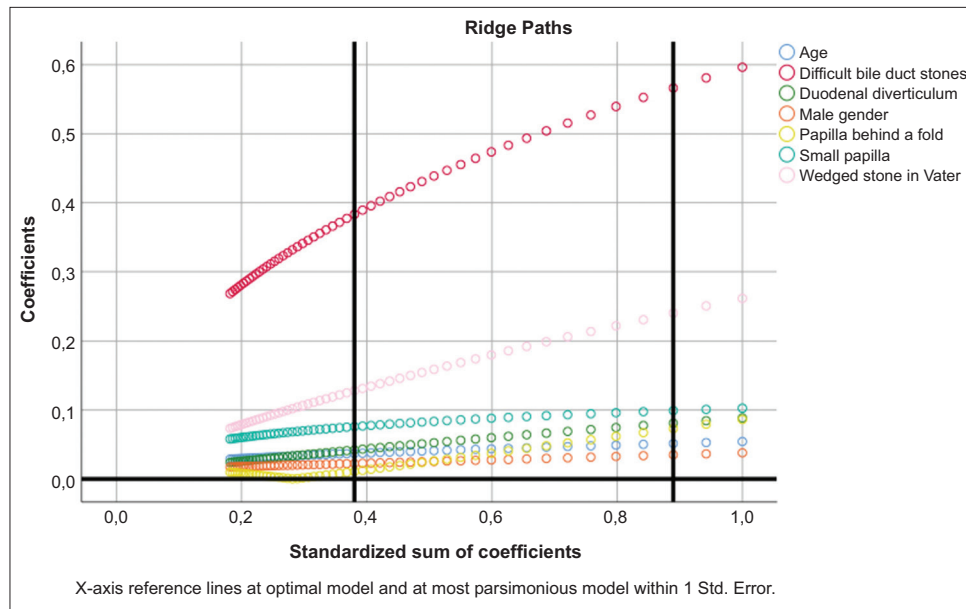


Figure 3. Binary regression model based on optimal scaling after discretization into the maximum of categories allowed (binary=2; scale=7), ridge regression and 10× cross-validation, assessing the parameters that are independently correlated with the use of cholangioscopy-guided electrohydraulic lithotripsy; ridge paths (full model is depicted in Table 2)

or disproportionate stones. Unlike that study, our findings emphasize specific techniques. Notably, cholangioscopy-guided laser lithotripsy has shown superior efficacy compared to conventional methods in 2 separate RCTs [18,19].

Recent multicenter studies by Fugazza *et al* demonstrated the safety and efficacy of lithotripsy using SOC in real-world DBS cases [20]. Additionally, a retrospective study conducted by Tejido *et al*, which evaluated all SOC procedures performed at their center for various indications, confirmed the safety and efficacy of the technique [21]. A review by Galetti *et al* and a subsequent meta-analysis by Mauro *et al* demonstrated that cholangioscopy-guided EHL achieves equivalent rates of success and adverse events compared to standard ERCP, while utilizing comparable fluoroscopy exposure. Furthermore, cholangioscopy-guided EHL is highly effective after standard technique failure, reducing the need for surgery [22,23].

The current study aimed to establish a novel, structured algorithm that recommends cholangioscopy-guided EHL as a first-line therapy for DBS. This model uses objective prognostic factors to replace traditional subjective clinical judgment. Consistent with the necessity of preprocedural planning highlighted by El Menabawey *et al*, our algorithm provides quantifiable data to assess the likelihood of success with conventional ERCP [24]. Early utilization of cholangioscopy-guided EHL is supported by the presence of imaging features that predict high failure rates with standard techniques, particularly in complex lithiasis. Adopting this structured approach is expected to optimize care, enhance clinical efficiency, and minimize reliance on repeat endoscopic procedures. In line with our results, El Menabawey *et al* have previously identified stone size, particularly large stones (greater than 15 mm), as a strong predictor of technical

difficulty, highlighting the value of cholangioscopy-guide EHL in the management of high-risk lithiasis.

The economic impact of difficult bile duct lithiasis is notable, given that patients in published cohorts commonly require 2 or more ERCP procedures before a definitive specialized technique is applied. Consequently, the timely and precise triage of DBS offers a pathway to significant cost savings [23,25,26]. Although international guidelines currently recommend a stepwise approach, this established algorithm could be significantly improved through the incorporation of a predictive model. Such optimization, based on early identification of high-risk cases, would reduce reliance on sequential, potentially unsuccessful procedures, thereby reducing healthcare costs and patient risks associated with cumulative ERCP exposure [26].

Comparing our findings with international data highlights notable distinctions between patients treated with EHL and those who were not, especially regarding the morphology of bile duct stones and the history of prior endoscopic attempts (Table 1). The classification tree serves as a practical, statistically supported tool for prioritizing cholangioscopy-guided EHL, confirming the predictive value of DBS, the absence of wedged stones in Vater, and small papillae.

The binary regression model identifies key factors independently associated with the need for EHL, including DBS presence, absence of wedged stones, and small papillae (Table 2). In contrast, factors such as duodenal diverticula, age, male sex and papilla location showed no significant correlations, and are thus unlikely to be critical in determining treatment decisions for biliary lithiasis. ORs related to these predictors underscore the impact of specific anatomical and procedural challenges on the decision to perform cholangioscopy-guided EHL (Supplementary Table 1, Fig. 2, 4).

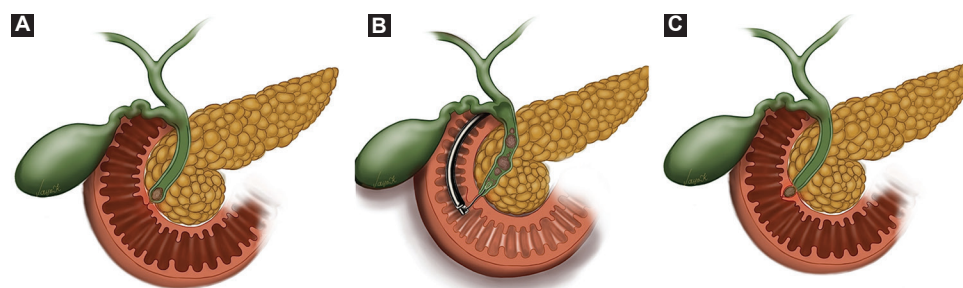


Figure 4 Graphical representation of key factors in predicting the need for cholangioscopy-guided electrohydraulic lithotripsy (EHL). The presence of a small papilla (A) or difficult bile duct stones (B) is associated with an increased likelihood of cholangioscopy-guided EHL use, whereas a wedged stone in the ampulla of Vater demonstrates an inverse relationship, with its presence decreasing the likelihood of EHL use (C)

The hierarchical importance of the identified clinical and anatomical predictors was further emphasized by the ridge regression analysis. The consistent performance and stability of these key factor coefficients across the model strongly reinforce their clinical relevance and robustness. In addition, the use of ridge regression strengthens the stability and external validity of the model, supporting its relevance in clinical practice (Fig. 3).

A key strength of this study is its methodological approach, which combines a retrospective design with prospectively collected data, standardized patient assessment and clearly defined eligibility criteria. The study was conducted in a tertiary referral center, where more complex cases are routinely managed, explaining the higher proportion of patients with DBS in this cohort.

This analysis also has limitations. It reflects the experience of a single center, which may limit the broader applicability of the findings. However, comparable results may be achievable in other high-volume units with similar expertise and clinical infrastructure.

In conclusion, cholangioscopy-guided EHL constitutes a highly effective treatment option for DBS, providing a less invasive alternative to conventional surgical management. Healthcare professionals should prioritize cholangioscopy-guided EHL over conventional techniques in the management of DBS, particularly when a small papilla is present or when there is no wedged stone in the ampulla of Vater. By utilizing these critical predictors, practitioners can enhance patient selection and optimize outcomes for individuals requiring intraductal interventions. This ensures that the most influential factors are properly emphasized during the clinical decision-making process.

Acknowledgments

In compliance with the International Committee of Medical Journal Editors (ICMJE) recommendations, the authors acknowledge the utilization of AI services in this work (Google Gemini Pro), exclusively for minor English corrections. All sentences revised by Google Gemini Pro were reviewed and verified by all authors. No content was generated by Google Gemini Pro or any other AI service.

Summary Box

What is already known:

- Cholangioscopy enables direct visualization of the biliopancreatic tree and overcomes the limitations of endoscopic retrograde cholangiopancreatography, which relies solely on fluoroscopy
- In therapeutic practice, cholangioscopy-guided electrohydraulic lithotripsy (EHL) is indicated for large, multiple, intrahepatic or impacted bile duct stones, as well as for stones associated with strictures or anatomical anomalies
- Cholangioscopy-guided EHL is usually used as a late-line technique in difficult bile duct stones (DBS), after endoscopic papillary large-balloon dilation failure or in complex bile stones (high multiplicity, >3 cm in diameter)

What the new findings are:

- DBS, wedged stones in the ampulla of Vater and small papilla constitute significant key factors in predicting the need for cholangioscopy-guided EHL
- Healthcare professionals should prioritize cholangioscopy-guided EHL over conventional techniques in cases involving DBS, particularly when a small papilla is present or when there is no wedged stone in the ampulla of Vater
- By identifying key predictors, this study offers foundational insights that may guide future clinical research, ultimately enhancing the treatment guidelines of biliary lithiasis, improving care quality and reducing the financial burden

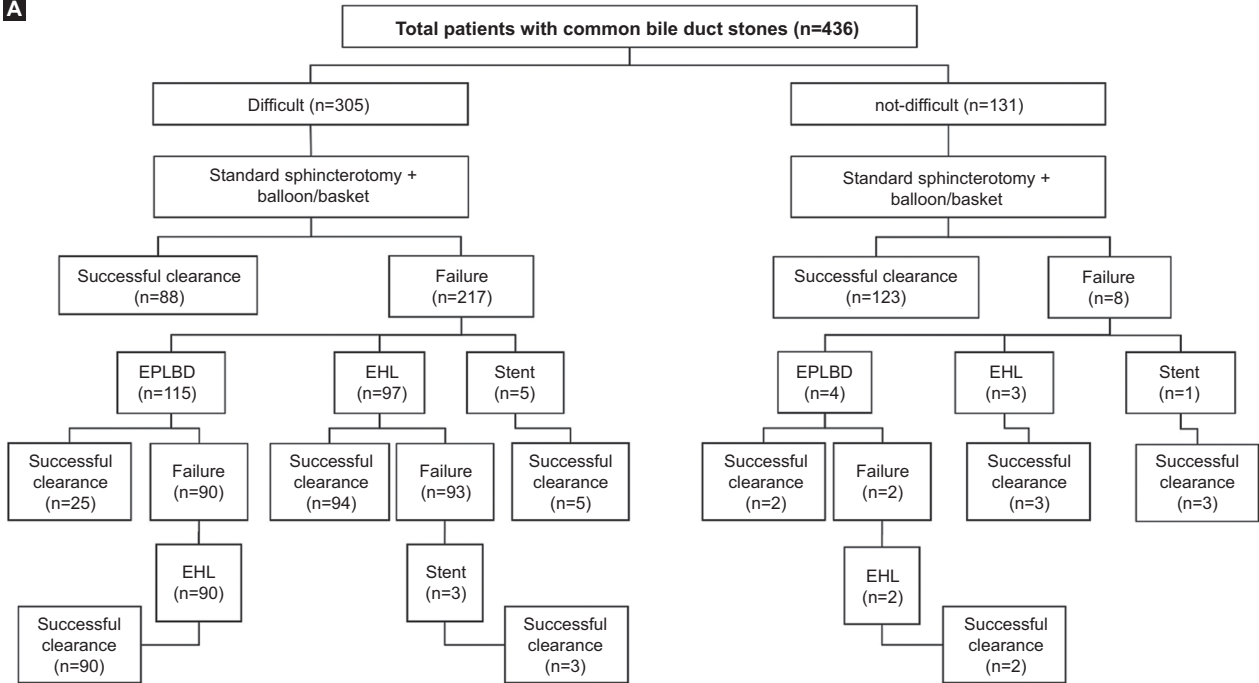
References

1. McCune WS, Shorb PE, Moscovitz H. Endoscopic cannulation of the ampulla of vater: a preliminary report. *Ann Surg* 1968;**167**:752-756.
2. Urakami Y, Seifert E, Butke H. Peroral direct cholangioscopy

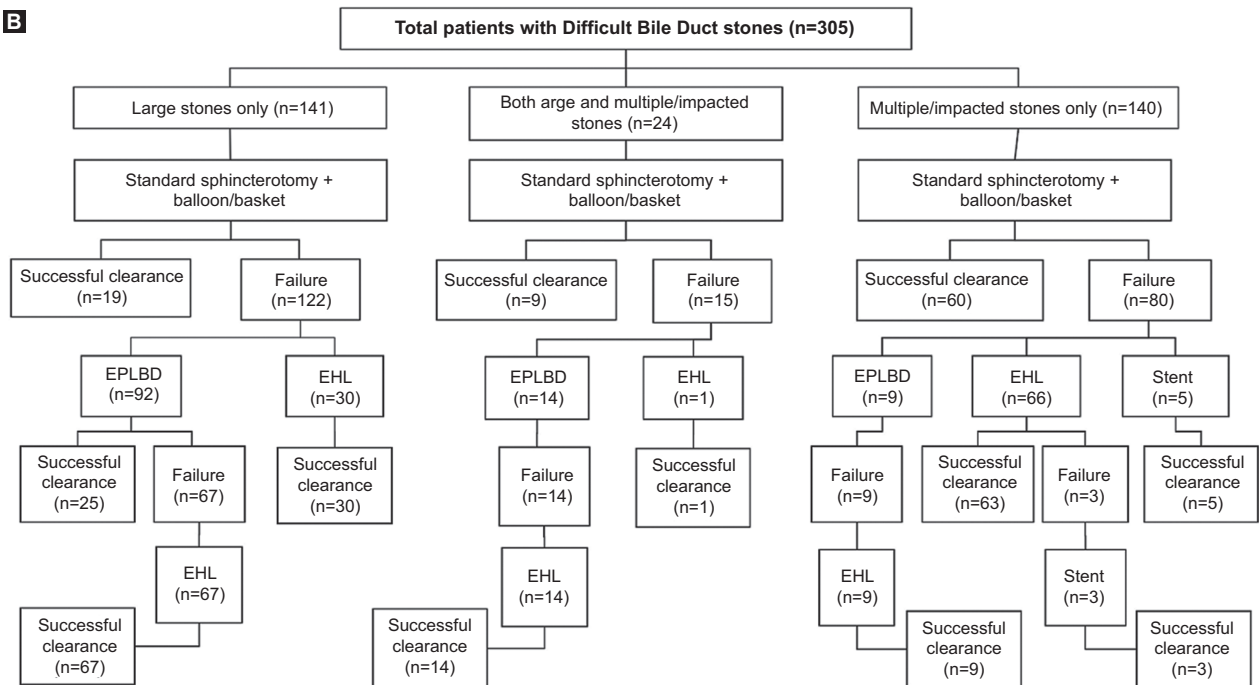
- (PDCS) using routine straight-view endoscope: first report. *Endoscopy* 1977;**9**:27-30.
3. Choi JH, Lee SK. Percutaneous transhepatic cholangioscopy: does its role still exist? *Clin Endosc* 2013;**46**:529-536.
 4. Chen YK, Pleskow DK. SpyGlass single-operator peroral cholangiopancreatography system for the diagnosis and therapy of bile-duct disorders: a clinical feasibility study (with video). *Gastrointest Endosc* 2007;**65**:832-841.
 5. Ishida Y, Itoi T, Okabe Y. Types of peroral cholangioscopy: how to choose the most suitable type of cholangioscopy. *Curr Treat Options Gastroenterol* 2016;**14**:210-219.
 6. Subhash A, Buxbaum JL, Tabibian JH. Peroral cholangioscopy: update on the state-of-the-art. *World J Gastrointest Endosc* 2022;**14**:63-76.
 7. Ayoub F, Yang D, Draganov PV. Cholangioscopy in the digital era. *Transl Gastroenterol Hepatol* 2018;**3**:82.
 8. McHenry L, Lehman G. Difficult bile duct stones. *Curr Treat Options Gastroenterol* 2006;**9**:123-132.
 9. Leung JW, Chung SS. Electrohydraulic lithotripsy with peroral choledochoscopy. *BMJ* 1989;**299**:595-598.
 10. Binmoeller KE, Brückner M, Thonke F, Soehendra N. Treatment of difficult bile duct stones using mechanical, electrohydraulic and extracorporeal shock wave lithotripsy. *Endoscopy* 1993;**25**:201-206.
 11. Kamiyama R, Ogura T, Okuda A, et al. Electrohydraulic lithotripsy for difficult bile duct stones under endoscopic retrograde cholangiopancreatography and peroral transluminal cholangioscopy guidance. *Gut Liver* 2018;**12**:457-462.
 12. Manes G, Paspatis G, Aabakken L, et al. Endoscopic management of common bile duct stones: European Society of Gastrointestinal Endoscopy (ESGE) guideline. *Endoscopy* 2019;**51**:472-491.
 13. Buxbaum JL, Abbas Fehmi SM, Sultan S, et al; ASGE Standards of Practice Committee. ASGE guideline on the role of endoscopy in the evaluation and management of choledocholithiasis. *Gastrointest Endosc* 2019;**89**:1075-1105.
 14. Fujita N, Yasuda I, Endo I, et al. Evidence-based clinical practice guidelines for cholelithiasis 2021. *J Gastroenterol* 2023;**58**:801-833.
 15. Cotton PB, Eisen GM, Aabakken L, et al. A lexicon for endoscopic adverse events: report of an ASGE workshop. *Gastrointest Endosc* 2010;**71**:446-454.
 16. Korrapati P, Ciolino J, Wani S, et al. The efficacy of peroral cholangioscopy for difficult bile duct stones and indeterminate strictures: a systematic review and meta-analysis. *Endosc Int Open* 2016;**4**:E263-E275.
 17. Franzini T, Moura RN, Bonifácio P, et al. Complex biliary stones management: cholangioscopy versus papillary large balloon dilation - a randomized controlled trial. *Endosc Int Open* 2018;**6**:E131-E138.
 18. Buxbaum J, Sahakian A, Ko C, et al. Randomized trial of cholangioscopy-guided laser lithotripsy versus conventional therapy for large bile duct stones (with videos). *Gastrointest Endosc* 2018;**87**:1050-1060.
 19. Angsuwatcharakon P, Kulpacharapong S, Ridditid W, et al. Digital cholangioscopy-guided laser versus mechanical lithotripsy for large bile duct stone removal after failed papillary large-balloon dilation: a randomized study. *Endoscopy* 2019;**51**:1066-1073.
 20. Fugazza A, Gabbiadini R, Tringali A, et al. Digital single-operator cholangioscopy in diagnostic and therapeutic bilio-pancreatic diseases: A prospective, multicenter study. *Dig Liver Dis* 2022;**54**:1243-1249.
 21. Tejido C, Puga M, Regueiro C, Francisco M, Rivas L, Sánchez E. Evaluation of the effectiveness and safety of single-operator cholangiopancreatography with the SpyGlass™ system. *Gastroenterol Hepatol* 2024;**47**:170-178.
 22. Galetti F, Moura DTH, Ribeiro IB, et al. Cholangioscopy-guided lithotripsy vs. conventional therapy for complex bile duct stones: a systematic review and meta-analysis. *Arq Bras Cir Dig* 2020;**33**:e1491.
 23. Mauro A, Mazza S, Scalvini D, et al. The role of cholangioscopy in biliary diseases. *Diagnostics (Basel)* 2023;**13**:2933.
 24. El Menabawey T, Mulay A, Graham D, Phillpotts S, Sethi A, Webster GJ. Predictors of success of conventional ERCP for bile duct stones and need for single-operator cholangioscopy. *Endosc Int Open* 2023;**11**:E943-E951.
 25. Sandha J, van Zanten SV, Sandha G. The safety and efficacy of single-operator cholangioscopy in the treatment of difficult common bile duct stones after failed conventional ERCP. *J Can Assoc Gastroenterol* 2018;**1**:181-190.
 26. Martin H, Sturgess R, Mason N, et al. ERCP for bile duct stones across a national service, demonstrating a high requirement for repeat procedures. *Endosc Int Open* 2023;**11**:E142-E148.

Supplementary material

A



B



Supplementary Figure 1 (A) Flow chart describing treatment approach of patients enrolled in the study; (B) Flow chart describing treatment approach of patients with difficult bile duct stones enrolled in the study

EPLBD, endoscopic papillary large-balloon dilation; EHL, electrohydraulic lithotripsy

Supplementary Table 1 Odds ratios for using cholangioscopy-guided EHL calculated from data presented in Table 2 and quantify the algorithm presented in Figure 2

Variable	OR for using cholangioscopy-guided EHL when present	OR for using cholangioscopy-guided EHL when absent
Difficult bile duct stones	1.57	0.64
Wedged stone in Vater	0.70	1.43
Small papilla	1.27	0.79

EHL, electrohydraulic lithotripsy