

Single incision laparoscopic surgery for ileal J-pouch–anal anastomosis: a 15-year review of the literature

Evangelia Balla^a, Dimitrios Dimitroulis^{b,c}, Nikolaos Garmpis^{b,c}, Ilektra Kyrochristou^d, Nikolaos Nikiteas^{b,c}, Dimitrios Patsouras^{b,c}

General Hospital of Filiates, Thesprotia; Laiko General Hospital, Medical School, National and Kapodistrian University of Athens, Greece; Hellenic Minimally Invasive Surgery Study Group, National and Kapodistrian University of Athens, Medical School; General Hospital of Nikaia and Piraeus, Athens, Greece

Abstract

Single-incision laparoscopic surgery (SILS) has emerged as a refinement of minimally invasive techniques, offering potential cosmetic and postoperative recovery benefits. This review aimed to evaluate the current evidence regarding the safety, feasibility, and outcomes of SILS for ileal J-pouch–anal anastomosis (IPAA). A structured literature search was performed in PubMed for studies published between January 2010 and January 2025, focusing on adult and pediatric patients undergoing restorative proctocolectomy with IPAA performed through a single incision. Twenty-two studies were identified, encompassing 182 procedures. The mean operative time ranged from 144–284 min. Reported conversion to multiport laparoscopy or open surgery occurred in 3.9% of cases, while the mean estimated blood loss varied from 27–136 mL. The median length of hospital stay was 4 days in most studies. Major postoperative complications (Clavien-Dindo grade \geq III) occurred in approximately 9% of patients, most commonly small-bowel obstruction or anastomotic leak. Cosmetic satisfaction and postoperative pain scores were generally favorable, although long-term functional outcomes were rarely reported. SILS-IPAA appears feasible and safe in selected patients, particularly when performed by experienced surgeons familiar with conventional laparoscopic restorative proctocolectomy. The current literature is heterogeneous and limited by small sample sizes and overlapping institutional data. Further comparative studies, especially in the context of robotic platforms, are needed to define the role of SILS in modern pouch surgery.

Keywords Single incision laparoscopic surgery, ileal J-pouch–anal anastomosis, ulcerative colitis, minimally invasive surgery, colorectal surgery

Ann Gastroenterol 2026; 39 (1): 1-10

^aDepartment of Surgery, General Hospital of Filiates, Thesprotia, Greece (Evangelia Balla); ^bSecond Department of Propaedeutic Surgery, Laiko General Hospital, Medical School, National and Kapodistrian University of Athens, Athens, Greece (Dimitrios Dimitroulis, Nikolaos Garmpis, Nikolaos Nikiteas, Dimitrios Patsouras); ^cHellenic Minimally Invasive Surgery Study Group (MIRS), National and Kapodistrian University of Athens, Medical School, Athens, Greece (Dimitrios Dimitroulis, Nikolaos Garmpis, Nikolaos Nikiteas, Dimitrios Patsouras); ^dDepartment of Emergency Medicine, General Hospital of Nikaia and Piraeus, Athens (Ilektra Kyrochristou), Greece

Conflict of Interest: None

Correspondence to: Evangelia Balla, Department of Surgery, General Hospital of Filiates, Thesprotia, Greece, e-mail: evaballa@hotmail.com

Received 6 August 2025; accepted 29 October 2025;
published online 12 December 2025

DOI: <https://doi.org/10.20524/aog.2026.1027>

This is an open-access journal, and articles are distributed under the terms of the Creative Commons Attribution-NonCommercial-ShareAlike 4.0 License, which allows others to remix, tweak, and build upon the work non-commercially, as long as appropriate credit is given and the new creations are licensed under the identical terms

© 2026 Hellenic Society of Gastroenterology

Introduction

Restorative proctocolectomy with ileal J-pouch–anal anastomosis (IPAA) remains the procedure of choice when restoration of intestinal continuity is attempted, offering quality-of-life outcomes comparable to those achieved with a permanent ileostomy or an ileorectal anastomosis [1–4]. The procedure provides excellent long-term results in patients with medically refractory ulcerative colitis (UC) and familial adenomatous polyposis (FAP) [5–7].

Conventional laparoscopic IPAA has been widely adopted since its introduction, as it reduces postoperative pain, shortens the length of hospital stay, and improves cosmesis compared with open surgery [8–11]. Single-incision laparoscopic surgery (SILS) represents the next step in minimally invasive evolution. By performing the entire operation through a single umbilical incision, SILS aims to further minimize parietal trauma and enhance cosmetic outcomes, while maintaining the benefits of standard laparoscopy [12,13].

SILS has gained popularity in colorectal and general surgery, including colectomy, appendectomy and

www.annalsgastro.gr

cholecystectomy [14–16]. However, the technical complexity of restorative proctocolectomy, requiring total mesorectal excision and deep pelvic dissection, limits its widespread use for IPAA [17]. Nevertheless, an increasing number of case reports and small series have described SILS IPAA since the first published experiences in 2010 [18]. The present study aimed to review the available literature on SILS IPAA, focusing on feasibility, safety, perioperative outcomes and early functional results, and to contextualize this approach within contemporary minimally invasive techniques.

Materials and methods

Study design

This work was conducted as a narrative systematic review of the literature, following the key principles of the Preferred Reporting Items for Systematic Reviews and Meta-Analyses (PRISMA) framework (Supplementary Table 1) [19]. The review aimed to summarize current evidence on SILS IPAA, focusing on feasibility, safety, perioperative outcomes and early functional results.

Search strategy

A systematic search was performed in the PubMed database for studies published between January 2010 and January 2025. The year 2010 was chosen as the lower limit because the earliest reports of SILS IPAA appeared at that time [20]. PubMed was selected for its comprehensive medical indexing and coverage of peer-reviewed surgical literature; pilot searches in other databases (Scopus, Embase) revealed no additional eligible studies [21].

The following keywords and Boolean operators were used: (“single incision laparoscopic” OR “single port laparoscopic” OR “SILS”) AND (“ileal pouch anal anastomosis” OR “J-pouch” OR “restorative proctocolectomy”). Reference lists of relevant articles and review papers were also screened manually to identify additional eligible studies.

Eligibility criteria

Studies were included if they: (a) reported patients undergoing restorative proctocolectomy with IPAA performed entirely through a single incision; (b) were published in English; and (c) reported at least 1 perioperative or postoperative outcome. Case reports, case series, retrospective cohort studies and prospective non-comparative studies were eligible. Reviews, editorials, and animal or cadaveric studies were excluded. Both adult and pediatric populations were eligible, and this inclusiveness is acknowledged in the Results and Limitations sections.

Study selection

Two reviewers independently screened titles and abstracts, followed by full-text assessment of potentially eligible articles. Disagreements were resolved by consensus. The selection process is summarized in Fig. 1 (PRISMA flow chart).

Data extraction

For each included study, data were extracted on patient demographics, underlying disease (UC, FAP, or other), operative technique, operative time, conversion rate, intraoperative blood loss, perioperative complications, and length of hospital stay. When reported, functional and quality-of-life outcomes were also recorded.

Primary and secondary outcomes

The primary outcomes were feasibility (completion rate, conversion), safety (complications), and operative characteristics (time, blood loss).

The secondary outcomes included early functional results (bowel frequency, continence, pouchitis incidence), and patient-reported measures such as pain or cosmetic satisfaction.

Data synthesis

In view of the substantial heterogeneity in study design, sample size and reporting, no quantitative meta-analysis was attempted. Results are summarized descriptively and, where appropriate, presented as ranges or medians.

Results

Study selection

The search identified 83 potentially relevant records. After title and abstract screening, 37 full-text articles were assessed, of which 22 met the eligibility criteria for inclusion (Fig. 1). These comprised 3 case reports, 13 retrospective case series, and 6 case-controlled studies, encompassing a total of 182 procedures [22–43].

Potential overlap of cohorts from the same institutions was noted and is acknowledged in the Limitations section. No randomised or comparative trials were identified.

Patient demographics

Across studies, the mean age ranged from 22–42 years [22–43]. Both adult and pediatric populations were represented; 5 studies specifically included patients under 18 years of age

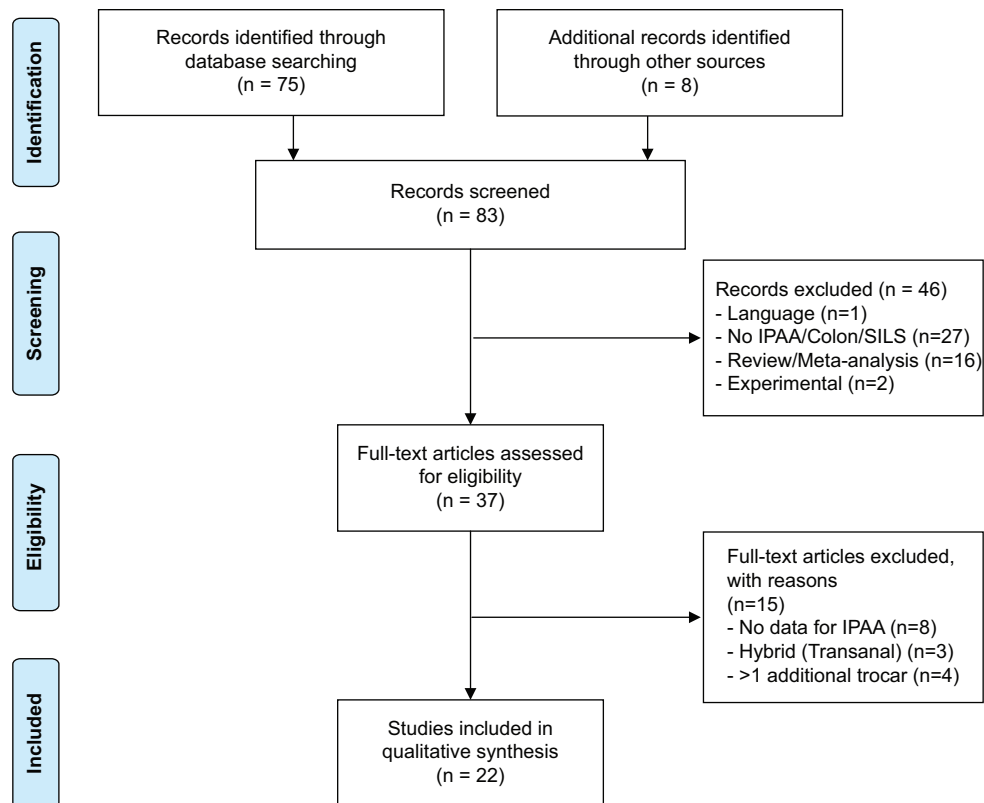


Figure 1 PRISMA flowchart

From: Moher D, Liberati A, Tetzlaff J, Altman DG. The PRISMA Group (2009). Preferred Reporting Items for Systematic Reviews and Meta-Analyses: The PRISMA Statement. *PLoS Med* 6(7): e1000097. doi:10.1371/journal.pmed1000097. For more information, visit www.prisma-statement.org.

[22,35,36,38,39]. Overall, approximately 12% of reported patients were pediatric. The inclusion of mixed age groups was prespecified and is noted in the materials and methods.

The sex distribution was balanced (49% male overall). The mean body mass index, reported in 9 studies, ranged between 21.8 and 25.6 kg/m² [22,23,28-31,34,41,43].

Underlying disease

UC accounted for 89% of indications, while FAP represented the remainder [22-43]. One study also reported a single case of indeterminate colitis [43]. All preoperative data are summarized in Table 1.

Operative characteristics

All operations were completed through a single umbilical incision, typically using a multiport access device (e.g., SILS Port or TriPort). The mean operative time ranged from 144-284 min, based on data from 15 studies that provided explicit times [22-26,28-30,34-36,38,39,41,43].

Conversion to multiport laparoscopy or open surgery occurred in 3.9% of cases overall, most commonly because of

dense pelvic adhesions or inadequate visualization [24,28,30].

Estimated intraoperative blood loss was low across all studies, varying from 27-136 mL [22-25,34,38,41,43]. All intraoperative variables are presented in Tables 2A,B.

Postoperative outcomes

Postoperative recovery was generally favorable. The median length of hospital stay was 4 days, reported as the most common median in 13 studies [22,23,25-30,34,36,38,39,41,43].

Overall morbidity ranged from 0-31%, while major complications (Clavien-Dindo ≥III) occurred in approximately 9% of patients. The most frequent complications were small-bowel obstruction (n=6), anastomotic leak (n=5), pelvic abscess (n=3), and wound infection (n=2) [23,29,34-36,38,39,41,43]. There were no reported deaths. The postoperative outcomes are summarized in Table 3.

Functional and cosmetic outcomes

Functional results were rarely reported. When available, the median bowel frequency ranged from 4-6 movements per day at 6-12 months postoperatively [29,35,38,43]. Continence outcomes were described as satisfactory in all studies.

Table 1 Preoperative data

Author, year [ref.]	Study type	Total number of SILS patients	SILS-IPAA	Disease for SILS-IPAA	Sex (male: female)	Age	BMI	ASA score/cases	Procedure
Geisler <i>et al</i> 2010 [22]	CR	1	1	FAP: 1	1:0	13	24	ns	TPC: 1
Geisler <i>et al</i> 2011 [23]	CS	5	5	UC: 4 FAP: 1	3:2	43 [^]	20.66 [^]	2 [^]	TPC: 5
Geisler and Garrett 2011 [24]	CS	102	20	UC, FAP	ns	ns	ns	ns	TPC: 13 CP: 7
Podolsky and Curcillo 2010 [25]	CS	113	1	UC: 1	ns	ns	ns	ns	TPC: 1
Chambers <i>et al</i> 2011 [26]	CS	7	1	UC: 1	1:0	26	ns	II	TPC: 1
Goede <i>et al</i> 2011 [27]	CS	7	7	UC: 7	ns	ns	ns	ns	TPC: 5 CP: 2
Gash <i>et al</i> 2011 [28]	CS	20	2	UC: 2	1:1	26+28	23+21	II+III	TPC: 2
Gash <i>et al</i> 2011 [29]	CS	10	10	UC: 10	4:6	31 [^]	22 [^]	ns	TPC: 7 CP: 3
Vestweber <i>et al</i> 2013 [30]	CS	224	9	UC: 7 FAP: 2	6:3	47.6*	25.8*	I: 2 II: 7	TPC: 9
Leblanc <i>et al</i> 2011 [31]	CS	4	1	UC: 1	0:1	31	26	ns	TPC: 1
Stewart and Messaris 2012 [32]	CS	41	1	UC: 1	ns	ns	ns	ns	CP: 1
Bulian <i>et al</i> 2012 [33]	CR	1	1	UC: 1	ns	54	ns	ns	CP: 1
Costedio <i>et al</i> 2012 [34]	CC	24	24	UC: 23 FAP: 1	9:15	43.2*	24.8*	II [^]	TPC: 13 CP: 11
Potter <i>et al</i> 2012 [35]	CS	11	8	UC, FAP, IC	ns	ns	ns	ns	TPC: 6 CP: 2
Polites <i>et al</i> 2015 [36]	CC	19	19	UC: 15 FAP: 4	9:10	14.1*	ns	ns	TPC: 12 CP: 7
Olson <i>et al</i> 2014 [37]	CC	20	4	UC: 4	ns	ns	ns	ns	TPC: 2 CP: 2
Perger <i>et al</i> 2014 [38]	CC	11	10	UC: 7 FAP: 3	ns	ns	ns	ns	TPC: 4 CP: 6
Schlager <i>et al</i> 2015 [39]	CS	8	8	UC: 8	3:5	14	ns	ns	CP: 8
Khayat <i>et al</i> 2015 [40]	CC	84	6	ns	ns	ns	ns	ns	TPC: 3 CP: 3
Homma <i>et al</i> 2016 [41]	CS	10	7	UC: 7	2:5	30.6*	19.7*	2.3*	TPC: 6 CP: 1
Benlice and Gorgun 2016 [42]	CR	1	1	UC: 1	0:1	39	ns	ns	CP: 1
Li <i>et al</i> 2019 [43]	CC	36	36	IC: 1 UC: 35	11:25	41*	24,56*	I, II: 21 III, IV: 15	CP: 36

Cosmetic satisfaction was consistently high, with most patients preferring the single-incision approach. Pain scores were also reported as lower than those in historical multiport cohorts, though no comparative data were available [43].

Discussion

This review summarizes the cumulative experience from SILS IPAA over the past 15 years. The collective evidence

demonstrates that SILS IPAA is technically feasible and can be performed safely in carefully selected patients, provided that the operating surgeon has significant experience in both conventional laparoscopic and restorative proctocolectomy techniques.

The principal advantages proposed for SILS are better cosmetic results, potentially lower levels of postoperative pain, and faster recovery, all derived from minimizing parietal trauma [44-46]. These benefits have been well documented for other colorectal procedures, including colectomy and

Table 2A Intraoperative data

Author, year [ref.]	Site of SILS-port	Type of access/SILS-port	Use of +1 trocar	Site+1 trocar	Standard/ curved instruments	Stapled/ hand-sewn IPAA
Geisler <i>et al</i> 2010 [22]	Ileostomy site	Covidien SILS™	0/1	-	Curved (+flexible tip laparoscope)	Stapled
Geisler <i>et al</i> 2011 [23]	Ileostomy site	Covidien SILS™	0/5	-	Standard (+flexible tip laparoscope)	Stapled
Geisler and Garrett 2011 [24]	Ileostomy site	Covidien SILS™	11/20	Drain site	Standard	Stapled
Podolsky and Curcillo 2010 [25]	Umbilicus	One skin incision-multiple trocars through fascia (3-4)	0/1	-	Standard	ns
Chambers <i>et al</i> 2011 [26]	Ileostomy site	Olympus TriPort™	0/1	-	Standard (+flexible tip laparoscope)	Stapled
Goede <i>et al</i> 2011 [27]	Ileostomy site	Olympus TriPort™	0/7	-	ns	Stapled
Gash <i>et al</i> 2011 [28]	Ileostomy site	Olympus TriPort™ Covidien SILS™	0/2	-	Standard	Stapled
Gash <i>et al</i> 2011 [29]	Ileostomy site	Olympus TriPort™	0/10	-	Standard	Stapled: 8 Hand-sewn: 2
Vestweber <i>et al</i> 2013 [30]	Ileostomy site	Covidien SILS™	0/9	-	Standard (mainly)	Stapled
Leblanc <i>et al</i> 2011 [31]	Ileostomy site	Covidien SILS™	0/1	-	Standard	Stapled
Stewart and Messaris 2012 [32]	Ileostomy site	Ethicon SSL Access System	0/1	-	Standard	Stapled
Bulian <i>et al</i> 2012 [33]	Ileostomy site	Endocone® Karl Storz GmbH & Co	0/1	-	Standard+curved grasping forceps	Stapled
Costedio <i>et al</i> 2012 [34]	Ileostomy site	ns	24/24	Drain site/ (umbilicus-TPC, suprapubic-CP)	Standard (+flexible tip laparoscope)	Stapled
Potter <i>et al</i> 2012 [35]	Ileostomy site	GelPOINT™ Applied Medical, Olympus TriPort™ or Quadport	5/8	Umbilicus	Standard	Stapled: 6 Hand-sewn: 2
Polites <i>et al</i> 2015 [36]	Ileostomy site: 16 Umbilicus: 3	GelPOINT™ Applied Medical, Olympus TriPort™ or Quadport	10/19	Umbilicus	ns	Stapled: 8 Hand-sewn: 11
Olson <i>et al</i> 2014 [37]	Ileostomy site	Covidien SILS™, GelPOINT™ Applied Medical	0/4	-	Standard (+flexible tip laparoscope)	Stapled
Perger <i>et al</i> 2014 [38]	Ileostomy site	various	+1 at first	Umbilicus	Standard	Stapled (mainly) Hand-sewn: 0-3
Schlager <i>et al</i> 2015 [39]	Umbilicus	GelPOINT™ Applied Medical	8/8	Ileostomy site	ns	Stapled: 8
Khayat <i>et al</i> 2015 [40]	Ileostomy site	ns	0/6	-	Standard	ns

(Contd...)

Table 2A (Continued)

Author, year [ref.]	Site of SILS-port	Type of access/SILS-port	Use of +1 trocar	Site +1 trocar	Standard/curved instruments	Stapled/hand-sewn IPAA
Homma <i>et al</i> 2016 [41]	Umbilicus: 2 Ileostomy site: 5	Covidien SILS™	7/7	Ileostomy site (2) Umbilicus (5) -Drain site-	Standard (+flexible tip laparoscope) + Curved graspers	Stapled: 5 Hand-sewn: 2
Benlice and Gorgun 2016 [42]	Ileostomy site- left lower quadrant	ns	0/1	-	ns	Stapled
Li <i>et al</i> 2019 [43]	Ileostomy site	ns	+ -1	Drain site	ns	ns

Table 2B Intraoperative data

Author, year [ref.]	Length of pouch (cm)	Diverting loop Ileostomy (n/cases)	Operative time (min)	Blood loss (mL)	Conversion to OS or CLS/cases
Geisler <i>et al</i> 2010 [22]	18/EC	1/1	172	100	0
Geisler <i>et al</i> 2011 [23]	20/EC	5/5	153^	100^	0
Geisler and Garrett 2011 [24]	ns/EC	20/20	TPC: 175* CP: 144*	TPC: 109* CP: 136*	1/20 (OS) 4/20 (CLS)
Podolsky and Curcillo 2010 [25]	ns	ns	300	100	0/1
Chambers <i>et al</i> 2011 [26]	20/EC	1/1	195	ns	0/1
Goede <i>et al</i> 2011 [27]	20/EC	7/7	ns	ns	0/7
Gash <i>et al</i> 2011 [28]	20/EC	2/2	195+160	ns	1/2 (CLS)
Gash <i>et al</i> 2011 [29]	20/EC	10/10	185^	ns	0/10
Vestweber <i>et al</i> 2013 [30]	ns	9/9	324*	ns	1/9 (OS)
Leblanc <i>et al</i> 2011 [31]	ns	1/1	ns	ns	0/1
Stewart and Messaris 2012 [32]	EC	1/1	ns	ns	0/1
Bulian <i>et al</i> 2012 [33]	13/EC	1/1	ns	ns	0/1
Costedio <i>et al</i> 2012 [34]	ns	24/24	125.9*	95.8*	0/24
Potter <i>et al</i> 2012 [35]	12-15/EC	6/8	300* (1-stage) 304* (3-stage) 327* (2-stage)	ns	ns
Polites <i>et al</i> 2015 [36]	EC	16/19	332.6* 308.3* (1-stage) 353.4* (2-stage) 316.1* (3-stage)	ns	0/19
Olson <i>et al</i> 2014 [37]	ns	ns	ns	ns	0/4 (CLS) ns (OS)
Perger <i>et al</i> 2014 [38]	EC	10/10	455* (TPC) 198* (CP)	131* (TPC) 53* (CP)	0/10
Schlager <i>et al</i> 2015 [39]	10-12/EC	8/8	284*	ns	0/8
Khayat <i>et al</i> 2015 [40]	ns	6/6	ns	ns	ns
Homma <i>et al</i> 2016 [41]	10/EC	7/7	360* (TCP) 214 (CP)	26,7* (TCP) 0 (CP)	0/7
Benlice and Gorgun 2016 [42]	15-20/EC	1/1	ns	ns	0/1
Li <i>et al</i> 2019 [43]	ns	36/36	182^	100^	0/36

appendicectomy [47-49]. In the present review, most authors reported high cosmetic satisfaction and low pain scores;

however, the lack of comparative trials limits definitive conclusions.

Table 3 Postoperative data

Author, year [ref.]	Mortality (n/cases)	Postoperative morbidity	Hospital stay (days)	Fully continent	Pouch frequency (bowel movements)	Quality of life (QOL)
Geisler <i>et al</i> 2010 [22]	0/1	0	4	ns	ns	ns
Geisler <i>et al</i> 2011 [23]	0/5	2 partial small-bowel obstructions	4 [^]	ns	ns	ns
Geisler and Garrett 2011 [24]	0/20	ns	ns	ns	ns	ns
Podolsky and Curcillo 2010 [25]	0/1	ns	5	ns	ns	ns
Chambers <i>et al</i> 2011 [26]	0/1	0	90 h	ns	ns	ns
Goede <i>et al</i> 2011 [27]	0/7	0	4 [^]	ns	ns	ns
Gash <i>et al</i> 2011 [28]	0/2	0	90 + 56 h	ns	ns	ns
Gash <i>et al</i> 2011 [29]	0/10	1 surgical emphysema around the ileostomy site with temperature, 1 panic attack	3 [^]	9/10	4 [^] /24hr	1: minor daily soiling, nocturnal incontinence 1: dry ejaculate for 10 weeks
Vestweber <i>et al</i> 2013 [30]	0/9	ns	14.8*	ns	ns	ns
Leblanc <i>et al</i> 2011 [31]	0/1	0	ns	ns	ns	ns
Stewart and Messaris 2012 [32]	0/1	ns	ns	ns	ns	ns
Bulian <i>et al</i> 2012 [33]	0/1	0	ns	1/1	ns	No impotence
Costedio <i>et al</i> 2012 [34]	0/24	1 anastomotic leak, 2 PO urinary retention, 1 intraabdominal abscess, 3 PO ileus, 1 early pouchitis, 2 high ileostomy output, 1 wound infection	6.08*	ns	ns	ns
Potter <i>et al</i> 2012 [35]	ns	2 anastomotic leak, 1 small bowel obstruction	ns	ns	4,5*/24hr	2: rarely night-time stooling 1: single time stool incontinence 4: at least 1 episode of pouchitis
Polites <i>et al</i> 2015 [36]	ns	1 small bowel obstruction, 2 pelvic abscess/anastomotic leak/revision of IPAA, 1 wound infection/dehiscence, 3 ileostomy complications, 1 portal vein thrombosis	4* 9* (1-stage) 4* (2-stage) 3* (3-stage)	ns	ns	ns
Olson <i>et al</i> 2014 [37]	0/4	ns	ns	ns	ns	ns
Perger <i>et al</i> 2014 [38]	0/10	1 ileostomy malfunction, 1 circular staple line dehiscence, 1 rectovaginal fistula, 1 retained rectum with persistent bleeding and pain, 1 obstruction with perforation at DLI	3.5* (CP) 7* (TPC)	10/10	5 [^] /24hr	ns
Schlager <i>et al</i> 2015 [39]	ns	mucosal bridge at staple line requiring repeat surgery	5*	ns	ns	ns

(Contd...)

Table 3 (Continued)

Author, year [ref.]	Mortality (n/cases)	Postoperative morbidity	Hospital stay (days)	Fully continent	Pouch frequency (bowel movements)	Quality of life (QOL)
Khayat <i>et al</i> 2015 [40]	0/6	ns	ns	ns	ns	ns
Homma <i>et al</i> 2016 [41]	0/7	1 MRSA enteritis	25*(TPC)	ns	ns	no soiling or pad usage
Benlice and Gorgun 2016 [42]	0/1	0	ns	ns	ns	ns
Li <i>et al</i> 2019 [43]	0/36	1 ileus, 1 abdomino-pelvic abscess, 1 bowel obstruction, 1 hemorrhage, 2 stoma complications, 1 ureter injury	4^	83%	4^/day 2^/night 6^ in total	Cleveland Clinic Global QOL Scale, 15% pads usage day and night, 31.2% pouchitis

* = mean value, ^ = median value, ns = not specified for SILS IPAA cases included in each study

SILS, single incision laparoscopic surgery; IPAA, ileal-J-pouch anal anastomosis; BMI, body mass index; ASA, American Society of Anesthesiologists; CR, case report; CS, case series; CC, case control; FAP, familial adenomatous polyposis; UC, ulcerative colitis; IC, indeterminate colitis; TPC, total proctocolectomy; CP, completion proctectomy; OS, open surgery; CLS, conventional laparoscopic surgery; PO, postoperative; EC, extracorporeally; DLI, diverting loop ileostomy; MRSA, methicillin-resistant *Staphylococcus aureus*

Technical considerations

SILS IPAA presents several challenges. The limited triangulation, instrument crowding, and reduced range of motion increase the technical complexity of dissection in the narrow pelvis [26]. Innovative access platforms, articulated instruments, and flexible endoscopes have been employed to overcome these constraints [22,33,41]. Some groups have also described the use of a transanal or additional suprapubic port to facilitate difficult cases [24,34–36,38,39,41,43].

In experienced hands, SILS IPAA can replicate the oncological and functional quality of standard laparoscopy. Operative times, although initially longer, have approached those of conventional multiport procedures as experience has accumulated [34,36,43]. The conversion rate of 3.9% observed across the included series is comparable to that of multiport laparoscopy [29,32,37].

Comparison with robotics and other minimally invasive approaches

Since the introduction of robotic platforms, the role of SILS in colorectal surgery has been re-evaluated. Robotic systems provide enhanced dexterity, depth perception and ergonomics, which directly address the technical limitations of SILS [50,51]. The robotic single-port platform now allows intracorporeal triangulation through a single incision, potentially offering a more ergonomic and reproducible approach to IPAA [52–54].

While the cosmetic advantages of SILS are undeniable, its learning curve and ergonomic limitations may hinder its widespread adoption, especially in the era of advanced robotic technology. Therefore, future research should compare SILS directly with both conventional laparoscopy and robotic

approaches, focusing on patient-centered outcomes such as pain, recovery, and long-term pouch function.

Limitations

This review is subject to several limitations. First, the heterogeneity of available studies—ranging from isolated case reports to small retrospective series—precluded meta-analysis or statistical synthesis. Second, potential data duplication may exist, as some institutions published multiple reports that could include overlapping patients. To avoid inflating sample size, totals were not aggregated across possibly overlapping cohorts. Third, only PubMed was searched, which may have limited the retrieval of articles indexed exclusively elsewhere; however, preliminary searches confirmed that nearly all SILS IPAA reports were PubMed-listed. Fourth, both adult and pediatric patients were included, which introduces clinical variability. Finally, long-term functional and quality-of-life data were inconsistently reported, and outcomes beyond 1 year were rarely available. Despite these constraints, this review provides the most comprehensive overview to date of SILS IPAA and its evolution over the past decade and a half.

Concluding remarks

SILS IPAA is a technically demanding, yet feasible and safe alternative to conventional laparoscopy in experienced hands. Reported short-term outcomes, including conversion rate, morbidity, and recovery, are comparable to those of multiport approaches, with the additional advantages of improved cosmetic satisfaction and potentially reduced postoperative discomfort.

However, the available evidence is limited by small sample sizes, possible cohort overlaps, and heterogeneous reporting.

Current data do not demonstrate the superiority of SILS over established minimally invasive techniques. In the context of rapid technological progress, particularly the advent of robotic single-port systems, the clinical relevance of conventional SILS may become increasingly selective.

Future studies should prioritize comparative analyses between SILS, multiport laparoscopy, and robotic platforms, focusing on patient-centered outcomes, such as postoperative pain, recovery trajectory, functional results, and quality of life, rather than large, randomised trials designed solely to compare SILS with traditional laparoscopy.

References

1. Parks AG, Nicholls RJ. Proctocolectomy without ileostomy for ulcerative colitis. *Br Med J* 1978;2:85-88.
2. Pappou EP, Kiran RP. The Failed J Pouch. *Clin Colon Rectal Surg* 2016;29:123-129.
3. Campos FG. Surgical treatment of familial adenomatous polyposis: dilemmas and current recommendations. *World J Gastroenterol* 2014;20:16620-16629.
4. Brown SR, Fearnhead NS, Faiz OD, et al. The Association of Coloproctology of Great Britain and Ireland consensus guidelines in surgery for inflammatory bowel disease. *Colorectal Dis* 2018;20 Suppl 8:3-117.
5. Fazio VW, O'Riordain MG, Lavery IC, et al. Long-term functional outcome and quality of life after stapled restorative proctocolectomy. *Ann Surg* 1999;230:575-584.
6. Murrell ZA, Melmed GY, Ippoliti A, et al. A prospective evaluation of the long-term outcome of ileal pouch-anal anastomosis in patients with inflammatory bowel disease-unclassified and indeterminate colitis. *Dis Colon Rectum* 2009;52:872-878.
7. van Balkom KA, Beld MP, Visschers RG, van Gemert WG, Breukink SO. Long-term results after restorative proctocolectomy with ileal pouch-anal anastomosis at a young age. *Dis Colon Rectum* 2012;55:939-947.
8. Holubar SD, Larson DW, Dozois EJ, Pattana-Arun J, Pemberton JH, Cima RR. Minimally invasive subtotal colectomy and ileal pouch-anal anastomosis for fulminant ulcerative colitis: a reasonable approach? *Dis Colon Rectum* 2009;52:187-192.
9. Hemandas AK, Jenkins JT. Laparoscopic pouch surgery in ulcerative colitis. *Ann Gastroenterol* 2012;25:309-316.
10. Singh P, Bhangu A, Nicholls RJ, Tekkis P. A systematic review and meta-analysis of laparoscopic vs open restorative proctocolectomy. *Colorectal Dis* 2013;15:e340-e351.
11. Konishi T, Ishida H, Ueno H, et al. Feasibility of laparoscopic total proctocolectomy with ileal pouch-anal anastomosis and total colectomy with ileorectal anastomosis for familial adenomatous polyposis: results of a nationwide multicenter study. *Int J Clin Oncol* 2016;21:953-961.
12. Brockhaus AC, Sauerland S, Saad S. Single-incision versus standard multi-incision laparoscopic colectomy in patients with malignant or benign colonic disease: a systematic review, meta-analysis and assessment of the evidence. *BMC Surg* 2016;16:71.
13. Yang TX, Chua TC. Single-incision laparoscopic colectomy versus conventional multiport laparoscopic colectomy: a meta-analysis of comparative studies. *Int J Colorectal Dis* 2013;28:89-101.
14. Remzi FH, Kirat HT, Kaouk JH, Geisler DP. Single-port laparoscopy in colorectal surgery. *Colorectal Dis* 2008;10:823-826.
15. Bucher P, Pugin F, Morel P. Single port access laparoscopic right hemicolectomy. *Int J Colorectal Dis* 2008;23:1013-1016.
16. Dong B, Luo Z, Lu J, et al. Single-incision laparoscopic versus conventional laparoscopic right colectomy: a systematic review and meta-analysis. *Int J Surg* 2018;55:31-38.
17. Leo CA, Samaranayake S, Perry-Woodford ZL, et al. Initial experience of restorative proctocolectomy for ulcerative colitis by transanal total mesorectal rectal excision and single-incision abdominal laparoscopic surgery. *Colorectal Dis* 2016;18:1162-1166.
18. Nagpal A, Soni H, Haribhakti S. Single-incision laparoscopic restorative proctocolectomy with ileal pouch anal anastomosis for ulcerative colitis: first Indian experience and literature review. *Int J Colorectal Dis* 2011;26:525-526.
19. Page MJ, McKenzie JE, Bossuyt PM, et al. The PRISMA 2020 statement: an updated guideline for reporting systematic reviews. *BMJ* 2021;372:n71.
20. Nagpal AP, Soni H, Haribhakti S. Hybrid single-incision laparoscopic restorative proctocolectomy with ileal pouch anal anastomosis for ulcerative colitis. *Indian J Surg* 2010;72:400-403.
21. Agha RA, Fowler AJ, Rajmohan S, Barai I, Orgill DP; PROCESS Group. Preferred reporting of case series in surgery; the PROCESS guidelines. *Int J Surg* 2016;36:319-323.
22. Geisler DP, Condon ET, Remzi FH. Single incision laparoscopic total proctocolectomy with ileopouch anal anastomosis. *Colorectal Dis* 2010;12:941-943.
23. Geisler DP, Kirat HT, Remzi FH. Single-port laparoscopic total proctocolectomy with ileal pouch-anal anastomosis: initial operative experience. *Surg Endosc* 2011;25:2175-2178.
24. Geisler D, Garrett T. Single incision laparoscopic colorectal surgery: a single surgeon experience of 102 consecutive cases. *Tech Coloproctol* 2011;15:397-401.
25. Podolsky ER, Curcillo PG 2nd. Single port access (SPA) surgery—a 24-month experience. *J Gastrointest Surg* 2010;14:759-767.
26. Chambers WM, Bicsak M, Lamparelli M, Dixon AR. Single-incision laparoscopic surgery (SILS) in complex colorectal surgery: a technique offering potential and not just cosmesis. *Colorectal Dis* 2011;13:393-398.
27. Goede AC, Reeves A, Dixon AR. Laparoscopic restorative proctocolectomy: a 10-year experience of an evolving technique. *Colorectal Dis* 2011;13:1153-1157.
28. Gash KJ, Goede AC, Chambers W, Greenslade GL, Dixon AR. Laparoendoscopic single-site surgery is feasible in complex colorectal resections and could enable day case colectomy. *Surg Endosc* 2011;25:835-840.
29. Gash KJ, Goede AC, Kaldowski B, Vestweber B, Dixon AR. Single incision laparoscopic (SILS) restorative proctocolectomy with ileal pouch-anal anastomosis. *Surg Endosc* 2011;25:3877-3880.
30. Vestweber B, Galetin T, Lammerting K, et al. Single-incision laparoscopic surgery: outcomes from 224 colonic resections performed at a single center using SILS. *Surg Endosc* 2013;27:434-442.
31. Leblanc F, Makhija R, Champagne BJ, Delaney CP. Single incision laparoscopic total colectomy and proctocolectomy for benign disease: initial experience. *Colorectal Dis* 2011;13:1290-1293.
32. Stewart DB, Messaris E. Outcomes for consecutive patients undergoing single-site laparoscopic colorectal surgery. *J Gastrointest Surg* 2012;16:849-856.
33. Bulian DR, Knuth J, Krakamp B, Heiss MM. Restorative restproctectomy as single-port surgery through the ostomy site in a three-stage procedure. *Surg Endosc* 2012;26:3688-3690.
34. Costedio MM, Aytac E, Gorgun E, Kiran RP, Remzi FH. Reduced port versus conventional laparoscopic total proctocolectomy and ileal J pouch-anal anastomosis. *Surg Endosc* 2012;26:3495-3499.
35. Potter DD, Tung J, Faubion WA Jr, Moir C. Single-incision laparoscopic colon and rectal surgery for pediatric inflammatory bowel disease and polyposis syndromes. *J Laparoendosc Adv Surg Tech A* 2012;22:203-207.
36. Polites SF, Zarroug AE, Moir CR, Potter DD. Single-incision

- laparoscopic ileal pouch-anal anastomosis in children—how does it compare to a laparoscopic-assisted approach? *J Laparoendosc Adv Surg Tech A* 2015;**25**:167-171.
37. Olson CH, Bedros N, Hakiman H, Araghizadeh FY. Single-site laparoscopic surgery for inflammatory bowel disease. *JSLs* 2014;**18**:258-264.
 38. Perger L, Little DC, Muensterer OJ, Chong AJ, Mortellaro VE, Harmon CM. Minimal access laparoscopic surgery for treatment of ulcerative colitis and familial adenomatous polyposis coli in children and adolescents. *J Laparoendosc Adv Surg Tech A* 2014;**24**:731-734.
 39. Schlager A, Siddharthan RV, Santore MT, Balci O, Clifton MS, Heiss KF. Single-incision total proctocolectomy and ileal pouch anal anastomosis in pediatric patients: lessons learned. *J Laparoendosc Adv Surg Tech A* 2015;**25**:782-785.
 40. Khayat A, Maggiori L, Vicaut E, Ferron M, Panis Y. Does single port improve results of laparoscopic colorectal surgery? A propensity score adjustment analysis. *Surg Endosc* 2015;**29**:3216-3223.
 41. Homma S, Kawamata F, Shibasaki S, Kawamura H, Takahashi N, Taketomi A. Does reduced-port laparoscopic surgery for medically uncontrolled ulcerative colitis do more harm than good? *Asian J Endosc Surg* 2016;**9**:24-31.
 42. Benlice C, Gorgun E. Single-port laparoscopic restorative proctocolectomy with ileal-pouch anal anastomosis using a left lower quadrant ileostomy site - a video vignette. *Colorectal Dis* 2016;**18**:818-819.
 43. Li W, Rencuzogullari A, Costedio M, et al. Outcome comparison of single-port versus multiport versus under direct view completion proctectomy with ileal-pouch anal anastomosis for patients with ulcerative colitis. *Surg Laparosc Endosc Percutan Tech* 2019;**29**:373-377.
 44. Lee YS, Kim JH, Kim HJ, et al. Short-term outcomes of single-port versus multiport laparoscopic surgery for colon cancer: the SIMPLE multicenter randomized clinical trial. *Ann Surg* 2021;**273**:217-223.
 45. Borowski DW, Baker EA, Wilson D, Garg DK, Gill TS. Clinical outcomes and inflammatory response to single-incision laparoscopic (SIL) colorectal surgery: a single-blinded randomized controlled pilot study. *Colorectal Dis* 2019;**21**:79-89.
 46. Li HJ, Huang L, Li TJ, et al. Short-term outcomes of single-incision versus conventional laparoscopic surgery for colorectal diseases: meta-analysis of randomized and prospective evidence. *J Gastrointest Surg* 2017;**21**:1931-1945.
 47. Maggiori L, Tuech JJ, Cotte E, et al. Single-incision laparoscopy versus multiport laparoscopy for colonic surgery: a multicenter, double-blinded, randomized controlled trial. *Ann Surg* 2018;**268**:740-746.
 48. Podda M, Saba A, Porru F, Pisanu A. Systematic review with meta-analysis of studies comparing single-incision laparoscopic colectomy and multiport laparoscopic colectomy. *Surg Endosc* 2016;**30**:4697-4720.
 49. Watanabe J, Ota M, Fujii S, Suwa H, Ishibe A, Endo I. Randomized clinical trial of single-incision versus multiport laparoscopic colectomy. *Br J Surg* 2016;**103**:1276-1281.
 50. Roy S, Evans C. Overview of robotic colorectal surgery: Current and future practical developments. *World J Gastrointest Surg* 2016;**8**:143-150.
 51. Petroni G, Niccolini M, Menciassi A, Dario P, Cuschieri A. A novel intracorporeal assembling robotic system for single-port laparoscopic surgery. *Surg Endosc* 2013;**27**:665-670.
 52. Lightner AL, Grass F, McKenna NP, et al. Short-term postoperative outcomes following robotic versus laparoscopic ileal pouch-anal anastomosis are equivalent. *Tech Coloproctol* 2019;**23**:259-266.
 53. Mark-Christensen A, Pachler FR, Nørager CB, Jepsen P, Laurberg S, Tøttrup A. Short-term Outcome of Robot-assisted and Open IPAA: An Observational Single-center Study. *Dis Colon Rectum* 2016;**59**:201-207.
 54. Rencuzogullari A, Gorgun E, Costedio M, et al. Case-matched Comparison of Robotic Versus Laparoscopic Proctectomy for Inflammatory Bowel Disease. *Surg Laparosc Endosc Percutan Tech* 2016;**26**:e37-e40.

Supplementary Table 1 PRISMA 2020 checklist

Section/Topic	PRISMA Item	Checklist Description	Location in Manuscript
TITLE	1	Identify as a systematic review.	Title page – implicitly a review (suggest adding “systematic review” if required).
ABSTRACT	2	Structured summary of objectives, methods, results, limitations, conclusions.	Abstract – Yes.
INTRODUCTION	3	Rationale for the review.	Introduction – Yes.
INTRODUCTION	4	Explicit statement of the review objectives/ questions.	Introduction last paragraph – Yes.
METHODS – Eligibility criteria	5	Inclusion/exclusion criteria.	Eligibility Criteria section – Yes.
METHODS – Information sources	6	All sources described with dates of coverage.	Search Strategy – Yes.
METHODS – Search strategy	7	Full search strategy (exact terms & Boolean operators).	Search Strategy – Yes.
METHODS – Selection process	8	How studies were screened, number of reviewers, consensus.	Study selection – Yes.
METHODS – Data collection process	9	How data were extracted, number of reviewers.	Data extraction – Yes.
METHODS – Data items	10	Variables sought (outcomes, characteristics).	Data extraction; Outcomes paragraphs – Yes.
METHODS – Risk of bias assessment	11	Methods for evaluating study quality or bias.	<i>Not reported</i> – No. (You may add a sentence if required.)
METHODS – Effect measures	12	Effect measures for synthesis (risk ratios, means).	Not applicable (narrative review).
METHODS – Synthesis methods	13	How results were synthesized; rationale for narrative approach.	Data synthesis – Yes.
METHODS – Reporting bias assessment	14	Assessment of risk of publication bias.	<i>Not reported</i> – No.
METHODS – Certainty assessment	15	Grading certainty (e.g., GRADE).	<i>Not reported</i> – No.
RESULTS – Study selection	16	Numbers at each screening stage; PRISMA flow diagram.	Results: Study selection; Figure 1 – Yes.
RESULTS – Study characteristics	17	Summary of included study characteristics.	Results; Table 1 – Yes.
RESULTS – Risk of bias	18	Summary of bias in included studies.	<i>Not reported</i> – No.
RESULTS – Individual study results	19	Extracted data for each study.	Tables 1–3 – Yes.
RESULTS – Synthesis	20	Summary of synthesized findings.	All Results subsections – Yes.
RESULTS – Reporting biases	21	Reporting bias assessment.	<i>Not reported</i> – No.
RESULTS – Certainty of evidence	22	Certainty (e.g., GRADE).	<i>Not reported</i> – No.
DISCUSSION	23	Interpretation of results in context.	Discussion – Yes.
DISCUSSION	24	Limitations of the included studies.	Limitations section – Yes.
DISCUSSION	25	Limitations of the review process.	Limitations section – Yes.
DISCUSSION	26	Implications for practice, future research.	Concluding remarks – Yes.
OTHER INFORMATION – Registration	27	Registration (e.g., PROSPERO).	<i>Not registered</i> – No.
OTHER INFORMATION – Protocol	28	Where protocol can be accessed.	<i>Not reported</i> – No.
OTHER INFORMATION – Support	29	Sources of financial or non-financial support.	Conflict of interest – partial.
OTHER INFORMATION – Competing interests	30	Declaration provided.	Conflict of Interest section – Yes.
OTHER INFORMATION – Availability of data	31	Availability of data, materials, supplementary files.	Not specified – Partial.