

# High-frequency miniprobe endoscopic ultrasonography for evaluation of indeterminate esophageal strictures

Surinder Singh Rana<sup>a</sup>, Ravi Sharma<sup>a</sup>, Rajesh Gupta<sup>b</sup>

Postgraduate Institute of Medical Education and Research (PGIMER), Chandigarh, India

## Abstract

**Background** Patients with esophageal stricture who have normal mucosa and whose endoscopic biopsies are inconclusive pose a difficult diagnostic dilemma. We prospectively assessed high-frequency miniprobe endoscopic ultrasonography (EUS) for the evaluation of indeterminate esophageal strictures.

**Methods** Over a period of 3 years, 19 patients (14 male; mean age: 58.9±11.6 years) with indeterminate esophageal strictures were studied using high-frequency miniprobe EUS. The final diagnosis was based on definitive cytopathology, surgical pathology or clinical follow up for more than 6 months.

**Results** The etiology of the esophageal stricture was benign in 10 patients (peptic 2, tubercular 2, drug-induced 2, idiopathic 1, post-pancreatitis 1, post-surgical 1, and IgG4-related sclerosing esophagitis 1), and malignant in 9 patients (squamous cell carcinoma 5, and adenocarcinoma 4). The esophageal stricture was located in the upper, mid and lower esophagus in 1, 9 and 9 patients respectively. The mean length of benign and malignant esophageal strictures was 2.4±1.1 cm and 5.3±1.6 cm, respectively (P=0.0003). EUS was performed successfully without dilatation in all patients. Wall stratification was lost in all patients with malignant strictures and in 3/10 (30%) patients with benign strictures (P=0.03). The mean esophageal wall thickness in malignant and benign strictures was 11.7±2.5 mm and 7.1±2.2 mm, respectively (P=0.0005). A wall thickness ≥9 mm had a sensitivity, specificity, and accuracy of 78%, 80%, and 79%, respectively, for the diagnosis of malignancy.

**Conclusions** High-frequency miniprobe EUS provides important diagnostic information about esophageal strictures. Thicker esophageal walls and a loss of wall stratification are more common in malignant strictures.

**Keywords** Endosonography, stricture, malignancy, tuberculosis, corrosive

*Ann Gastroenterol 2018; 31 (6): 680-684*

## Introduction

Esophageal strictures can be benign or malignant and may have various etiologies, including peptic, corrosive

ingestion-induced, tuberculosis, post-surgical (anastomotic), IgG4-related, post-radiation, while drugs are responsible for various benign etiologies [1,2]. The identification of the underlying etiology of an esophageal stricture is usually possible after obtaining a proper history, performing an endoscopy and taking a biopsy from the site of narrowing. Endoscopic mucosal biopsy is usually diagnostic in the presence of a polypoid lesion or unhealthy ulcerated mucosa at the site of esophageal narrowing. However, patients presenting with dysphagia occasionally have no significant history of drugs or corrosive ingestion and endoscopy reveals a stricture with normal overlying mucosa. These patients usually pose a difficult diagnostic challenge, as repeated endoscopic mucosal biopsies are non-diagnostic and cross-sectional imaging, such as computed tomography (CT), shows only non-specific esophageal wall thickening. Many of these patients undergo unnecessary morbid surgical esophagectomy, considering the possibility of esophageal malignancy rather than an underlying

Departments of <sup>a</sup>Gastroenterology (Surinder Singh Rana, Ravi Sharma); <sup>b</sup>Surgery (Rajesh Gupta), Postgraduate Institute of Medical Education and Research (PGIMER), Chandigarh, India

Conflict of Interest: None

Correspondence to: Dr Surinder Singh Rana, Professor, Department of Gastroenterology PGIMER, Chandigarh 160 012, India, e-mail: drsurinderrana@yahoo.co.in

Presented at Digestive Disease Week 2018, Washington DC, USA

Received 19 June 2018; accepted 31 July 2018; published online 14 September 2018

DOI: <https://doi.org/10.20524/aog.2018.0307>

benign disease. Therefore, it is important to accurately differentiate benign from malignant esophageal strictures, as well as identify the underlying benign etiology.

Endoscopic ultrasound (EUS) provides high-resolution images of the gastrointestinal tract (GIT) as well as the surrounding structures. Because of its ability to identify different layers of the GIT wall, it may provide more detailed information in patients with unclassified esophageal strictures in comparison to cross-sectional imaging modalities like CT; thus, it could help differentiate benign from malignant etiologies. We have previously shown that radial EUS provides detailed information about the extent of esophageal injury in patients with various benign etiologies and that this information can predict the response to endoscopic dilatation: patients with *muscularis propria* involvement require more sessions of dilatation than do patients with only mucosal and submucosal involvement [3]. However, the inability to examine the stricture completely because of the lack of maneuverability of the radial echoendoscope was a major limitation of this study. Likewise, conventional echoendoscopes would be able to provide limited information because of their inability to cross the undiagnosed stricture.

However, EUS miniprobes or catheter probes, because of their narrow diameter, can be easily negotiated across the strictures. These probes can be passed through the accessory channel of standard endoscopes without dilatation to provide high-frequency ultrasound images. Because of the use of a higher frequency, images with better resolution and 3D reconstruction can be obtained. However, there is paucity of data on the use of EUS probes for the evaluation of undiagnosed esophageal strictures. We conducted this prospective study to prospectively evaluate the utility of high-frequency miniprobes for the evaluation of esophageal strictures of unknown etiology in a large tertiary care teaching hospital in North India.

## Patients and methods

Over a period of three years (December 2014 to November 2017), all patients with undiagnosed esophageal strictures were prospectively screened for inclusion in the study. The study protocol was approved by the institute's ethics committee and informed consent was obtained from the patients prior to their enrollment in the study.

Inclusion criteria were: a) patients with dysphagia, with no history of corrosive intake or ingestion of drugs known to cause esophageal strictures or mediastinal radiation; b) CT imaging demonstrating thickened esophageal wall; c) endoscopy: non-negotiable stricture in the esophagus with normal mucosa at the mouth of the stricture; and d) endoscopic biopsy from mouth of stricture being non-contributory.

Patients refusing consent, pregnant females, and patients with a previously diagnosed malignancy were excluded. All the enrolled patients underwent EUS examination using an EUS catheter probe. Before enrollment, patients underwent endoscopy and endoscopic biopsy from the mouth of the stricture. Subsequently, a miniprobe EUS examination was

carried out and EUS fine-needle aspiration was performed only in those patients who had a significantly thickened esophageal wall.

## Miniprobe EUS examination

The miniprobe EUS examination was performed using a high-frequency 3-dimensional (3D) catheter probe (20 MHz miniprobe, UM-DG20-31R; Olympus, Tokyo, Japan) with radial, linear, and oblique 3D reconstructions. The procedure was performed with the patient under conscious sedation using intravenous midazolam. Initially, a standard upper esophagoscopy was performed using a standard flexible endoscope positioned at the proximal part of the esophageal stricture. The probe was then inserted through the instrument channel and negotiated across the stricture. If it was not possible to pass the probe across the stricture blindly, a guidewire was inserted across the stricture and the EUS probe was then reinserted over the guidewire. The miniprobe EUS procedure was performed using the direct contact method. Initially, the probe was passed into the distal esophagus beyond the stricture and the EUS examination was performed by gradually withdrawing the probe. The EUS examination used a 20 MHz transducer and the parameters assessed were wall stratification, wall thickness and symmetric or asymmetric thickening, and the presence of any surrounding lymph nodes.

## Final diagnosis

The patients were further assessed and managed as decided by the treating clinician. The final diagnosis was based on either definitive cytopathology obtained by EUS-guided fine-needle aspiration of the esophageal wall from the mouth of the stricture, histopathology of the surgically resected specimen, or clinical follow up of more than 6 months.

## Statistical analysis

The descriptive data were represented as percentages for categorical variables and mean  $\pm$  standard deviation for quantitative variables. Student's *t*-test was used to compare continuous variables and the chi-square test to compare categorical variables. A P-value of  $<0.05$  was considered as significant.

## Results

Over a period of 3 years, 19 patients (14 male; mean age:  $58.9 \pm 11.6$  years) with dysphagia and CT demonstrating esophageal wall thickening were studied (Table 1). On endoscopy, the stricture was non-negotiable in all the patients with normal esophageal mucosa at the stricture mouth and no

**Table 1** Demographic profile of patients

Number of patients	19
Male: Female	14:5
Mean age	58.9±11.6 years
Location of stricture	Upper esophagus: 1 Mid esophagus: 9 Lower esophagus: 9
Grade of dysphagia	Grade 0: None Grade I: 2 Grade II: 12 Grade III: 5 Grade IV: 0
Etiology of stricture	Peptic: 2 Probable drug-induced: 2 Post pancreatitis: 1 Tubercular: 2 IgG4-related: 1 Post surgical: 1 Idiopathic: 1 Squamous cell carcinoma: 5 Adenocarcinoma: 4

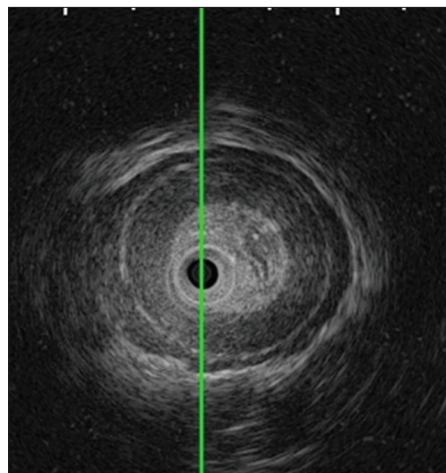
etiology could be identified via histopathological examination of endoscopic biopsies. Catheter-probe EUS was performed using a high-frequency 3D catheter probe.

The esophageal stricture was located in the upper, mid and lower esophagus in 1, 9 and 9 patients respectively. The Mellow–Pinkas dysphagia score was 1 in 2 patients, 2 in 12 patients and 3 in 5 patients. No patient had a dysphagia score of 4. All patients underwent successful catheter-probe EUS without needing dilatation of the esophageal stricture. Of the 19 patients enrolled, the esophageal stricture had an underlying benign etiology in 10 patients and a malignant etiology in 9. The benign etiologies were peptic in 2 patients, tubercular in 2, probable drug-induced in 2, idiopathic in 1, post-pancreatitis in 1, post-surgical in 1, and IgG4-related sclerosing esophagitis in 1 patient. The malignant etiologies were squamous cell carcinoma in 5 patients and adenocarcinoma in 4 patients.

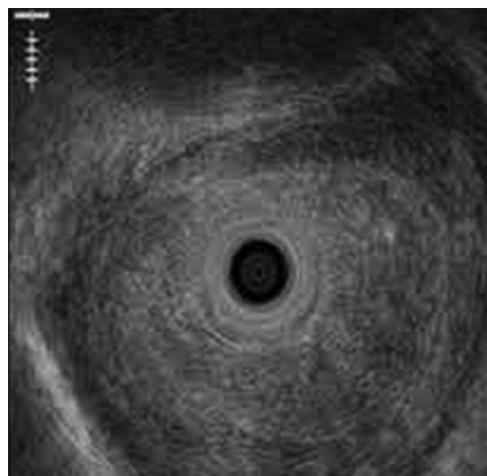
The mean length of benign and malignant esophageal strictures was 2.4±1.1 cm and 5.3±1.6 cm, respectively ( $P=0.0003$ ). The esophageal wall stratification was lost in all the patients with malignant strictures (Fig. 1-3) but in only 3/10 (30%) patients with benign strictures ( $P=0.03$ ). The mean esophageal wall thickness in patients with malignant strictures was 11.7±2.5 mm, significantly greater than in those with benign strictures (7.1±2.2 mm;  $P=0.0005$ ). The loss of wall stratification on EUS had a sensitivity, specificity, negative and positive predictive values of 100%, 70%, 100% and 75%, respectively for the diagnosis of malignancy, whereas a wall thickness of 9 mm or more on EUS had a sensitivity, specificity, and accuracy of 78%, 80%, and 79%, respectively, for the diagnosis of malignancy.

## Discussion

EUS is an excellent imaging modality for the locoregional staging of various gastrointestinal malignancies. This is

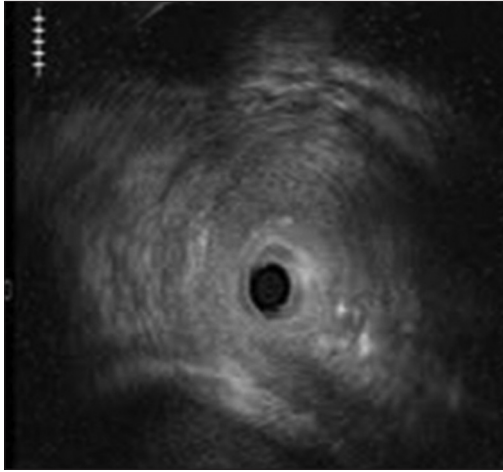


**Figure 1** Preserved wall stratification with mucosal thickness in patient with peptic stricture



**Figure 2** Asymmetric esophageal wall thickness with focal loss of wall stratification in patient with esophageal adenocarcinoma

because of its unique ability to provide high-resolution, cross-sectional, 5-or-more-layered structural images of the GIT wall; thus, the depth of invasion of a malignant lesion can be demonstrated accurately [4-6]. Therefore, EUS can provide more detailed information about the esophageal wall lesion than can conventional endoscopy. Using a conventional radial echoendoscope, we have previously shown that EUS was able to demonstrate the exact depth of esophageal injury in benign esophageal strictures and could thus predict the response to endoscopic dilatation: patients with involvement of the *muscularis propria* required more dilatation sessions than did those with only mucosal and submucosal involvement [3]. However, many patients with esophageal strictures would need endoscopic dilatation before the radial echoendoscope could be negotiated across the stricture. Endoscopic dilatation is associated with significant risks of perforation and bleeding, especially in malignant strictures. Moreover, even after dilatation, the echoendoscope, because of its large diameter, sometimes cannot be maneuvered across the stricture.



**Figure 3** Asymmetric esophageal wall thickness with loss of wall stratification in patient with esophageal squamous cell carcinoma

However, EUS miniprobes or catheter probes, because of their narrow diameter, can easily negotiate the stricture.

Chiu *et al* used catheter-probe EUS safely in 16 patients with acute corrosive injury and demonstrated that EUS could precisely demonstrate the depth of esophageal injury; this information was helpful in predicting bleeding and stricture information [7]. Because of its ability to scan at a high frequency, catheter-probe EUS has also been demonstrated to provide information about perforating collateral vessels in portal hypertension and thus to predict recurrence of varices after endoscopic variceal ligation [8]. Bocus *et al* used catheter EUS in three children with congenital esophageal stenosis and demonstrated that trachea-bronchial remnants could be clearly visualized on EUS [9]. They concluded that miniprobe EUS examination is safe and quick and provides useful prognostic information about the nature and length of a stenosis. Similar observations have also been reported by Usui *et al* in 2 children with congenital esophageal stenosis [10].

In the current study, we used catheter-probe EUS for the evaluation of undiagnosed esophageal strictures and found that patients with malignant esophageal strictures had a thicker wall, with loss of wall stratification, compared to patients with benign esophageal strictures, where the wall stratification was more frequently preserved. To the best of our knowledge, based on a literature search, miniprobe EUS has not been previously used for assessing patients with undiagnosed esophageal strictures. Intraductal ultrasound (IDUS) has been previously used for diagnosing indeterminate strictures and it has been shown that disruption of normal echo layers, heterogeneity of the internal echo pattern, notching or irregularity of the outer border, papillary surface and hypoechoic mass on IDUS are features suggestive of malignancy [11-13]. In addition, malignant biliary strictures have been reported to be thicker than the benign strictures, an observation similar to our own [14].

All patients with malignant strictures had a loss of wall stratification, whereas the wall stratification was lost in only 30% of patients with benign strictures. Wall stratification was

lost in both the patients with tubercular esophageal strictures, as well as the patient with an IgG4-related esophageal stricture, whereas it was preserved in patients with benign strictures of other etiologies. It appears that disease processes involving all the layers of the esophageal wall lead to loss of wall stratification.

The small sample size and the fact that it was a single-center study were important limitations of our investigation. Furthermore, all the observations were recorded by a single observer.

In conclusion, miniprobe EUS provides important diagnostic information about non-negotiable indeterminate esophageal strictures. On EUS, patients with malignant strictures have thicker esophageal walls compared to those with benign strictures, while loss of wall stratification is more common in malignant strictures.

### Summary Box

#### What is already known:

- Patients with esophageal strictures, normal mucosa on endoscopy, esophageal wall thickening on computed tomography and a non-diagnostic mucosal biopsy are a diagnostic challenge
- Endoscopic ultrasound (EUS) provides high-resolution images of the esophageal wall
- EUS provides detailed information about extent of esophageal injury in patients with various benign etiologies and can predict the response to endoscopic dilatation
- Inability to completely examine a stricture the echoendoscope cannot cross, is a major limitation

#### What the new findings are:

- EUS miniprobes can be easily maneuvered across the strictures with no need for dilatation
- Patients with malignant esophageal strictures have thicker esophageal wall with a loss of wall stratification compared to patients with benign esophageal strictures, where the wall stratification is more frequently preserved
- High-frequency miniprobe EUS provides important diagnostic information about non-negotiable indeterminate esophageal strictures

### References

1. Miller LS, Jackson W, McCray W, Chung CY. Benign nonpeptic esophageal strictures: diagnosis and treatment. *Gastrointest Endosc Clin N Am* 1998;8:329-355.
2. Nada R, Rana SS, Sharma R, et al. An unusual cause of dysphagia: isolated IgG 4-related esophageal disease. *Endosc Ultrasound* 2016;5:393-395.
3. Rana SS, Bhasin DK, Singh K. Role of endoscopic ultrasonography

- (EUS) in management of benign esophageal strictures. *Ann Gastroenterol* 2011;**24**:280-284.
4. Scotiniotis IA, Kochman ML, Lewis JD, Furth EE, Rosato EF, Ginsberg GG. Accuracy of EUS in the evaluation of Barrett's esophagus and high-grade dysplasia or intramucosal carcinoma. *Gastrointest Endosc* 2001;**54**:689-696.
  5. May A, Günter E, Roth F, et al. Accuracy of staging in early oesophageal cancer using high resolution endoscopy and high resolution endosonography: a comparative, prospective, and blinded trial. *Gut* 2004;**53**:634-640.
  6. Kelly S, Harris KM, Berry E, et al. A systematic review of the staging performance of endoscopic ultrasound in gastro-oesophageal carcinoma. *Gut* 2001;**49**:534-539.
  7. Chiu HM, Lin JT, Huang SP, Chen CH, Yang CS, Wang HP. Prediction of bleeding and stricture formation after corrosive ingestion by EUS concurrent with upper endoscopy. *Gastrointest Endosc* 2004;**60**:827-833.
  8. Konishi Y, Nakamura T, Kida H, Seno H, Okazaki K, Chiba T. Catheter US probe EUS evaluation of gastric cardia and perigastric vascular structures to predict esophageal variceal recurrence. *Gastrointest Endosc* 2002;**55**:197-203.
  9. Bocus P, Realdon S, Eloubeidi MA, et al. High-frequency miniprobes and 3-dimensional EUS for preoperative evaluation of the etiology of congenital esophageal stenosis in children (with video). *Gastrointest Endosc* 2011;**74**:204-207.
  10. Usui N, Kamata S, Kawahara H, et al. Usefulness of endoscopic ultrasonography in the diagnosis of congenital esophageal stenosis. *J Pediatr Surg* 2002;**37**:1744-1746.
  11. Inui K, Yoshino J, Miyoshi H. Differential diagnosis and treatment of biliary strictures. *Clin Gastroenterol Hepatol* 2009;**7**:S79-S83.
  12. Farrell RJ, Agarwal B, Brandwein SL, Underhill J, Chuttani R, Pleskow DK. Intraductal US is a useful adjunct to ERCP for distinguishing malignant from benign biliary strictures. *Gastrointest Endosc* 2002;**56**:681-687.
  13. Domagk D, Wessling J, Reimer P, et al. Endoscopic retrograde cholangiopancreatography, intraductal ultrasonography, and magnetic resonance cholangiopancreatography in bile duct strictures: a prospective comparison of imaging diagnostics with histopathological correlation. *Am J Gastroenterol* 2004;**99**:1684-1689.
  14. Krishna NB, Saripalli S, Safdar R, Agarwal B. Intraductal US in evaluation of biliary strictures without a mass lesion on CT scan or magnetic resonance imaging: significance of focal wall thickening and extrinsic compression at the stricture site. *Gastrointest Endosc* 2007;**66**:90-96.