

## Endoscopic closure of colonic perforations using over-the-scope clip: a surgeon-sparing technique

Kinesh Changela, Dhuha Alhankawi, Sury Anand, Mahesh Krishnaiah

The Brooklyn Hospital Center - Clinical Affiliate of Mount Sinai Hospital, Brooklyn, NY, USA

The incidence of perforation during diagnostic colonoscopy has been reported to be 0.2%, however this increases to 5% during therapeutic colonoscopy [1]. The current approach to manage these complications encountered during colonoscopy is surgical repair. With the advances in the field of therapeutic endoscopy, the role of over-the-scope clip (OTSC) in managing this dreaded complication seems to be very promising [2]. Although experience in porcine models proved the OTSC's usefulness in the successful closure of full thickness perforations, we still lack experience with humans to label it as a standard approach [3]. Here we would like to share interesting images from our experience with OTSC in dealing with colonic perforations during colonoscopy.

An 87-year-old female with multiple co-morbidities underwent colonoscopy for evaluation of severe iron deficiency anemia and multiple polyps in the past. At the recto-sigmoid junction we found multiple medium sized diverticula, of which one appeared to be different with yellowish tissue suggestive of omentum (Fig. 1A,B). Colonic perforation was suspected and we decided to manage that endoscopically using OTSC 12/6 GC. The endoscopic closure of the defect was performed successfully using the standard OTSC technique (Fig. 1C). Computed tomography of the abdomen with oral contrast revealed no contrast extravasation and the clip completely approximated the defect. The patient was discharged from the hospital after an uneventful observation in the surgical unit for 48 h.

There is limited information available in the current literature regarding the benefits of OTSC in the management of colonic perforation in humans. We believe that the OTSC will be a helpful tool in dealing with iatrogenic colonic perforation, if identified early with a significant level of confidence. In contrast to a surgical approach, usage of the OTSC can potentially avoid surgical and anesthesia complications, shorten the length of hospitalization and be ideal for frail high-risk patients.

Department of Gastroenterology, The Brooklyn Hospital Center - Clinical Affiliate of Mount Sinai Hospital, Brooklyn, NY, USA

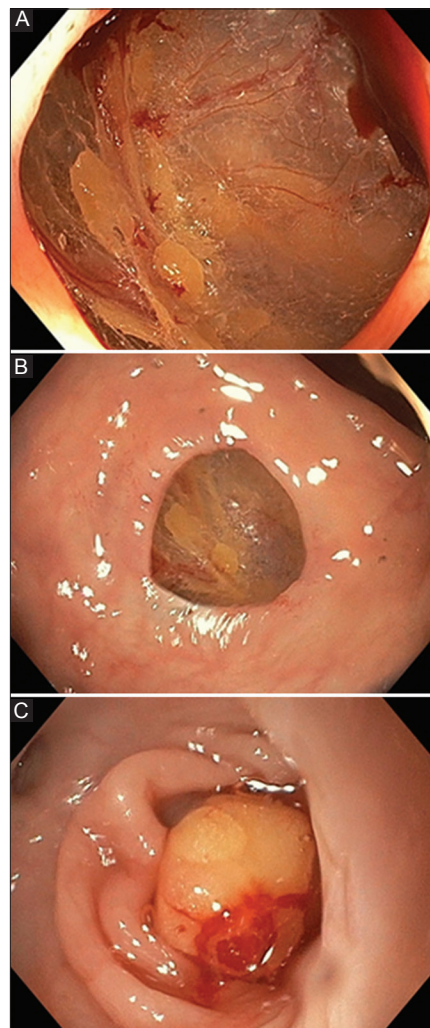
Conflict of Interest: None

Correspondence to: Kinesh Changela, MD, Department of Gastroenterology, The Brooklyn Hospital Center, Clinical affiliate of Mount Sinai Hospital, 121 DeKalb Avenue, Brooklyn, New York 11201, USA, Tel.: +1 516 582 8772, Fax: +1 718 250 8120, e-mail: kinooo2002@gmail.com

Received 14 November 2015; accepted 23 November 2015

DOI: <http://dx.doi.org/10.20524/aog.2016.0019>

© 2016 Hellenic Society of Gastroenterology



**Figure 1** (A, B) Endoscopic images showing contained perforation at the recto-sigmoid junction (C) Endoscopic closure of the defect at the recto-sigmoid junction using standard over-the-scope clip technique

### References

1. Lohsiriwat V. Colonoscopic perforation: incidence, risk factors, management and outcome. *World J Gastroenterol* 2010;**16**:425-430.
2. Changela K, Virk MA, Patel N, Duddempudi S, Krishnaiah M, Anand S. Role of over the scope clips in the management of iatrogenic gastrointestinal perforations. *World J Gastroenterol* 2014;**20**:11460-11462.
3. Singhal S, Changela K, Papafragkakakis H, Anand S, Krishnaiah M, Duddempudi S. Over the scope clip: technique and expanding clinical applications. *J Clin Gastroenterol* 2013;**47**:749-756.

[www.annalsgastro.gr](http://www.annalsgastro.gr)