Annals of Gastroenterology (2026) **39,** 1-9

Gaps in the diagnosis of small bowel adenocarcinoma among patients with Crohn's disease: a tertiary care perspective

Marisa-Nicole S. Zayat[a], Micah Vander Griend[a], Jana G. Hashash[b], Jami Kinnucan[b], Michael Picco[b], Francis A. Farraye[b], Rex K. Siu[a]

Mayo Clinic Florida, USA

Abstract

Background Small bowel adenocarcinoma (SBA) is a rare and serious complication of Crohn's disease (CD), with symptoms often mimicking CD-related symptoms. Therefore, preoperative diagnosis of SBA is difficult, since conventional imaging is rarely diagnostic. This study aims to evaluate the utility of imaging and endoscopic modalities in detecting SBA among patients with CD.

Methods A retrospective review of medical records from a multi-institutional tertiary care center was conducted. ICD-10 codes were used to identify patients with CD who were diagnosed with SBA between January 1, 2019, and November 24, 2024.

Results Of 92 patients identified, 36 met the inclusion criteria. Twenty-one (58.3%) were male, and 35 (97.2%) were Caucasian. The median age at SBA diagnosis was 61 years, with a median 19-year interval from initial CD diagnosis to SBA diagnosis. Thirty-one patients (86.1%) had preoperative imaging, but only 7/31 (22.6%) had findings that raised concern for malignancy. Eight (22.2%) of the patients who underwent endoscopy were diagnosed with SBA or dysplasia on endoscopic biopsy; 18 cases were discovered incidentally during surgery. Sixteen patients (44.4%) had stage III or IV cancer at diagnosis, and 18 patients (50.0%) achieved oncologic remission.

Conclusions Among patients with CD diagnosed with SBA, a large proportion of imaging and endoscopic studies failed to suggest malignancy. Given the substantial proportion of patients diagnosed at advanced stages, and the associated poor outcomes, a high index of suspicion and multimodal evaluation could improve the diagnostic yield in long-standing CD patients with new or changing symptoms.

Keywords Small bowel adenocarcinoma, Crohn's disease, inflammatory bowel disease, small bowel cancer, gastrointestinal malignancy

Ann Gastroenterol 2026; 39 (2): 1-9

[a]Department of Internal Medicine, Mayo Clinic Florida, USA (Marisa-Nicole S. Zayat, Micah Vander Griend, Rex K. Siu); [b]Department of Gastroenterology and Hepatology, Mayo Clinic Florida, USA (Jana G. Hashash, Jami Kinnucan, Michael Picco, Francis A. Farraye)

Conflict of Interest: Dr. Farraye has served as a Consultant for Astellas, Avalo Therapeutics, Bausch, BMS, Braintree Labs, Fresenius Kabi, GI Reviewers, IBD Educational Group, Iterative Health, Janssen, Pharmacosmos, Pfizer, Sandoz Immunology, Viatris. He sits on a DSMB for Eli Lilly and Moon Lake. For the remaining authors none were declared

Correspondence to: Marisa-Nicole S. Zayat, MD, 4500 San Pablo Rd S, Jacksonville, FL, 32224, USA, e-mail: Zayat.MarisaNicole@Mayo.edu

Presented as poster at Digestive Disease Week, San Diego, CA May 2025

Received 4 November 2025; accepted 6 January 2026; published online 18 February 2026

DOI: https://doi.org/10.20524/aog.2026.1047

This is an open access journal, and articles are distributed under the terms of the Creative Commons Attribution-NonCommercial-ShareAlike 4.0 License, which allows others to remix, tweak, and build upon the work non-commercially, as long as appropriate credit is given and the new creations are licensed under the identical terms

Introduction

Small bowel cancers are rare, accounting for less than 3% of overall gastrointestinal tract tumors; among them, small bowel adenocarcinoma (SBA) is one of the most common subtypes [1]. Compared to the general population, patients with Crohn's disease (CD) have a 20- to 40-fold greater risk of developing SBA, with an estimated incidence of 3 per 10,000 patient-years [1-6]. The majority of SBA are identified in the ileum, followed by the jejunum [7,8]. Contributing to its elusive nature is the overlap between the non-specific presenting symptoms of SBA and fibrostenotic or inflammatory CD, such as nausea, vomiting, abdominal pain and weight loss.

Cross-sectional imaging is seldom diagnostic. In 1 meta-analysis, only 11% of all SBAs had concerning radiological features [3], with a large portion of cancers found incidentally at the time of surgical resection [9]. Olson and colleagues also reported that 50% of small bowel neoplasms in patients with ulcerative colitis were diagnosed incidentally at the time of surgery [10]. Imaging findings suggestive of SBA

© 2026 Hellenic Society of Gastroenterology

include a mass, obstructive stricture with abrupt margins/shouldering, irregular nodularity along the serosal margin, heterogenous strictures, high-grade obstruction, irregular and circumferential bowel wall thickening, increased bowel thickness >8-10 mm, perforation, and distant metastases [9,11]. Even with recent advances in computer tomography (CT) and magnetic resonance (MR) imaging, the preoperative detection of small bowel malignancies remains low; Weber *et al* performed reexamination of prior CT and MR imaging and noted a worrisome mass in 7 of 14 patients (50%), compared to 15% (n=2) of the 13 available radiologic reports by the original reading radiologist [11].

Currently, the American College of Gastroenterology, American Gastroenterological Association, and American Society of Gastrointestinal Endoscopy have issued no small bowel cancer surveillance guidelines for patients with inflammatory bowel disease (IBD) [12,13]. A preoperative diagnosis of small bowel malignancy is difficult, and multiple studies have attempted to identify better solutions. Our study aimed to explore the utility of imaging and endoscopic modalities in identifying SBA among patients with CD.

Patients and methods

Patient selection

A retrospective review was performed of patient medical records from a multi-institutional tertiary care center. Patients aged 18 and older, with ICD-10 diagnostic codes for CD (K50.*) and malignant neoplasms of the small bowel (C17.*) between January 1, 2019, and November 24, 2024, were included (Fig. 1). Patients with mixed cancer pathology (multiple primary small bowel cancers), non-adenocarcinoma small bowel cancer, metastatic cancer to the small bowel without identified SBA, SBA diagnosed outside the study dates, and incomplete records were excluded. This project was approved by the Institutional Review Board of the Mayo Clinic.

Data collection

Data from patient medical records were abstracted into and managed in Research Electronic Data Capture. The primary exposure was CD identified with ICD-10 diagnostic code K50.* and SBA identified with ICD-10 diagnostic code C17.*, and the primary outcome was the diagnostic modality: endoscopic biopsy showing high-grade dysplasia or adenocarcinoma, imaging explicitly suspicious for a malignancy, or intraoperative diagnosis.

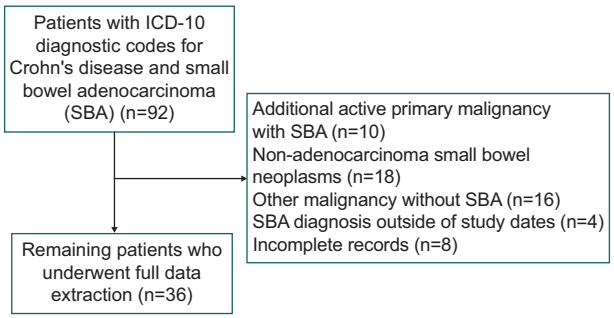

Figure 1 Flow diagram demonstrating patient selection and study cohort derivation

Patient demographics were recorded along with CD-specific variables, including the location of small bowel involvement, IBD phenotype, and history of CD-specific pharmacologic treatment. Additionally, factors specific to small bowel malignancy were documented, including the duration from CD diagnosis to cancer diagnosis, preoperative suspicion of cancer, presenting symptoms, methods of cancer diagnosis, and imaging reports. Preoperative diagnosis in this study was defined as patients with an endoscopic biopsy showing malignancy or dysplasia, and/or imaging studies showing a small bowel mass, or stated uncertainty and/or inability to rule out malignancy. Notably, imaging was performed at the discretion of treating clinicians, without a standardized institutional algorithm. Imaging studies, completed both internally at Mayo Clinic proper and externally, were reviewed based on radiologists' dictated reports. A study was classified as suspicious for malignancy if the impression explicitly mentioned a mass, could not exclude malignancy, or raised concern for neoplasm.

Information on cancer staging and active CD treatment at the time of cancer diagnosis was also collected. In addition, data on cancer treatment received (surgical intervention, chemotherapy, and/or radiation therapy), hospitalizations within 6 months prior to oncologic resection, and response to cancer treatment were recorded.

Bias and study size

To mitigate selection bias, inclusion and exclusion criteria were prespecified, and all eligible encounters were screened using ICD-10 codes for CD (K50.*) and small bowel malignancy (C17.*). This was a descriptive study of all eligible cases, including patients diagnosed with SBA who also had a diagnosis of CD during the study period.

Statistical analysis

Statistical analyses were performed using Excel and IBM SPSS Statistics (Version 29.0.2.0). Sociodemographic characteristics were summarized using descriptive statistics. Medians and standard deviations were reported for continuous variables, and frequencies and percentages for categorical variables. Missing data were recorded as missing; denominators are provided for each analysis. Categorical variables were compared using Fisher's exact tests, unless otherwise noted because of software limitations. Continuous variables were compared using Mann-Whitney *U* tests, given the small sample size and non-normal distributions. Statistical significance was assigned to P-values <0.05. No adjustment

for confounding variables was performed, given the study's exploratory aim.

Results

Patient demographics

A total of 25,751 patients with CD were evaluated during the study period. The initial data search identified 92 patients with diagnoses of CD and small bowel malignancies. Of the 92 charts reviewed, 56 were excluded because of mixed small bowel malignancies with SBA (n=10), non-adenocarcinoma small bowel cancer (n=18), other malignancy with SBA diagnosis (n=16), SBA diagnosis predating the study dates (n=4), and incomplete records (n=8). The remaining 36 patients underwent full data abstraction (Fig. 1); that comprised 0.14% of all patients with CD evaluated during the study period.

Patient demographics (Table 1) include 21 males (58.3%), while 35 (97.2%) identified as Caucasian and not Hispanic. The median body mass index was 23.2 kg/m^2 (interquartile range [IQR] 20.7-28.2). Most patients were never smokers (n=22, 61.1%) while 13 were former smokers (36.1%) and 1 was an active smoker (2.8%). Of those who actively or formerly smoked, the median was 14.5 pack years (IQR 5-34.4). Fourteen (38.9%) reported alcohol consumption. Eight patients reported a family history of gastrointestinal malignancy: 6 of the 8 with a family history of colorectal cancer (75.0%), 1 with a family history of esophageal cancer (12.5%) and 1 with a family history of SBA (12.5%). No patients reported prior or current use of teduglutide.

CD characteristics

Most patients had ileal disease (n=31, 86.1%), and 21 (67.7%) of these 31 patients specifically had terminal ileal involvement of their CD (Table 1). Isolated jejunal disease was present in 2 patients (5.6%), and no patients (0.0%) had duodenal disease. One patient had disease present in both the jejunum and ileum (2.8%), and the location of CD was unspecified in 3 patients (8.3%). A stricturing IBD phenotype predominated (n=22, 61.1%), followed by fistulizing disease (n=12, 33.3%). Common previously tried medications prior to SBA diagnosis included steroids (n=21, 58.3%), adalimumab (n=17, 47.2%), infliximab (n=15, 41.7%), aminosalicylates (n=14, 38.9%), thiopurines (n=14, 38.9%), vedolizumab (n=11, 30.6%), ustekinumab (n=8, 22.2%), methotrexate (n=2, 5.6%), certolizumab (n=2, 5.6%), risankizumab (n=1, 2.8%), and upadacitinib (n=1, 2.8%). Twelve patients (33.3%) had prior IBD-related surgery predating their SBA diagnosis, with a median of 2 prior surgeries. At the time of SBA diagnosis, 9 patients (25.0%) reported their CD to be in clinical remission.

Table 1 Baseline demographics and Crohn's disease characteristics of patients with small bowel adenocarcinoma (N=36)

Variable	Median (IQR) or fraction (%)
Demographics	
Male: Female	21:15
Body mass index, kg/m^2	23.2 (20.7-28.2)
Race	
Caucasian	35/36 (97.2)
African American	1/36 (2.8)
Smoking status	
Never smoker	22/36 (61.1)
Current smoker	1/36 (2.8)
Former smoker	13/36 (36.1)
Pack-years (among ever-smokers)	14.5 (5-34.4)
Alcohol use	14/36 (38.9)
Age at small bowel adenocarcinoma diagnosis, years	61 (52.8-64)
Family history of gastrointestinal malignancy	8/36 (22.2)
Colorectal cancer	6/8 (75.0)
Esophageal cancer	1/8 (12.5)
Small bowel adenocarcinoma	1/8 (12.5)
Crohn's disease characteristics*	
Location of small bowel disease*	
Jejunum	3/36 (8.3)
Ileum	31/36 (86.1)
Terminal ileum	21/31 (67.7)
Disease phenotype*	
Fistulizing	12/36 (33.3)
Stricturing	22/36 (61.1)
Abscess	6/36 (16.7)
Pharmacologic therapies tried	
Aminosalicylates	14/36 (38.9)
Corticosteroids	21/36 (58.3)
Azathioprine, 6-mercaptopurine	14/36 (38.9)
Methotrexate	2/36 (5.6)
Infliximab	15/36 (41.7)
Adalimumab	17/36 (47.2)
Certolizumab	2/36 (5.6)
Ustekinumab	8/36 (22.2)
Risankizumab	1/36 (2.8)
Vedolizumab	11/36 (30.6)
Upadacitinib	1/36 (2.8)
Prior Crohn's disease-related surgery predating SBA diagnosis	12/36 (33.3)
Median number of prior surgeries	2 (1.5-3)
Crohn's disease in clinical remission, patient-reported	9/36 (25.0)

*Values under Crohn's disease location, phenotype, and characteristics may overlap and are not intended to add up to 100%
IQR, interquartile range; SBA, small bowel adenocarcinoma

SBA characteristics

The most prevalent symptom at presentation was abdominal pain (n=20, 55.6%) (Table 2). The median age at SBA diagnosis was 61 years (IQR 53.5-64), with a median of 19 years (IQR 3-30) from the diagnosis of CD to the diagnosis of malignancy (Fig. 2). Fourteen (38.9%) were hospitalized within 6 months preceding their malignancy diagnosis.

At the time of SBA diagnosis, the most common concurrent CD therapy was adalimumab (n=8, 22.2%), followed by steroids (n=6, 16.7%) and infliximab (n=5, 13.9%). Other active CD treatments at the time of SBA diagnosis included thiopurines (n=4, 11.1%), ustekinumab (n=4, 11.1%), vedolizumab (n=3, 8.3%), risankizumab (n=1, 2.8%), upadacitinib (n=1, 2.8%), and aminosalicylates (n=1, 2.8%).

Most of the malignancies were located in the ileum (n=24, 66.7%), with 16 (44.4%) located specifically in the terminal ileum. Jejunal involvement was noted in 5 cases (13.9%), and duodenal involvement in 2 (5.6%). In 5 patients (13.9%), the precise tumor location could not be determined from available records. Comparing the tumor location with the patient's underlying CD distribution, 25 were concordant, 3 were discordant, and 8 were unclear because either the CD site, the SBA site, or both were not discretely documented.

At diagnosis, 10 patients (27.8%) had stage I disease, 10 (27.8%) stage II, 9 (25.0%) stage III and 7 (19.4%) stage IV. Nearly all patients (35, 97.2%) underwent surgical resection; 20 (55.6%) received chemotherapy, and 3 (8.3%) received radiation. At the time of chart review, 18 patients (50.0%) were considered to be in cancer remission, and the mortality rate was 19.4% (n=7). Of the 18 patients in remission, stage at diagnosis correlated with outcome: 6 (33.3%) patients were stage I, 7 (38.9%) stage II, 4 (22.2%) stage III, and 1 (5.6%) stage IV. Cancer stage was not significantly associated with cancer remission status (P=0.125, when cancer stages I and II were combined into a localized cohort, and cancer stages III and IV were combined into an advanced cohort).

Preoperative and perioperative SBA diagnosis

In total, 15 patients (41.7%) had a preoperative endoscopic or imaging diagnosis suggestive or confirmed with cancer (Table 3). In contrast, 21 patients (58.3%) were diagnosed intraoperatively or histologically at the time of surgical resection.

All patients underwent preoperative endoscopic evaluation (Table 4). Nine patients (25.0%) underwent esophagogastroduodenoscopy, 27 (75%) underwent colonoscopy, 3 (8.3%) underwent pouchoscopy, and 1 (2.8%) underwent ileoscopy at some point prior to SBA diagnosis.

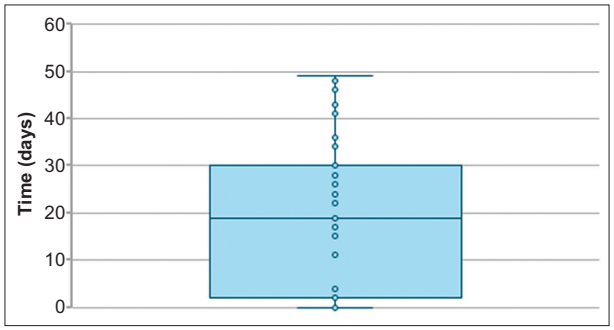

Figure 2 Box-and-whisker plot demonstrating the time interval in years between the diagnosis of Crohn's disease and the diagnosis of small bowel adenocarcinoma

Table 2 Small bowel adenocarcinoma characteristics in patients with Crohn's disease (N=36)

Variable	Median (IQR) or fraction (%)
Interval from Crohn's disease to small bowel adenocarcinoma diagnosis, years	19 (3-30)
Active Crohn's disease treatment(s) at time of small bowel adenocarcinoma diagnosis*	
Aminosalicylates	1/36 (2.8)
Corticosteroids	6/36 (16.7)
Azathioprine, 6-mercaptopurine	4/36 (11.1)
Infliximab	5/36 (13.9)
Adalimumab	8/36 (22.2)
Ustekinumab	4/36 (11.1)
Risankizumab	1/36 (2.8)
Vedolizumab	3/36 (8.3)
Upadacitinib	1/36 (2.8)
Presenting symptoms*	
Abdominal pain	20/36 (55.6)
Weight loss	8/36 (22.2)
Gastrointestinal bleed	2/36 (5.6)
Nausea and/or vomiting	11/36 (30.6)
Changes in bowel habits	7/36 (19.4)
Fatigue	1/36 (2.8)
Abdominal distention	5/36 (13.9)
Anemia	2/36 (5.6)
Location of small bowel adenocarcinoma	
Duodenum	2/36 (5.6)
Jejunum	5/36 (13.9)
Ileum	24/36 (66.7)
Terminal ileum	16/36 (44.4)
Unclassified location	5/36 (13.9)
Cancer staging	
Stage II	10/36 (27.8)
Stage III	9/36 (25.0)
Stage IV	7/36 (19.4)
Unclassified	1/36 (2.8)
Cancer interventions*	
Surgical resection	35/36 (97.2)
Chemotherapy	20/36 (55.6)
Radiation	3/36 (8.3)
Oncologic outcomes	
Remission	18/36 (50.0)
Progressive disease	6/36 (16.7)
Cancer recurrence	4/36 (11.1)
Death	7/36 (19.4)

*Values under active Crohn's disease treatment, presenting symptoms and cancer interventions may overlap among patients and are not intended to add up to 100%
IQR, interquartile range

Table 3 Diagnostic modalities for small bowel adenocarcinoma in patients with Crohn's disease

Variables	Fraction (%)
Pre-operative diagnosis of dysplasia or malignancy	15/36 (41.7)
Endoscopic diagnosis	8/36 (22.2)
Imaging diagnosis	7/36 (19.4)
Incidental diagnosis at time of surgery	21/36 (58.3)

IQR, interquartile range

Table 4 Endoscopic modalities and diagnostic yield in patients with Crohn's disease and small bowel adenocarcinoma

Variables	Median (IQR) or fraction (%)
Endoscopic modalities performed	
Esophagogastroduodenoscopy	9/36 (25.0)
Antegrade double-balloon enteroscopy	2/36 (5.6)
Endoscopic ultrasound	1/36 (2.8)
Colonoscopy	27/36 (75.0)
Retrograde single balloon enteroscopy	1/36 (2.8)
Pouchoscopy	3/36 (8.3)
Ileoscopy	1/36 (2.8)
Capsule endoscopy	0/36 (0)
Positive biopsy with dysplasia or adenocarcinoma per endoscopic modality	
Esophagogastroduodenoscopy	2/36 (5.6)
Antegrade double-balloon enteroscopy	1/36 (2.8)
Colonoscopy	5/36 (13.9)
Pouchoscopy	2/36 (5.6)

*Values under active endoscopic modalities performed may overlap among patients and are not intended to add up to 100%
IQR, interquartile range

The median number of days between the patient's colonoscopy and their SBA diagnosis was 95.5 (IQR 20.75-377.50) for all patients (n=36), and 67.50 (IQR 4.50-251.75) for patients with ileal or terminal ileal cancer (n=24; Fig. 3). Among patients with ileal or terminal ileal SBA who had colonoscopies within 1 year of SBA diagnosis (n=19), 15 reports noted successful intubation of the terminal ileum, 3 failed to intubate the terminal ileum, while 1 report did not document whether the terminal ileum was intubated. Six reports noted how far into the ileum they were able to intubate, with a median of 7 cm (IQR 3.25-10). Among advanced endoscopic modalities, 1 patient underwent retrograde single-balloon enteroscopy, 2 had antegrade double-balloon enteroscopy, and 1 underwent endoscopic ultrasound.

Eight patients (22.2%) had biopsy findings diagnostic of adenocarcinoma or dysplasia—most commonly during colonoscopy (n=5, 13.9%), followed by pouchoscopy (n=2, 5.6%), and antegrade double-balloon enteroscopy (n=1, 2.8%). Cross-sectional imaging with concerning imaging findings led to an additional 2 biopsy-proven cases. No patients underwent capsule endoscopy.

Thirty-one patients (86.1%) had preoperative imaging (table 5) within approximately 1 year of SBA diagnosis, with several having been evaluated using multiple imaging modalities. Cross-sectional imaging included CT with

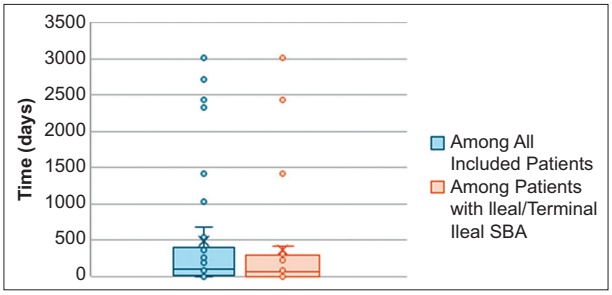

Figure 3 Box-and-whisker plot demonstrating the time interval in days between the date of colonoscopy and the diagnosis of small bowel adenocarcinoma (SBA)

intravenous (i.v.) contrast (14/31, 45.2%), CT without i.v. contrast (2/31, 6.5%), CT enterography (CTE; 8/31, 25.8%), MR imaging with i.v. contrast (5/31, 16.1%), MR with magnetic resonance cholangiopancreatography (2/31, 6.5%), MR enterography (MRE; 10/31, 32.2%), nuclear medicine positron emission tomography (PET; 1/31, 3.2%), and PET/CT scan (1/31, 3.2%). Of these 31 patients with preoperative imaging, 7 studies (22.6%) were suspicious for malignancy: 2 CTE, 1 CT with i.v. contrast, 1 nuclear medicine PET scan, 2 MRE, and 1 from a review of multiple outside images (including CTE, PET/CT, and CT abdomen and pelvis with i.v. contrast). Notably, 17 patients had undergone an MRE at some point prior to their SBA diagnosis; 13/17 (76.5%) of these MREs were for symptom evaluation, 2/17 (11.8%) did not state an explicit indication, 1 (5.9%) was for preoperative evaluation that was planned prior to formal SBA diagnosis, and 1 (5.9%) was for surveillance. The median number of days between MRE and SBA diagnosis was 91 (IQR 8-546; Figure 4).

Of the 7 reports with concern for malignancy, 6 (85.7%) radiographic reports noted a mass, 4 (57.1%) noted bowel wall thickening, and 3 (42.9%) noted lymphadenopathy. A concern for stricture was reported on 3 (42.9%) imaging studies, active inflammation consistent with CD was noted in 4 (57.1%) reports, ascites in 1 (14.3%) imaging study, a contained perforation in 1 (14.3%), and a developing small bowel obstruction (SBO) in 1 (14.3%).

Among the 24 patients with imaging not initially concerning for cancer, findings included active inflammation consistent with CD (14/24, 58.3%), fistula(s) (5/24, 20.8%), stricture(s) (9/24, 37.5%), complete SBO (2/24, 8.3%), partial or developing SBO (4/24, 16.7%), abscesses (1/24, 4.2%), phlegmon (1/24, 4.2%), contained perforation (1/24, 4.2%), ischemia (1/24, 4.2%), lymphadenopathy (1/24, 4.2%), bowel wall thickening (1/24, 4.2%), and gastric outlet abnormality (1/24, 4.2%).

Comparative analysis of preoperative and intraoperative detection

Diagnostic timing (pre- versus intraoperative diagnosis) did not demonstrate statistical significance when evaluating

Table 5 Imaging modalities and radiographic findings in patients with Crohn's disease and small bowel adenocarcinoma

Variables	Median (IQR) or fraction (%)
Imaging modalities performed*	31/36 (86.1)
CT abdomen/pelvis with i.v. contrast	14/31 (45.2)
CT abdomen/pelvis without i.v. contrast	2/31 (6.5)
CT enterography	8/31 (25.8)
MR with i.v. contrast	5/31 (16.1)
MR abdomen with MRCP	2/31 (6.5)
NM PET	1/31 (3.2)
PET/CT	1/31 (3.2)
Imaging studies suspicious for malignancy	7/31 (22.6)
CT abdomen/pelvis with i.v. contrast	1/7 (14.3)
CT enterography	2/7 (28.6)
MR enterography	2/7 (28.6)
NM PET	1/7 (14.3)
Multimodal imaging (CT abdomen and pelvis with i.v. contrast, CT enterography, PET/CT)	1/7 (14.3)
Findings in imaging reports with suspicion for malignancy, n=7*	
Mass	6/7 (85.7)
Bowel wall thickening	4/7 (57.1)
Lymphadenopathy	3/7 (42.9)
Stricture	3/7 (42.9)
Active inflammation consistent with Crohn's disease	4/7 (57.1)
Ascites	1/7 (14.3)
Contained perforation	1/7 (14.3)
Partial or developing SBO	1/7 (14.3)
Findings in imaging reports without suspicion for malignancy, n=24*	
Active inflammation consistent with CD	14/24 (58.3)
Fistula(s)	5/24 (20.8)
Stricture(s)	9/24 (37.5)
Complete SBO	2/24 (8.3)
Partial or developing SBO	4/24 (16.7)
Abscess	1/24 (4.2)
Phlegmon	1/24 (4.2)
Lymphadenopathy	1/24 (4.2)
Ischemia	1/24 (4.2)
Bowel wall thickening	1/24 (4.2)
Contained perforation	1/24 (4.2)
Gastric outlet abnormality	1/24 (4.2)

*Values under imaging modalities performed and imaging findings may overlap among patients and are not intended to add up to 100%
IQR, interquartile range, CT, computed tomography, i.v., intravenous, MR, magnetic resonance, MRCP, magnetic resonance cholangiopancreatography, NM, nuclear medicine; PET, positron emission tomography; SBO, small bowel obstruction

patients based on CD location (P=0.630 for ileal CD, P=0.090 for terminal ileal CD, and P>0.99 for jejunal CD), inflammatory bowel disease phenotype (P=0.499 for stricturing CD, P=0.282 for fistulizing CD, and P>0.99 for abscess forming CD), history of prior surgical intervention for CD-related complications (P=0.499), or patient-reported CD activity (P=0.427) (Table 6). Additionally, diagnostic timing was not associated with SBA cancer stage (P=0.500) or hospitalization within 6 months of SBA diagnosis (P>0.99). While MR with i.v. contrast was associated with a greater frequency of

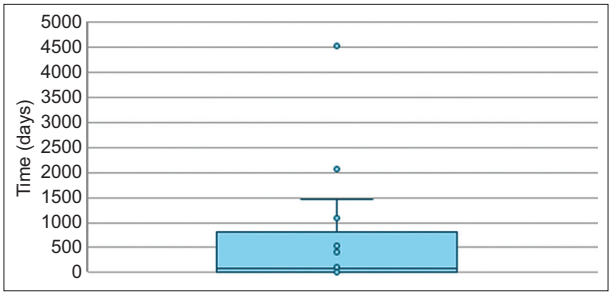

Figure 4 Box-and-whisker plot demonstrating the time interval in days between the date of magnetic resonance enterography (MRE) and the diagnosis of small bowel adenocarcinoma

preoperative diagnosis compared to intraoperative diagnosis (n=5/12 versus 0/19, P=0.005), other imaging modalities and endoscopic modalities were not associated with statistically significant differences in the timing of SBA diagnosis. Successful advancement of the colonoscope into the terminal ileum (P=0.389) and CD disease duration (P=0.853) were also not statistically significant.

Discussion

SBA in patients with CD is rare, but remains a diagnostic dilemma: in the absence of specific recommendations, clinicians must fall back on their clinical acumen to triage this high-risk population. The current study demonstrated that 0.14% of patients with CD were complicated by SBA during the study period; however, this frequency reflects a center-specific proportion over a period of time, rather than an incidence rate. The fact that it was within a tertiary center, with high referral volume and high case-mix index, limits its overall generalizability. This proportion needs to be extrapolated with caution, as it may overestimate the true disease burden relative to community centers. Risk factors for SBA in CD include male sex, chronic penetrating disease, disease duration, previous strictureplasties, and the presence of distal small bowel disease [9,14]. Although a meta-analysis from 2011 showed no significant association between CD duration and SBA [15], a more recent prospective observational study in France of 8222 patients with small bowel CD noted a difference between SBA standardized incidence rates when comparing patients with <8 years of CD (0.0787 per 1000 patient years, odds ratio [OR] 17.8, 95% confidence interval [CI] 0.45-99.1) to those with >8 years (0.464 per 1000 patient years, OR 46.0, 95%CI 12.5-117.8) [4]. The current study demonstrates that most patients were male (58.3%), had stricturing disease (61.1%), with ileal involvement (86.1%), were a median of 61 years old (IQR 53.5-64), and had a median of 19 years (IQR 3-30) of CD duration by the time of SBA diagnosis.

In our cohort, 15/36 (41.7%) of the patients had a preoperative diagnosis established either endoscopically or radiographically. Of the 15 patients, nearly half (8/15, 53.3%) were diagnosed endoscopically, while the remainder (7/15,

AQ1 **Table 6** Comparison of clinical features and diagnostic workup by diagnostic timing (pre- and intra-operative diagnosis)

Variable	Preoperative diagnosis (n=15)	Intraoperative diagnosis (n=21)	P-value
	Median (IQR) or fraction (%)	Median (IQR) or fraction (%)	
Crohn's disease location*			
Ileum	12/15 (80.0)	19/21 (90.5)	0.630
Terminal ileum	6/15 (40.0)	15/21 (71.4)	0.090
Jejunum	1/15 (6.7)	2/21 (9.5)	>0.99
Crohn's disease phenotype*			
Stricturing	8/15 (53.3)	14/21 (66.7)	0.499
Fistulizing	3/15 (20.0)	9/21 (42.9)	0.282
Abscess forming	2 (13.3)	4/21 (19.1)	>0.99
Inflammatory	1 (7.7)	4/21 (19.1)	0.376
Prior Crohn's disease-related surgery	6/15 (40.0)	6/21 (28.6)	0.499
Active Crohn's disease (n=32)	8/13 (61.5)	15/19 (78.9)	0.427
Small bowel adenocarcinoma stage			0.500
Localized stage (stage I-II SBA)	7/15 (46.7)	13/21 (61.9)	
Advanced stage (stage III–IV SBA)	8/15 (53.3)	8/21 (38.1)	
Hospitalized within 6 months of SBA diagnosis	6/15 (40.0)	8/21 (38.1)	>0.99
Pre-diagnosis imaging modalities completed*			
Non-contrast CT	0/12 (0.0)	2/19 (10.5)	0.510
CT with i.v. contrast	8/12 (66.7)	12/19 (63.2)	>0.99
CTE	3/12 (25.0)	10/19 (52.6)	0.158
MR with i.v. contrast	5/12 (41.7)	0/19 (0.0)	0.005
MRE	3/12 (25.0)	7/19 (36.8)	0.697
MR/MRCP	2/12 (16.7)	0/19 (0.0)	0.142
PET scan	2/12 (16.7)	0/19 (0.0)	0.142
Pre-diagnosis endoscopic modalities completed*			
Esophagogastroduodenoscopy	4/15 (26.7)	5/21 (23.8)	>0.99
Colonoscopy	10/15 (66.7)	17/21 (81.0)	0.443
Pouchoscopy	2/15 (13.3)	1/21 (4.8)	0.559
Ileoscopy	1/15 (6.7)	0/21 (0.0)	0.417
Successful advancement into the terminal ileum (n=19)	6/9 (66.7)	9/10 (90.0)	0.389**
Disease duration, years	19.5 (2.0-30.0)	16 (1.5-31.5)	0.853

*Values under active Crohn's disease location and phenotype as well as pre-diagnosis imaging and endoscopic modalities completed may overlap among patients and are not intended to add up to 100%

**To evaluate whether advancement into the terminal ileum was successful by diagnostic timing (pre- versus intraoperative diagnosis), Pearson's chi-square test was applied because of software limitations

IQR, interquartile range, SBA, small bowel adenocarcinoma, CT, computed tomography, i.v., intravenous, CTE, computed tomography enterography, MR, magnetic resonance, MRE, magnetic resonance enterography, MRCP, magnetic resonance cholangiopancreatography, NM PET, nuclear medicine positron emission tomography, SBO, small bowel obstruction

46.7%) were diagnosed radiographically, which highlights how various modalities may be useful for evaluating patients with CD who are at risk for SBA. Other studies investigating the preoperative diagnosis of SBA vary, with small populations (n=9 and 14) showing up to 15-56%, and larger studies (n=29 and 36) reporting 5-11% [7,8,11,16]. Urquhart and colleagues retrospectively reviewed patient charts over an approximately 30-year period, and found 54 patients with small bowel neoplasms—47 of which were SBA [17]. Urquhart's study noted that 61.1% were diagnosed at the time of surgery, 16.7% by endoscopy and 16.7% by cross-sectional imaging [18]. Our cohort of patients with CD and SBA is one of the largest to date, including 36 patients. Multiple factors may have influenced our preoperative diagnostic rate of 41.7%, including advances in radiographic imaging technology, the presence of specialized abdominal radiologists at our institution, and the potential for a higher frequency of endoscopic monitoring. Notably, 75.0% of our study population had active CD, with 38.9% requiring hospitalization within 6 months prior to their cancer diagnosis. While active disease status can also influence clinical judgment by introducing framing and anchoring effects that could potentially impair the assessment of imaging modalities and reduce the frequency of preoperative diagnoses, our study did not identify a significant relationship between disease remission status and diagnostic timing (pre- versus intraoperative diagnosis).

A heightened degree of suspicion, with consideration for early surgical intervention, is crucial, particularly when considering that nearly half of our patients (44.4%) were diagnosed with stage III or IV cancer at the time of surgical intervention. One study suggested that small bowel cancer is diagnosed at stage IV in approximately one third of patients [12]. Conversely, Chappe *et al* demonstrated that SBAs were diagnosed at T3-T4 in 89% of cases, with metastases noted in 31% of cases. Urquhart *et al* reported metastatic disease in 41%, with histologic tumor grade 3 in 41% and grade 4 in 20% of patients [17]. The high prevalence of advanced neoplasms in the current study, as well as other published studies, highlights the potential presence of delays in early recognition and diagnosis.

Of our patients, 97.2% underwent surgery, while 1 patient selected a hospice approach. Chemotherapy was used in approximately half of the patients, while radiation was used in less than 10%. The literature suggests that, for the management of localized jejunal and ileal tumors, segmental resection of the diseased small intestine and associated mesentery has been shown to be curative [12]. While our study demonstrated an SBA remission rate of 50.0% at time of chart review, literature reports suggest that small bowel cancers have high rates of both local and distant recurrence, with a 39% recurrence rate being cited [12].

Although our study was multi-institutional, including patients from 3 distinct geographic regions, it was inherently limited by its retrospective design. Reliance on ICD-10 codes may have missed cases miscoded under nonspecific small bowel neoplasm categories, resulting in potential selection bias; however, combinations including the ICD-10 codes K50.* and C17.* were interrogated to reduce this risk. Various imaging modalities were undertaken, based on clinical presentation and referring provider preference, resulting in nonuniform imaging protocols across the cohort. Additionally, this cohort's multimodal approach, with advanced imaging techniques, specialized abdominal radiologists and management by IBD specialists, can potentially play a role in overcoming differences in detection rates, although there is still room for improvement. Finally, the descriptive representation of data and lack of a comparator group do not permit causal conclusions to be drawn, and inherently limit generalizability. Further research is needed to determine diagnostic solutions, screening high-risk patients with SBA through pooling samples, and evaluation via meta-analysis to overcome inherent limitations, given the rarity of SBA and overall small sample size.

In conclusion, a heightened suspicion for SBA should be maintained, and physicians should consider using a combination of endoscopic, radiographic, and surgical methods to diagnose SBA in patients with CD, whenever possible. Given that most patients' imaging studies did not report a concern for malignancy, it is prudent to maintain a high suspicion for malignancy in patients with long-standing CD and a heightened awareness of the role of surgical intervention in these patients.

Summary Box

What is already known:

- Small bowel adenocarcinoma (SBA) is a rare but serious complication of Crohn's disease (CD), with symptoms often mimicking symptoms of inflammatory bowel disease flares
- Cross-sectional imaging is rarely diagnostic
- Currently, the American College of Gastroenterology, the American Gastroenterological Association and the American Society of Gastrointestinal Endoscopy have not issued any small bowel cancer surveillance guidelines for patients with inflammatory bowel disease

What the new findings are:

- Among patients with CD diagnosed with SBA, a large portion of imaging and endoscopic studies failed to suggest malignancy, with 21 (58.3%) in the current study being diagnosed intraoperatively or histologically at the time of surgical resection
- Completion of magnetic resonance imaging with intravenous contrast was associated with a significantly greater likelihood of a preoperative diagnosis; however, no other diagnostic modalities were associated with non-incidental cancer identification
- Therefore, physicians should consider a multimodal approach to the management of patients with CD, to evaluate new or worsening CD symptoms
- Given that most patients' imaging studies did not report a concern for malignancy, clinicians should maintain a high suspicion for malignancy in patients with long-standing CD and a heightened awareness of the role of surgical intervention in these patients

References

1. Annese V, Beaugerie L, Egan L, et al; ECCO. European evidence-based consensus: inflammatory bowel disease and malignancies. *J Crohns Colitis* 2015;**9**:945-965.
2. Annese V. Small bowel adenocarcinoma in Crohn's disease: an underestimated risk? *J Crohns Colitis* 2020;**14**:285-286.
3. Chin YH, Jain SR, Lee MH, et al. Small bowel adenocarcinoma in Crohn's disease: a systematic review and meta-analysis of the prevalence, manifestation, histopathology, and outcomes. *Int J Colorectal Dis* 2022;**37**:239-250.
4. Elriz K, Carrat F, Carbonnel F, Marthey L, Bouvier AM, Beaugerie L; CESAME study group. Incidence, presentation, and prognosis of small bowel adenocarcinoma in patients with small bowel Crohn's disease: a prospective observational study. *Inflamm Bowel Dis* 2013;**19**:1823-1826.

5. Alsakarneh S, Ahmed M, Azim S, Hashash JG, Farraye FA, Ghoz H. Risk of small intestine cancer in inflammatory bowel disease: a propensity-matched study from a large multi-center database in the United States. *Am J Gastroenterol* 2024;**119**:2334-2337.
6. Axelrad JE, Hashash JG, Itzkowitz SH. AGA clinical practice update on management of inflammatory bowel disease in patients with malignancy: commentary. *Clin Gastroenterol Hepatol* 2024;**22**:1365-1372.
7. Palascak-Juif V, Bouvier AM, Cosnes J, et al. Small bowel adenocarcinoma in patients with Crohn's disease compared with small bowel adenocarcinoma de novo. *Inflamm Bowel Dis* 2005;**11**:828-832.
8. Widmar M, Greenstein AJ, Sachar DB, Harpaz N, Bauer JJ, Greenstein AJ. Small bowel adenocarcinoma in Crohn's disease. *J Gastrointest Surg* 2011;**15**:797-802.
9. Chappe C, Salut C, Amiot A, et al. Preoperative predictors of neoplasia in patients undergoing small bowel resection for complicated Crohn's disease: a multicentre case-control study. *Cancers (Basel)* 2023;**15**:2004.
10. Olson CG, Picco M, Farraye FA, Hashash JG, Kinnucan J. Clinical characteristics of patients with ulcerative colitis and small intestinal malignancy. *Crohns Colitis 360* 2025;**7**:otaf041.
11. Weber NK, Fletcher JG, Fidler JL, et al. Clinical characteristics and imaging features of small bowel adenocarcinomas in Crohn's disease. *Abdom Imaging* 2015;**40**:1060-1067.
12. Bhatt H, Mathis KL. Small bowel carcinoma in the setting of inflammatory bowel disease. *Clin Colon Rectal Surg* 2024;**37**:46-52.
13. Caldera F, Kane S, Long M, Hashash JG. AGA clinical practice update on noncolorectal cancer screening and vaccinations in patients with inflammatory bowel disease: expert review. *Clin Gastroenterol Hepatol* 2025;**23**:695-706.
14. Egan L, D'Inca R, Jess T, et al. Non-colorectal intestinal tract carcinomas in inflammatory bowel disease: results of the 3rd ECCO Pathogenesis Scientific Workshop (II). *J Crohns Colitis* 2014;**8**:19-30.
15. Laukoetter MG, Mennigen R, Hannig CM, et al. Intestinal cancer risk in Crohn's disease: a meta-analysis. *J Gastrointest Surg* 2011;**15**:576-583.
16. Grolleau C, Pote NM, Guedj NS, et al. Small bowel adenocarcinoma complicating Crohn's disease: a single-centre experience emphasizing the importance of screening for dysplasia. *Virchows Arch* 2017;**471**:611-617.
17. Urquhart SA, Smyrk TC, Harmsen WS, Loftus EV Jr, Kisiel JB, Coelho-Prabhu N. Clinical characteristics and outcomes of small bowel neoplasms in Crohn's disease: a case-control study. *Crohns Colitis 360* 2025;**7**:otaf001.