Annals of Gastroenterology (2026) **39,** 1-7

Long-term outcome after endoscopic ultrasound-guided pancreatic duct drainage

Anouk Voutaz[a], Elodie Romailler[b], Mariola Marx[b], Meddy Dalex[b], Marie Philippart[b], Domenico Galasso[b], Sébastien Godat[b]

eHnv, Yverdon-les-Bains, Switzerland; CHUV, Lausanne, Switzerland

Abstract

Background Obstruction of the main pancreatic duct (MPD) may result in severe pain, recurrent pancreatitis, and pancreatic insufficiency. Endoscopic retrograde cholangiopancreatography (ERCP) with pancreatic duct cannulation and stent placement is the standard first-line approach, yet it sometimes fails or is not feasible. Endoscopic ultrasound-guided pancreatic duct drainage (EUS-PDD) has emerged as a surgical alternative. We assessed the long-term outcomes, safety, and technical aspects of EUS-PDD.

Methods We retrospectively reviewed all adult patients who underwent EUS-PDD at a tertiary referral center between April 2016 and November 2022. Only patients who underwent pancreatogastrostomy or pancreatojejunostomy and had at least 12 months of follow up were included. Clinical success was defined as a residual visual analog scale score ≤2 without obstructive pancreatitis recurrence. Adverse events, reinterventions, and long-term outcomes were analyzed.

Results Thirty-five patients (mean age 58±11 years; 74% male) were included, with a mean follow up of 23±19 months. Chronic pancreatitis accounted for 54% of indications. Technical success was achieved in all patients. Overall clinical success was 80% (95% confidence interval [CI] 64-91%). Adverse events occurred in 17% (95%CI 7-33%), including severe events in 6%. Reintervention was required in 29% of patients, mainly because of stent dysfunction. During follow up, 26% experienced pancreatitis, most commonly related to stent dysfunction. Two deaths occurred, unrelated to pancreatic disease or the procedure.

Conclusion EUS-guided pancreatic duct drainage is a safe and effective long-term treatment option in selected patients with MPD obstruction or disruption when ERCP is not feasible, providing durable symptom control with acceptable morbidity.

Keywords Endoscopic ultrasound-guided pancreatic duct drainage, endoscopic retrograde cholangiopancreatography, pancreatic duct cannulation, stent placement

Ann Gastroenterol 2026; 39 (2): 1-7

[a]Department of Internal Medicine, eHnv, Yverdon-les-Bains, Switzerland (Anouk Voutaz); [b]Department of Gastroenterology and Hepatology, CHUV, Lausanne, Switzerland (Elodie Romailler, Mariola Marx, Meddy Dalex, Marie Philippart, Domenico Galasso, Sébastien Godat)

Conflict of Interest: None

Correspondence to: Dre Anouk Voutaz, Department of Internal Medicine, Rue de Plaisance 2 1400 Yverdon-les-Bains, Switzerland, e-mail: anouk.voutaz@ehnv.ch

Received 11 July 2025; accepted 14 January 2026; published online 12 February 2026

DOI: https://doi.org/10.20524/aog.2026.1046

This is an open-access journal, and articles are distributed under the terms of the Creative Commons Attribution-NonCommercial-ShareAlike 4.0 License, which allows others to remix, tweak, and build upon the work non-commercially, as long as appropriate credit is given and the new creations are licensed under the identical terms

Introduction

Obstruction of the main pancreatic duct (MPD) is encountered in several pancreatic disorders, most commonly chronic pancreatitis with inflammatory strictures, pancreatic duct stones, pseudocysts or ductal disruption. Less frequent causes include papillary stenosis, anatomical variants such as *pancreas divisum*, and post-surgical anastomotic strictures or fistulas. Persistent MPD obstruction results in ductal dilation and intraductal hypertension, which are key mechanisms underlying abdominal pain, recurrent acute pancreatitis, and progressive pancreatic insufficiency [1-5].

Endoscopic retrograde cholangiopancreatography (ERCP) remains the first-line approach for MPD drainage. However, ERCP fails or cannot be performed in approximately 3-10%

© 2026 Hellenic Society of Gastroenterology

of cases, particularly in patients with altered anatomy or inaccessible papilla [4]. In such situations, endoscopic ultrasound-guided pancreatic duct drainage (EUS-PDD), first described in 2002 [1], enables an anterograde approach to the MPD with creation of a pancreatogastrostomy or pancreatoduodenostomy and stent placement [3]. Compared with surgery, EUS-PDD offers a less invasive alternative with the potential to reduce pain and preserve pancreatic function [7-9].

While short-term outcomes of EUS-PDD have been reported, data on long-term clinical efficacy, stent-related complications and durability of symptom relief remain limited. The present study reports our center's long-term experience with EUS-PDD, focusing on clinical outcomes, adverse events, and the need for reintervention, with the main aim being to evaluate the long-term clinical course of patients after EUS-PDD.

Patients and methods

Type of study and population studied

This retrospective single-center study included all adult patients (≥18 years) who underwent EUS-PDD at the University Hospital of Lausanne, Switzerland, between April 2016 and November 2022. Only patients treated with pancreatogastrostomy or pancreatojejunostomy and followed for at least 12 months were eligible. The study protocol was approved by the local ethics committee (CER-VD, authorization no. 2023-00386).

Demographic data, clinical characteristics, indications for EUS-PDD, procedural details, and follow-up outcomes were extracted from medical records. Baseline data included pain, analgesic use, steatorrhea, pancreatic enzyme replacement therapy, smoking and alcohol consumption, and MPD diameter. All these parameters were evaluated during consultations carried out in the gastroenterology and visceral surgery departments at our hospital.

Endoscopic technique

Endoscopic procedures were performed under general anesthesia or deep propofol sedation. Patients received antibiotic prophylaxis by 1 dose of amoxicillin-clavulanic acid and 1 dose of proton pump inhibitor (40 mg) during the procedure. A linear endoscope with carbon dioxide insufflation was used to identify the MPD. Color Doppler was used to exclude the presence of vascular structures between the digestive tract and the pancreas. Depending on the patient's anatomy, the puncture was performed at gastric or duodenal level using a 19-G needle (Cook Medical), followed by contrast injection, pancreatography and confirmation of the correct position in the MPD. A 0.025-inch guidewire (Boston Scientific) was then inserted through the needle into the duct. Once the needle had been withdrawn through the guidewire, the tract was dilated using a 6 French cystotome. In case of hard pancreatic parenchyma, a 4-mm balloon (Boston Scientific) was used. A straight plastic pancreatic stent (Cook Medical) was inserted, with its proximal end in the gastric or intestinal lumen and the distal part in the MPD or through the papilla in the duodenum. The length of the stents was determined during the procedure, depending on the patient's anatomy. In most patients, a second parallel stent was inserted 4 weeks later to optimize drainage and facilitate fistula maturation.

Endpoints

The primary outcome of this study was to evaluate the long-term clinical success of EUS-PDD. Clinical success was defined by a residual visual analog scale ≤2 and the absence of recurrence of obstructive acute pancreatitis after at least 12 months of follow up after the first drainage procedure. The secondary outcomes were potential infection, acute cholangitis, other causes of acute pancreatitis (e.g., alcoholic), pneumoperitoneum, hemorrhage, prosthesis migration and dysfunction, perforation, intra-abdominal collection, pancreatic fistula, exacerbation of abdominal pain, as well as associated secondary hospitalizations. Pancreatitis of obstructive origin was defined by the recurrence of dilation of the main pancreatic duct after initial normalization, and the lack of acute or massive alcohol intake or other causes identified. The severity of adverse events was defined according to the classification of the American Society of Gastrointestinal Endoscopy [10] which categorizes adverse events into mild, moderate and severe, based on clinical management criteria, the need for hospitalization and the impact on patient outcomes.

Data presentation and statistical analysis

Categorical variables were compared using the chi-square test or Fisher's exact test, as appropriate. Continuous variables were compared using the Wilcoxon rank-sum test. Clinical outcomes are reported with 95% confidence intervals (CI). Exploratory univariate analyses were performed to compare patients with clinical success vs. failure. To assess potential selection bias, baseline characteristics of included and excluded patients were compared. Sensitivity analyses were conducted by excluding patients with ongoing alcohol consumption during follow up. A 2-sided P-value <0.05 was considered statistically significant.

Results

Among 53 patients who underwent EUS-PDD during the study period, 35 met the inclusion criteria (Fig. 1). Baseline characteristics are summarized in Table 1. Mean age was

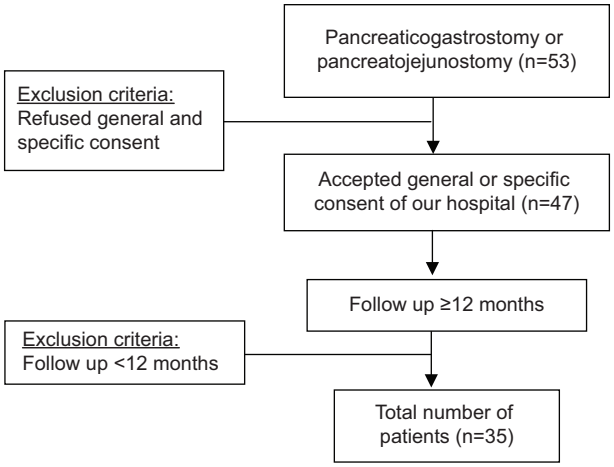

Figure 1 Inclusion criteria

58±11 years, 74% were male, and the mean MPD diameter was 6.6±3.2 mm. Prior to the procedure, 63% reported abdominal pain and 46% required analgesics; 31% reported steatorrhea and 69% were receiving pancreatic enzyme replacement therapy. Regarding substance abuse, 54% of patients were smokers and 26% consumed alcohol on a regular basis.

Chronic pancreatitis was the indication for EUS-PDD in 19 patients (54%), predominantly alcohol-related (79%), either because of pain (n=5), repeated episodes of pancreatitis (n=6) or both (n=6), obstruction by pancreatic duct stone with acute pancreatitis (n=2). Other indications included pancreaticojejunal anastomotic stenosis (26%), MPD rupture (11%), dilation of the MPD post-surgical duodenal suture (2.8%), chronic pancreatic fistula (2.8%) and dissociation of the MPD after a pancreaticojejunal derivation (2.8%). In most patients with pancreaticojejunal anastomosis stenosis, the primary intervention was performed in the setting of neoplastic disease: ampulloma (8.5%), adenocarcinoma of the gastric cardia (2.8%), pancreatic adenocarcinoma (5.7%), and cholangiocarcinoma (2.8%). The mean diameter of the MPD was 6.6±3.2 mm.

Technical success was achieved in all patients (Table 2). Pancreatogastrostomy was performed in 94% and pancreatojejunostomy in 6%. Double stenting was used in 83% of patients. Mean procedure duration was 51±24 minutes, and mean hospital stay was 2±7 days. The median stent size used was 9.0 cm and 7 Fr.

After a mean follow up of 23±19 months, clinical success was achieved in 80% of patients (28/35, 95%CI 64-91%) (Table 3). Adverse events occurred in 17% (95%CI 7-33%), including severe events in 6% and moderate events in 11.4%. One patient with severe adverse events had iatrogenic gastric perforation with suture of the posterior wall of the stomach, and the other patient had a lesion of the left gastric artery, embolized radiologically, and a surgical drainage of an infected hematoma 2 weeks later. Moderate adverse events were a perigastric hematoma endoscopically drained at D4, 1 patient had post-intervention pain requiring morphine, and 1 patient had a radiologically drained infected peripancreatic collection and inter-hepatico-cardial collection at 13 months. The last patient with moderate adverse events had a non-obstructive ascending cholangitis due to *Salmonella* gastroenteritis at 8 months, treated with antibiotics.

Table 1 Baseline characteristics of included patients (n=35)

Characteristics	Number (%)	P-value
Sex		>0.99
Male	26 (74)	
Female	9 (26)	
Age (mean±SD, range)	58±11, 40-81	0.81
BMI (kg/m^2) (mean±SD, range)	22.3±4.9, 14.7-40.1	0.74
Use of analgesics		0.002
Yes	16 (46)	
No	19 (54)	
Pancreatic enzyme replacement therapy		>0.99
Yes	24 (69)	
No	11 (31)	
Tobacco consumption		>0.99
Yes	19 (54)	
No	16 (46)	
Alcohol consumption		0.57
Yes	9 (26)	
No	26 (74)	
Abdominal pain before procedure		0.001
Yes	22 (63)	
No	13 (37)	
Steatorrhea before procedure		>0.99
Yes	11 (31)	
No	24 (69)	
Underlying pathology		0.88
Chronic calcifying pancreatitis	19 (54)	
Other	16 (46)	
Postoperative complications	11	
MPD rupture	4	
Fistula	1	
Etiology of chronic calcifying pancreatitis		
Alcohol	15 (79)	0.79
Other	4 (21)	
Indeterminate	2	
MPD stenosis after surgery	1	
MPD stone	1	
Diameter of main pancreatic duct (mm) (mean±SD, range)	6.6±3.2, 2-17	0.69

SD, standard deviation; BMI, body mass index; MPD, main pancreatic duct

Reintervention was required in 29% of patients (10/35; 95%CI 15-46%), mainly due to stent migration or obstruction. Pancreatitis during follow up occurred in 26% (9/35; 95%CI 13-43%), most often attributed to stent dysfunction. Nine patients (26%) had 1 (n=5) or more episodes (n=4) of pancreatitis during follow up. For these 9 patients, the causes of pancreatitis were clearly attributed to alcohol abuse in 2 patients (6%) and suspected obstructive dysfunction on drainage in 7 patients (20%), even in case of concomitant alcohol consumption in 5 patients (14%). Half of the patients

Table 2 Details regarding the main pancreatic duct drainage

Variable	Number (%)	P-value
Type of anesthesia		0.88
General anesthesia	21 (60)	
Propofol sedation (administered by another gastroenterologist)	14 (40)	
Duration of intervention (min) (mean±SD, range)	51±24, 17-137	0.77
Technical success (defined as stent in main pancreatic duct)		NA
Yes	35 (100)	
No	0	
Type of intervention		>0.99
Pancreaticogastrostomy	33 (94)	
Pancreaticoduodenostomy	2 (6)	
Stent length (cm) (median)	9	0.83
Stent diameter (French)		0.91
5 Fr	3	
7 Fr	31	
8.5 Fr	1	
Double stenting		0.74
Yes	29 (83)	
No	6 (17)	
Second stent length (cm) (median)	7	0.89
Second stent diameter (French) (median)	7	0.92
Hospitalization length (day) (mean±SD, range)	2±7, 1-44	0.81

SD, standard deviation

(48%) presented with stent dysfunction, with either migration alone (56%), obstruction alone (13%) or both (31%). 10 patients (29%) needed reintervention. Three patients had another EUS-PDD, 3 patients had 2 other EUS-PDD, 1 patient had a repositioning of the prosthesis, 1 patient had repositioning and optimization of the prosthesis, and 2 patients needed stent exchange.

Regarding tobacco and alcohol consumption, 51% (n=18) of patients were smokers and 20% (n=7) still regularly consumed alcohol. At last follow up, 83% of patients were pain-free without analgesics, 86% were receiving pancreatic enzyme replacement therapy, and mean weight gain was 2±8 kg. Two deaths occurred during follow up, unrelated to pancreatic disease or EUS-PDD.

Discussion

In this single-center retrospective study with a mean follow up of 23±19 months, endoscopic ultrasound-guided pancreatic duct drainage (EUS-PDD) demonstrated durable clinical efficacy and an acceptable safety profile in selected patients with MPD obstruction after failure or infeasibility of ERCP. Clinical success was achieved in 80% of patients (95%CI

Table 3 Outcomes assessed in the follow-up period

Outcomes	n (%)	95%CI	P- value
Clinical success (defined as no recurrence of pancreatitis and VAS ≤ 2 without analgesics)		64-91	NA
Yes	28 (80)		
No	7 (20)		
Adverse events		7-33	0.41
Yes	6 (17)		
No	29 (83)		
Severity of adverse events		1-20	0.62
Moderate	4 (11)		
Severe	2 (5.7)		
Type of adverse events (n=6)			
Perigastric hematoma	1 (2.8)		
Post-intervention pain requiring morphine	1 (2.8)		
Infected peripancreatic collection and inter-hepatico-cardial collection	1 (2.8)		
Non-obstructive ascending cholangitis	1 (2.8)		
Iatrogenic gastric perforation	1 (2.8)		
Lesion of the left gastric artery	1 (2.8)		
Need for reintervention		15-46	0.03
Yes	10 (29)		
No	25 (71)		
Another PGS	3		
Two other PGS	3		
Repositioning of the prosthesis	1		
Repositioning and optimization of prosthesis	1		
Prosthesis change	2		
Need for surgery			0.18
No	33 (94)		
Yes	2 (6)		
Duration of follow up (months) (mean±SD, range)	23±19, 12-83		
Pancreatitis during follow up		13-43	0.002
No	26 (74)		
Yes	9 (26)		
Alcoholic	1		
Prosthesis obstruction	6		
Gallstone	1		
Undetermined	1		
Pain during follow up		67-93	<0.001
No	29 (83)		
Yes	6 (17)		
Steatorrhea during follow up			>0.99
No	25 (71)		
Yes	10 (29)		
Pancreatic enzyme replacement therapy during follow up			>0.99
Yes	30 (86)		
No	5 (14)		

(Contd...)

Table 3 *(Continued)*

Outcomes	n (%)	95%CI	P- value
Tobacco consumption during follow up Yes No	18 (51) 17 (49)		>0.99
Alcohol consumption during follow up No Yes	28 (80) 7 (20)		0.057
Weight at end of follow up (kg) (mean±SD, range)	68±17, 42-127		
Delta weight at the end of follow up (kg) (mean±SD, range)	2±8, -13-36		0.27
Death during follow up No Yes	33 (94) 2 (6)		0.49
Cause of death Unknown	2		

CI, confidence interval; VAS, Visual Analog Scale for pain; PGS, plastic gastroduodenal stent; SD, standard deviation

64-91%), a result that aligns with previously reported long-term success rates ranging from 50-100% in heterogeneous cohorts [1,11-23].

A distinctive feature of our study is the exclusive inclusion of patients treated with anterograde drainage through pancreatogastrostomy or pancreatojejunostomy, whereas most published series combine anterograde EUS-PDD, rendezvous and standard ERCP approaches. This methodological homogeneity strengthens the interpretation of our long-term outcomes and supports the role of anterograde EUS-PDD as a definitive drainage strategy, rather than a bridge to retrograde access. Importantly, baseline characteristics and procedural variables were not significantly different between the clinical success and failure groups, suggesting good comparability of the populations. In contrast, follow-up outcomes showed significant associations between clinical failure and pancreatitis (P=0.002), pain (P<0.001) and need for reintervention (P=0.03). These findings support the internal consistency of our definition of clinical success and failure and reinforce the clinical relevance of the outcome measures used.

Although adverse events occurred in 17% of patients, severe complications were uncommon, and were mainly observed during the early learning phase. Most complications were managed conservatively or endoscopically, underscoring the importance of expertise and careful patient selection. There are a numerous technical challenges associated with this procedure [2,8,24,25]. Tyberg *et al* looked at the learning curve for EUS-PDD in a study of 56 patients and a single operator; they described a reduction in the duration of the procedure from the 27th case, and proficiency from the 40th procedure [26]. Given that procedures in our cohort were performed by an experienced endoscopist, a further reduction in complication rates could reasonably be expected as institutional experience continues to increase.

Stent-related dysfunction was frequently observed during follow up, affecting nearly half of the patients, a rate comparable to those in studies with similar follow-up durations [11,13]. Importantly, more than half of the stent migrations in our cohort were clinically silent and did not require intervention. Consequently, we deliberately chose not to classify asymptomatic stent dysfunction as an adverse event, and we adopted a conservative management strategy without routine stent exchange in asymptomatic patients. This approach reduced the number of repeat procedures and associated procedural risks, while maintaining satisfactory clinical outcomes.

Pancreatitis during follow up occurred in 26% of patients (95%CI 13-43%), predominantly related to stent dysfunction, although alcohol consumption remained a contributing factor in a minority of cases. Sensitivity analyses, excluding patients with ongoing alcohol intake, yielded similar clinical success rates, reinforcing the robustness of our primary outcome. These findings highlight the multifactorial nature of post-procedural pancreatitis and emphasize the importance of addressing modifiable risk factors, particularly alcohol cessation, in patients with chronic pancreatitis.

From a technical perspective, our current practice is in favor of the use of 7-Fr stents, which allow endoscopic retrieval in case of intraductal migration. The early use of 5-Fr stents was associated with a higher risk of distal migration, including 1 challenging case of intraductal stent retention. The use of longer stents and systematic double stenting—performed 4 weeks after the initial procedure to allow fistula maturation—appears to enhance drainage, reduce migration risk and maintain fistula patency. In pancreatogastrostomy this interval may be shortened, whereas in pancreatojejunostomy a longer delay remains necessary because of increased intestinal motility and migration risk.

Comparative data between endoscopic and surgical management of chronic pancreatitis favor surgery in terms of long-term pain control [27,28]. However, these randomized trials evaluated retrograde ERCP-based strategies with scheduled stent exchanges and delayed endoscopic intervention, while anterograde EUS-PDD was not assessed. In contrast, patients in our cohort underwent definitive anterograde drainage with long-term stent placement, and none required surgery for persistent symptoms. These differences suggest that EUS-PDD may offer a durable alternative to surgery in appropriately selected patients, although direct comparative studies are still lacking. A study comparing surgery and anterograde EUS-PDD would be interesting.

Several limitations should be acknowledged. The retrospective design introduces potential selection and information biases, and the single-center setting limits generalizability. Pain assessment relied partly on the visual analog scale, a subjective measure that may be influenced by individual perception. Nevertheless, the inclusion of objective outcomes, such as recurrence of obstructive pancreatitis, strengthens the validity of our findings. The heterogeneity of underlying indications reflects real-world practice but complicates subgroup analyses. Larger, prospective, multicenter studies are needed to confirm these results, refine patient selection, and optimize stent strategies.

In conclusion, EUS-PDD is a safe and effective long-term therapeutic option for selected patients with MPD obstruction when ERCP is not feasible. With an 80% clinical success rate over a mean follow up of nearly 2 years, EUS-PDD provides durable symptom control with acceptable morbidity. Conservative management of asymptomatic stent dysfunction appears justified and may reduce the need for repeat interventions. Prospective comparative studies are warranted, to further define the role of anterograde EUS-PDD relative to surgical drainage in chronic pancreatitis and other causes of MPD obstruction.

Summary Box

What is already known:

- Endoscopic retrograde cholangiopancreatography is the first-line technique for main pancreatic duct drainage, but 3-10% of patients cannot be treated because of inaccessible papilla or altered anatomy
- Endoscopic ultrasound-guided pancreatic duct drainage (EUS-PDD) is the most effective alternative, offering pain relief and preservation of pancreatic function with lower morbidity than surgery
- Long-term clinical outcomes after EUS-PDD remain poorly documented, particularly regarding symptom improvement and late complications

What the new findings are:

- This study provides one of the longest follow-ups reported (mean 23 months) in a homogeneous cohort treated exclusively with pancreaticogastrostomy or pancreatojejunostomy, avoiding the heterogeneity of mixed anterograde/rendezvous populations
- Although complications occurred in 17% of cases, severe adverse events were rare, and most events arose early in the learning curve, supporting a reduction in risk with operator experience
- High long-term clinical success (80%) was observed despite frequent stent dysfunction, with many patients remaining asymptomatic after migration, suggesting durable fistula formation and supporting a minimally interventionist stent management strategy

References

1. François E, Kahaleh M, Giovannini M, Matos C, Devière J. EUS-guided pancreaticogastrostomy. *Gastrointest Endosc* 2002; **56**:128-133.
2. Will U, Reichel A, Fueldner F, Meyer F. Endoscopic ultrasonography-guided drainage for patients with symptomatic obstruction and enlargement of the pancreatic duct. *World J Gastroenterol* 2015;**21**:13140-13151.
3. Hayat U, Freeman ML, Trikudanathan G, Azeem N, Amateau SK, Mallery J. Endoscopic ultrasound-guided pancreatic duct intervention and pancreaticogastrostomy using a novel cross-platform technique with small-caliber devices. *Endosc Int Open* 2020;**8**:E196-E202.
4. Sledzianowski JF, Muscari F, Suc B, Fourtanier G. Recurrent pancreatitis after pancreaticoduodenectomy: reoperation for stenosis of the pancreaticojejunostomy. *Ann Chir* 2004;**129**:37-40.
5. Vitale GC, Cothron K, Vitale EA, et al. Role of pancreatic duct stenting in the treatment of chronic pancreatitis. *Surg Endosc* 2004;**18**:1431-1434.
6. Widmer J, Sharaiha RZ, Kahaleh M. Endoscopic ultrasonography-guided drainage of the pancreatic duct. *Gastrointest Endosc Clin N Am* 2013;**23**:847-861.
7. Krafft MR, Croglio MP, James TW, Baron TH, Nasr JY. Endoscopic endgame for obstructive pancreatopathy: outcomes of anterograde EUS-guided pancreatic duct drainage. *Gastrointest Endosc* 2020;**92**:1055-1066.
8. Fujii-Lau LL, Levy MJ. Endoscopic ultrasound-guided pancreatic duct drainage. *J Hepatobiliary Pancreat Sci* 2015;**22**:51-57.
9. Tyberg A, Sharaiha RZ, Kedia P, et al. EUS-guided pancreatic drainage for pancreatic strictures after failed ERCP: a multicenter international collaborative study. *Gastrointest Endosc* 2017;**85**:164-169.
10. Cotton PB, Eisen GM, Aabakken L, et al. A lexicon for endoscopic adverse events: report of an ASGE workshop. *Gastrointest Endosc* 2010;71:**446**-454.
11. Tessier G, Bories E, Arvanitakis M, et al. EUS-guided pancreatogastrostomy and pancreatobulbostomy for the treatment of pain in patients with pancreatic ductal dilatation inaccessible for transpapillary endoscopic therapy. *Gastrointest Endosc* 2007;**65**:233-241.
12. Kahaleh M, Hernandez AJ, Tokar J, Adams RB, Shami VM, Yeaton P. EUS-guided pancreaticogastrostomy: analysis of its efficacy to drain inaccessible pancreatic ducts. *Gastrointest Endosc* 2007;**65**:224-230.
13. Ergun M, Aouattah T, Gillain C, Gigot JF, Hubert C, Deprez PH. Endoscopic ultrasound-guided transluminal drainage of pancreatic duct obstruction: long-term outcome. *Endoscopy* 2011;**43**:518-525.
14. Brauer BC, Chen YK, Fukami N, Shah RJ. Single-operator EUS-guided cholangiopancreatography for difficult pancreaticobiliary access. *Gastrointest Endosc* 2009;**70**:471-479.
15. Vila JJ, Pérez-Miranda M, Vazquez-Sequeiros E, et al. Initial experience with EUS-guided cholangiopancreatography for biliary and pancreatic duct drainage: a Spanish national survey. *Gastrointest Endosc* 2012;**76**:1133-1141.
16. Mallery S, Matlock J, Freeman ML. EUS-guided rendezvous drainage of obstructed biliary and pancreatic ducts: report of 6 cases. *Gastrointest Endosc* 2004;**59**:100-107.
17. Fujii LL, Topazian MD, Abu Dayyeh BK, et al. EUS-guided pancreatic duct intervention: outcomes of a single tertiary-care referral center experience. *Gastrointest Endosc* 2013;**78**:854-864.
18. Shah JN, Marson F, Weilert F, et al. Single-operator, single-session EUS-guided anterograde cholangiopancreatography in failed ERCP or inaccessible papilla. *Gastrointest Endosc* 2012;**75**:56-64.
19. Kurihara T, Itoi T, Sofuni A, Itokawa F, Moriyasu F. Endoscopic ultrasonography-guided pancreatic duct drainage after failed ERCP in patients with malignant and benign pancreatic duct obstructions. *Dig Endosc* 2013;**25**:109-116.
20. Kinney TP, Li R, Gupta K, et al. Therapeutic pancreatic endoscopy after Whipple resection requires rendezvous access. *Endoscopy* 2009;**41**:898-901.
21. Barkay O, Sherman S, McHenry L, et al. Therapeutic EUS-assisted

endoscopic retrograde pancreatography after failed pancreatic duct cannulation at ERCP. *Gastrointest Endosc* 2010;**71**:1166-1173.
22. Will U, Fueldner F, Goldmann B, Mueller AK, Wanzar I, Meyer F. Successful transgastric pancreaticography and endoscopic ultrasound-guided drainage of a disconnected pancreatic tail syndrome. *Therap Adv Gastroenterol* 2011;**4**:213-218.
23. Will U, Füldner F, Reichel A, Meyer F. EUS-guided drainage of the pancreatic duct (EUPD): promising therapeutic alternative to surgical intervention in case of symptomatic retention of the pancreatic duct and unsuccessful ERP. *Zentralbl Chir* 2014;**139**:318-325.
24. Devière J. EUS-guided pancreatic duct drainage: a rare indication in need of prospective evidence. *Gastrointest Endosc* 2017;**85**:178-180.
25. Itoi T, Yasuda I, Kurihara T, Itokawa F, Kasuya K. Technique of endoscopic ultrasonography-guided pancreatic duct intervention. *J Hepatobiliary Pancreat Sci* 2014;**21**:E4-E9.
26. Tyberg A, Bodiwala V, Kedia P, et al. EUS-guided pancreatic drainage: a steep learning curve. *Endosc Ultrasound* 2020;**9**:175-179.
27. Issa Y, Kempeneers MA, Bruno MJ, et al; Dutch Pancreatitis Study Group. Effect of early surgery vs endoscopy-first approach on pain in patients with chronic pancreatitis: the ESCAPE randomized clinical trial. *JAMA* 2020;**323**:237-247.
28. van Veldhuisen CL, Kempeneers MA, de Rijk FEM, et al; Dutch Pancreatitis Study Group. Long-term outcomes of early surgery vs endoscopy first in chronic pancreatitis: follow-up analysis of the ESCAPE randomized clinical trial. *JAMA Surg* 2025;**160**:126-133.