Annals of Gastroenterology (2026) **39,** 1-8

Endoscopic submucosal dissection and submucosal tunneling endoscopic resection of gastric subepithelial lesions originating from the muscle layer: a multicenter retrospective study

Stavros Dimitriadis[a], Stamatina Vogli[b], Gianluca Adrisani[c], George Tribonias[d], Domenico Galasso[e], Shaimaa Elkholy[f], Shivam Khare[g], Juliette Leroux[h], Harold Eduardo Benites Goñi[i], Stefan Seewald[j], Khanh Do-Cong Pham[k], Pedro Rosón Rodriguez[l], Ahmad Madkour[m], Sandro Sferrazza[n], Hany Shehab[o], Sridhar Sundaram[p], Mihai Ciocîrlan[q], Amr Fouly[r], Luis Marín Calderón[s], Paulo Bardalez Cruz[i], Hany Hagag[f], Mohamed El-Sherbiny[f], Kareem Essam[f], Rossella Maresca[s], Jijo Varghese[t], Federico Barbaro[s], Cristiano Spada[s], Matteo Marasco[e], Francesco Maria Di Matteo[c], Maria Zachou[u], Georgios Mavrogenis[u]

Private Practice, Thessaloniki, Greece; Metaxa Oncologic Hospital of Piraeus, Piraeus, Greece; Fondazione Policlinico Universitario Campus Bio-Medico, Rome, Italy; Red Cross Hospital, Athens, Greece; Hôpital Riviera-Chablais, Vaud-Valais, Switzerland; Cairo University, Cairo, Egypt; Sir Ganga Ram Hospital, New Delhi, India; Hôpital Cochin, Paris, France; Universidad San Ignacio de Loyola, Lima, Peru; Clinic Hirslanden, Zurich, Switzerland; Haukeland University Hospital, Bergen, Norway; Hospital Regional Universitario de Málaga, Málaga, Spain; Helwan University, Cairo, Egypt; ARNAS Civico Di Cristina Benfratelli, Palermo, Italy; Integrated Clinical & Research Center for Intestinal Disorders (ICRID), Cairo, Egypt; Tata Memorial Hospital, Homi Bhabha National Institute, Mumbai, India; "Carol Davila" University of Medicine and Pharmacy, Bucharest, Romania; Hospital Nacional Edgardo Rebagliati Martins, Lima, Peru; Fondazione Policlinico Universitario Agostino Gemelli IRCCS, Università Cattolica del Sacro Cuore – Centre for Endoscopic Research Therapeutics and Training (CERTT), Rome, Italy; NS Hospital, Kollam, Kerala, India; Mediterraneo Hospital, Athens, Greece

Abstract

Background Gastric subepithelial lesions (SELs) from the *muscularis propria* are usually managed surgically or with surveillance. Advances in endoscopic techniques now permit safe *en bloc* resection, even for lesions with extraluminal growth, but data from outside East Asia are scarce.

Methods We performed a multicenter retrospective study across 18 centers in Europe, the Middle East, South America and South Asia, including patients with gastric SELs from the *muscularis propria* resected by endoscopic submucosal dissection (ESD) or submucosal tunneling endoscopic resection (STER) between 2017 and 2024. Outcomes included *en bloc* resection, safety, complications, and recurrence.

Results Eighty-two patients (62.2% women; median age 59 years) were included. Median lesion size was 2 cm (range 0.6-8). Lesions were located in the cardia (18.3%), fundus (18.3%), body (40.2%), and antrum (23.2%). Histology showed gastrointestinal stromal tumors in 78.0%, leiomyomas in 19.5%, and schwannomas in 2.5%. Most were endoluminal (80.5%), 19.5% were extraluminal, and 7.3% extended beyond the serosa. ESD was performed in 65.9% and STER in 34.1%. Median procedure time was 120 min. Deliberate perforation was performed in 31.7%, while 92.3% were managed endoscopically. *En bloc* resection was achieved in 96.3%, with defect closure in 90.2%. Complications occurred in 7%, with no mortality. Local relapse occurred in 2.5% after a median 9-month follow up. One-third of procedures took place in non-academic centers.

Conclusions ESD and STER are safe and effective alternatives to surgery or surveillance for gastric SELs from the *muscularis propria*, including lesions with extraluminal growth. Long-term, comparative studies alongside laparoscopic surgery are warranted.

Keywords Subepithelial lesion, endoscopic submucosal dissection, submucosal tunneling endoscopic resection, gastrointestinal stromal tumor, submucosal tumor

Ann Gastroenterol 2026; 39 (2):1-8

Conflict of Interest: None

Correspondence to: Stavros Dimitriadis, MD, Private Gastroenterology Practice, Egnatia 106, 54622, Thessaloniki, Greece, e-mail: dimitriadis.stavros@yahoo.com

Received 24 August 2025; accepted 24 November 2025; published online 26 January 2026

DOI: https://doi.org/10.20524/aog.2026.1035

This is an open access journal, and articles are distributed under the terms of the Creative Commons Attribution-NonCommercial-ShareAlike 4.0 License, which allows others to remix, tweak, and build upon the work non-commercially, as long as appropriate credit is given and the new creations are licensed under the identical terms

© 2026 Hellenic Society of Gastroenterology

Introduction

Subepithelial lesions (SELs) in the gastrointestinal tract are usually incidental findings during upper gastrointestinal (GI) endoscopy. The incidence is about 1 in every 300 endoscopies, and 2/3 are located in the stomach. SELs include a large spectrum of lesions with varied potential for malignancy, ranging from completely benign pathologies, such as ectopic pancreatic rest, to potentially malignant lesions, such as neuroendocrine tumors and GI stromal tumors (GISTs) [1-4].

Among gastric SELs, GISTs are the most commonly encountered, followed by pancreatic rests, lipomas, leiomyomas and neuroendocrine tumors. These lesions require further investigation to determine their nature and malignant potential [5].

The diagnostic workup for gastric SELs includes computed tomography (CT), magnetic resonance imaging and endoscopic ultrasound (EUS), often complemented by fine-needle aspiration (EUS-FNA) or biopsy [5-7]. However, despite these modalities, obtaining a definitive diagnosis without tissue resection remains challenging. Even with EUS-FNA or biopsy, histopathological confirmation may be inconclusive, particularly for lesions originating from the *muscularis propria* layer [8].

Endoscopic surveillance at regular intervals for SELs smaller than 2 cm is suggested by the existing guidelines, while surgical resection is recommended for lesions exceeding this size [1,5,6]. However, emerging evidence suggests that small SELs, more specifically GISTs, could be potentially malignant despite their size. Furthermore, prolonged surveillance has its own drawbacks, including patient anxiety, loss to follow up, and higher healthcare costs due to repeated examinations [9]. The most recent recommendation from the European Society for Medical Oncology (ESMO) suggests the resection of histologically confirmed GISTs, even when they are less than 2 cm [10].

Until now, surgical excision has been considered the gold standard for the treatment of gastric GISTs [4,6]. However, advancements in endoscopic techniques and accessories have significantly expanded the feasibility of *en bloc* resection with effective defect closure [11]. Endoscopic resection offers distinct advantages, particularly for lesions in anatomically challenging locations, such as the esophagogastric junction or cardia, where laparoscopic access may be complex [12]. In addition, the endoscopic resection preserves the anatomy of the stomach, thus sparing the risk of postoperative anatomical deformity, gastroparesis or dyspepsia often related to surgical wedge resections. In particular, knife-assisted resection (KAR) enucleates the tumor and, if necessary, intentional perforation and dissection beyond the serosa are applied. In most publications the term ESD is used for KARs (although dissection may expand beyond the submucosal layer to the muscle layer or even the serosa), while the term STER is reserved for endoscopic resections of SELs through a submucosal tunnel that is closed at the end of the procedure. The choice between these techniques depends on the location, the size and the need for dissection beyond the serosa. Most frequent complications related to either ESD or STER include difficulty to close the wall defect, intraprocedural or late bleeding, peritonitis, and gas-related effects [13]. However, most of these adverse events may be managed conservatively. In addition, in cases with preoperative uncertainty about the need for surgical closure of the defect, the endoscopic procedure is undertaken inside the surgical theater, so that cooperative laparoscopic endoscopic surgery can be applied if needed [14]. The aforementioned techniques demand advanced endoscopic skills, high-end endoscopic equipment, surgical backup, and copious training in reference centers that perform peroral endoscopic myotomy (POEM) and ESD. Moreover, they are mainly applied in Asia, while only limited experience has been published from other parts of the world [15-17].

In this retrospective study, we aimed to evaluate the feasibility, efficacy and safety of endoscopic resection for gastric SELs arising from the *muscularis propria* layer, mainly in countries outside of East Asia.

Patients and methods

Patients and data collection

Advanced academic and non-academic endoscopic centers outside of East Asia known for their clinical work on ESD, STER and POEM were asked to share their data on the resection of gastric submucosal tumors by means of ESD

[a]Private Practice, Thessaloniki, Greece (Stavros Dimitriadis); [b]Department of Gastroenterology, Metaxa Oncologic Hospital of Piraeus, Piraeus, Greece (Stamatina Vogli); [c]Digestive Endoscopy Unit, Fondazione Policlinico Universitario Campus Bio-Medico, Rome, Italy (Gianluca Adrisani, Francesco Maria Di Matteo); [d]Red Cross Hospital, Athens, Greece (George Tribonias); [e]Hôpital Riviera-Chablais, Vaud-Valais, Switzerland (Domenico Galasso, Matteo Marasco); [f]Gastroenterology Division, Internal Medicine Department, Faculty of Medicine, Cairo University, Cairo, Egypt (Shaimaa Elkholy, Hany Hagag, Mohamed El-Sherbiny, Kareem Essam); [g]Department of Gastroenterology, Sir Ganga Ram Hospital, New Delhi, India (Shivam Khare[g]); [h]Department of Gastroenterology, Hôpital Cochin, Paris, France (Juliette Leroux); [i]Hospital Nacional Edgardo Rebagliati Martins; Universidad Peruana Cayetano Heredia; Universidad San Ignacio de Loyola, Lima, Peru (Harold Eduardo Benites Goñi, Paulo Bardalez Cruz[i]); [j]GastroZentrum, Clinic Hirslanden, Zurich, Switzerland (Stefan Seewald); [k]Department of Medicine, Haukeland University Hospital, Bergen, Norway (Khanh Do-Cong Pham); [l]Hospital Vithas Xanit International; Hospital Regional Universitario de Málaga, Málaga, Spain (Pedro Rosón Rodriguez); [m]Faculty of Medicine, Helwan University, Cairo, Egypt (Ahmad Madkour); [n]Gastroenterology and Endoscopy Unit, ARNAS Civico Di Cristina Benfratelli, Palermo, Italy (Sandro Sferrazza); [o]Integrated Clinical & Research Center for Intestinal Disorders (ICRID), Cairo, Egypt (Hany Shehab); [p]Department of Digestive Diseases and Clinical Nutrition, Tata Memorial Hospital, Homi Bhabha National Institute, Mumbai, India (Sridhar Sundaram); [q]"Carol Davila" University of Medicine and Pharmacy, Bucharest, Romania (Mihai Ciocîrlan); [r]Hospital Nacional Edgardo Rebagliati Martins, Lima, Peru (Amr Fouly); [s]Digestive Endoscopy Unit, Fondazione Policlinico Universitario Agostino Gemelli IRCCS, Università Cattolica del Sacro Cuore – Centre for Endoscopic Research Therapeutics and Training (CERTT), Rome, Italy (Luis Marín Calderón, Rossella Maresca, Frederico Barbaro, Cristiano Spada); [t]NS Hospital, Kollam, Kerala, India (Jijo Varghese); [u]Third Space Endoscopy Unit, Department of Gastroenterology, Mediterraneo Hospital, Athens, Greece (Maria Zachou, Georgios Mavrogenis)

and/or STER, for procedures performed between February 2017 and September 2024. Participating centers were located in the following countries: Egypt, France, Greece, India, Italy, Norway, Peru, Romania, Spain, and Switzerland. The inclusion criteria were: (1) patients aged 18 years or older; (2) gastric SEL originating from the muscle layer determined by EUS or CT scan; (3) no distant metastases; (3) ESD or STER treatment; and (4) patient informed consent for the endoscopic treatment. Exclusion criteria included: (1) no signed informed consent for the endoscopic treatment; and (2) endoscopic treatments other than ESD and STER.

All the endoscopists who performed the ESD and STER procedures were experienced, with a yearly case load of at least 50 ESD/POEM cases per year. The patient's demographic characteristics, tumor location and size, procedural type, duration and complications, and finally the wall defect closure type (if needed) were recorded. The ethical approval was obtained initially by the Mediterraneo Hospital in Athens and also by the local ethic committees of the participating centers, when needed. The study adhered to the STrengthening the Reporting of OBservational studies in Epidemiology (STROBE) guidelines [18].

Technical details

All procedures were performed under general anesthesia using a gastroscope fitted with a transparent hood under CO_2 insufflation. Depending on the risk of perforation and the availability of laparoscopic endoscopic cooperative surgery (LECS), the operation took place in the endoscopy unit or inside the operating theater. A tip-cutting knife was used in the majority of cases; the type varied among centers (Flush Knife, FujiFilm Tokyo; Dual Knife Olympus, Tokyo; Hybrid Knife I type, ERBE, Tubingen). In case of bleeding, visible vessels were coagulated with the tip of the knife, or with a hemostatic forceps. Various techniques were used for defect closure, such as clip-and-loop closure, conventional clip closure, over-the-scope clip closure, or endoscopic suturing. In cases of STER, the mucosal window was closed in all cases, while in cases of ESD it was left at the discretion of the endoscopist, based on the risk of late perforation or of bleeding. Representative examples of endoscopic resection of gastric SELs originating from the muscle layer are shown in Fig. 1. In our study, we defined the resection technique as KAR when intentional serosal dissection was performed, and as ESD when the serosa remained intact. On the other hand, the term endoscopic full-thickness resection is broad and encompasses various endoscopic techniques—such as KAR, full-thickness resection device and STER—which may lead to inconsistencies in communication among endoscopists. Fig. 2 shows our endoscopic approach based on lesion size, depth of invasion, and site of origin.

Study outcomes

The primary outcomes of this study were the *en bloc* resection rate, endoscopic procedure-related adverse events (AEs), and recurrence rate. *En bloc* resection rate was defined as the number of lesions that were macroscopically complete and removed intact, as described by the endoscopist. AEs were classified according to the AGREE (Adverse events in GastRointEstinal Endoscopy) system, as proposed by Nass *et al* [19]. Local recurrence rate and mean follow-up duration were also documented. Secondary outcomes included procedure time, the need for surgical intervention or adjuvant therapy after endoscopic resection (chemotherapy or immunotherapy), as well as hospital stay duration.

Statistical analysis

For descriptive statistics, the mean ± standard deviation was used for normally distributed variables, while the median was reported for skewed distributions. Categorical variables were presented as counts (n) and percentages. Where appropriate, Student's *t*-test, ANOVA, and the chi-square (χ^2) test were applied. A P-value <0.05 was considered statistically significant. All statistical analyses were conducted using STATA software (version 17.0, StataCorp, College Station, TX, USA).

Results

A total of 82 patients (38% men) were included in the study, recruited from 18 centers. Clinical and demographic characteristics are summarized in Table 1. The patients' median age was 58.5 years, and the median lesion size was 20 mm (range 6-80 mm). The lesions were located in the cardia, fundus, body and antrum in 18%, 18%, 40% and 23% of the cases, respectively. Among these 4 gastric regions, the median tumor size did not differ significantly and was 21 mm in the cardia, 18 mm in the fundus, 20 mm in the body, and 21 mm in the antrum. Most tumors were endoluminal, 16 cases presented extraluminal growth, and 6 extended beyond the serosa.

Indications for endoscopic resection included a confirmed diagnosis of GIST (38%), increasing lesion size with uncertain histology (25%), symptomatic presentation (3%), patient preference for removal over surveillance (14%), and a combination of these factors (20%).

ESD was performed in 54 cases (66%) and STER in 28 (34%), with a median procedure time of 120 min (range 24-305). In 26 cases a deliberate perforation was performed, 24 of which were managed endoscopically, while 2 cases were converted to surgical intervention (LECS) after failure to close the defect. Histopathological examination diagnosed GISTs in 78% of cases, while leiomyomas and schwannomas were identified in 20% and 2%, respectively. Seven GISTs of 64 (11%) had a high mitotic rate, whereas 57 (89%) showed a low mitotic rate. Table 2 presents an overview of the procedure details by technique (ESD or STER).

En bloc resection was successfully achieved in 79 of 82 cases (96%). Moderate to severe complications, classified as AGREE Grade II, III and IV—including perforation, bleeding,

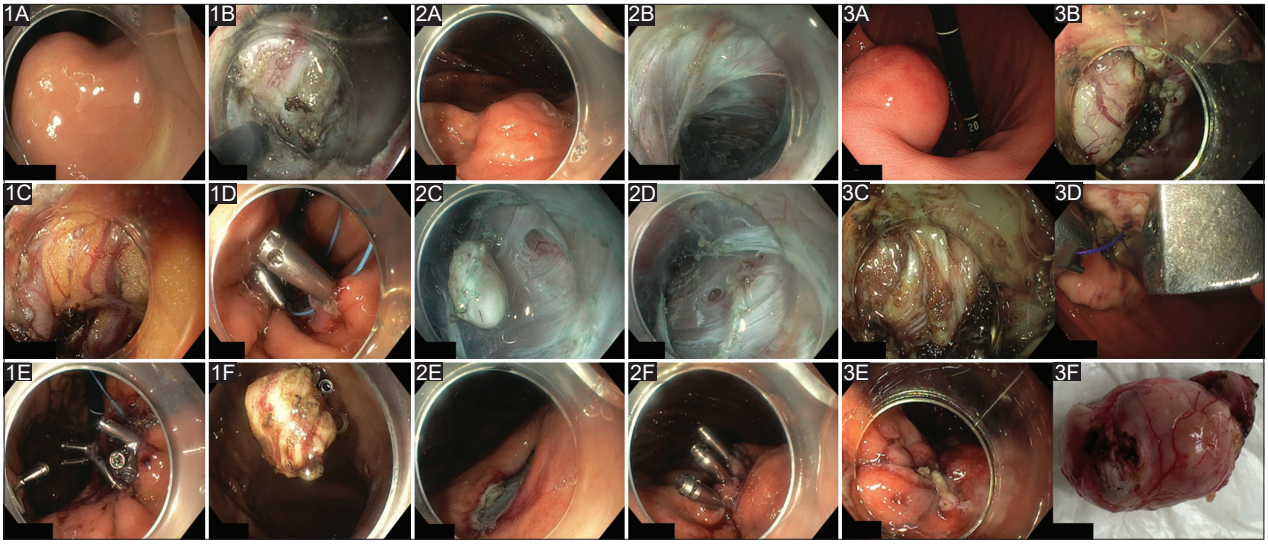

Figure 1 (1A) Knife assisted resection of a gastric GIST of the posterior wall of the gastric body. (1B) The tumor invades the *muscularis propria*. (1C) Exposure of the peritoneal fat. (1D, E) Clip and band endoloop closure. (1F) Final specimen. 2 Demonstration of STER. (2A) A leiomyoma of the posterior wall of the gastric body. (2B) Tunneling. (2C) Enucleation of the tumor. (2D) Resection of the tumor through the tunnel. (2E, F) Mucosal window before and after closure. (3A) Knife assisted subserosal resection of a GIST of the gastric angulus. (3B) Exposure of the tumor. (3C) Subserosal dissection. (3D, E) Closure of the defect with a suturing device. (3F) Final specimen
GIST, gastrointestinal stromal tumors; STER, submucosal tunneling endoscopic resection

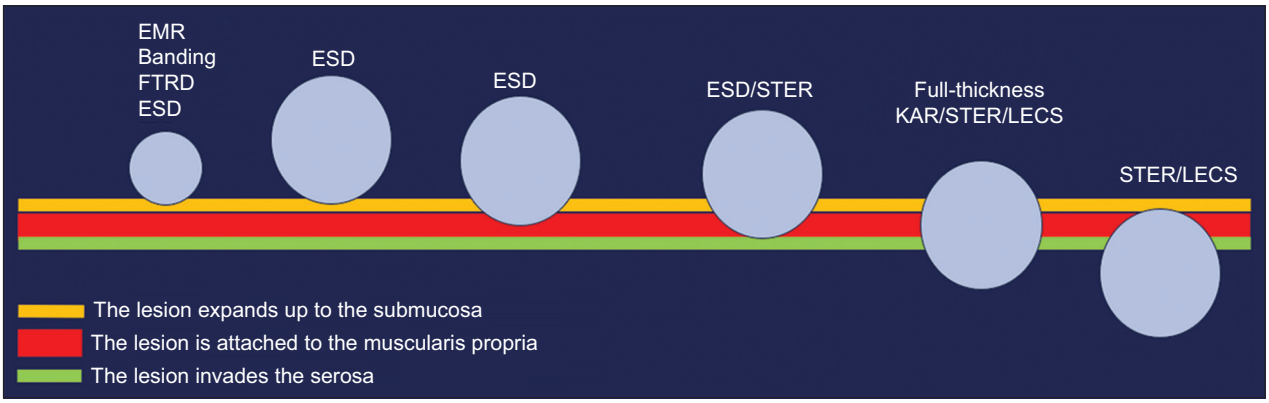

Figure 2 Endoscopic options for resection of epithelial lesions and SEL depending on size (<1.5 cm vs. >1.5 cm) and depth of invasion
SEL, subepithelial lesions; FTRD, full-thickness resection device; EMR, endoscopic mucosal resection; ESD, endoscopic submucosal dissection; KAR, knife-assisted resection; LECS, laparoscopic endoscopic cooperative surgery

conversion to surgery and peritonitis—occurred in 6 cases (7%). The majority of adverse events were mild, consisting of pneumoperitoneum (9 cases) and abdominal pain, which was managed conservatively. Two cases were converted into LECS, as mentioned above. One patient experienced perforation leading to peritonitis and prolonged hospitalization; however, no mortality was reported. Local recurrence occurred in 2 cases after a mean follow up of 12 months (range 3-60 months). Primary and secondary outcomes by technique are shown in Table 3.

Procedure details and outcomes

ESD was performed in 54 patients, with a mean tumor size of 27 mm, while STER was used in 28 tumors, with a significantly smaller mean size of 19 mm (P=0.0026). The mean procedure duration was 126 min for ESD and 105 min for STER (P=0.06). Serosal dissection was performed in 17 ESD cases and 9 STER cases. Endoscopic closure of the defect was required in 52 of 54 tumors resected via ESD and in 22 of 28 tumors resected via STER, with the closure methods used detailed in Table 2.

The *en bloc* resection rate did not differ statistically between the 2 techniques, being achieved in 98% of ESD cases and 93% of STER cases (P=0.226). All instances of moderate and severe complications (AGREE Grade III and IV) occurred in the ESD group. In 2 cases, wall defect closure was unsuccessful, necessitating surgical intervention, while in 1 case, perforation and peritonitis led to prolonged hospitalization (21 days).

Table 1 Clinical and demographic characteristics of 82 patients undergoing endoscopic resection of gastric subepithelial lesions across 18 centers

Variable	N (%/range)
Type of center, university-based	48 (58.5%)
Age (years), median (range)	58.5 (20-81)
Male sex	
Location	31 (37.8%)
Cardia	15 (18.3%)
Fundus	15 (18.3%)
Body	33 (40.2%)
Antrum	19 (23.2%)
Size (mm), median	20.0 (6-80)
Extraluminal and/or beyond the serosa growth	22 (26.8%)
Muscularis propria on EUS	57 (69.5%)
Indication	
GIST on histology	31 (37.8%)
Uncertain diagnosis/*muscularis propria* origin	21 (25.6%)
Obstruction or bleeding	3 (3.7%)
Patient's preference	11 (13.4%)
Two or more of the above reasons	16 (19.5%)
Histology	
GIST	64 (78.0%)
Leiomyoma	16 (19.5%)
Schwannoma	2 (2.5%)

EUS, endoscopic ultrasound; GIST, gastrointestinal stromal tumors

Table 2 Procedure-related details by endoscopic technique (ESD vs. STER)

Variable, n (%)	ESD (n=54)	STER (n=28)	P-value
Size (mm), mean±SD	26.7±15.1	19.0±7.2	0.0026
Serosa dissection	17 (31.5%)	9 (32.1%)	0.951
Procedure location			0.378
Endoscopy room	38 (70.4%)	17 (60.7%)	
Surgical theater	16 (29.6%)	11 (39.3%)	
Closure technique			
No need	2 (3.7%)	0	
TTSC	20 (37.0%)	24 (85.7%)	
TTSC/Loop	22 (40.7%)	4 (14.3%)	
OTSC	3 (5.5%)	0	
Suturing	6 (11.1%)	0	
Combination	1 (2.0%)	0	

ESD, endoscopic submucosal dissection; STER, submucosal tunneling endoscopic resection; SD, standard deviation; TTSC, through-the-scope endoscopic clips; OTSC, over-the-scope endoscopic clips

The mean hospital stay in the ESD group was 4 days, whereas in the STER group it was 2 days (P=0.02). In the multivariate analysis (multiple logistic regression) conducted to identify risk factors for prolonged hospitalization beyond the median stay of 3 days, independent risk factors associated with a significantly increased risk were the use of the ESD technique (compared to STER), serosa dissection, and performing the endoscopy in the operating room rather than in the endoscopy suite.

Table 3 Primary and secondary outcomes by endoscopic technique (ESD vs. STER)

Variable, n (%)	ESD (n=54)	STER (n=28)	P-value
En bloc resection	53 (98.2%)	26 (92.9%)	0.226
Agree adverse events			
No	41 (76.0%)	24 (85.7%)	
Grade I	7 (13.0%)	4 (14.3%)	
Grade II	3 (5.5%)	0	
Grade III	2 (3.6%)	0	
Grade IV	1 (1.8%)	0	
Duration of the procedure (min), mean±SD	126±53	105±37	0.066
Hospital stay (days), mean±SD	4±0.4	2±0.2	0.019
Adjuvant treatment			
Chemotherapy/	2 (3.8%)	1 (3.7%)	
immunotherapy	2 (3.8%)	0	
Surgery			
None	49 (92.4%)	26 (96.3%)	
Follow up (months), mean±SD	12±1.6	12±2.8	0.873
Recurrence	2 (3.7%)	0	

ESD, endoscopic submucosal dissection; STER, submucosal tunneling endoscopic resection; AGREE, Adverse events in GastRointEstinal Endoscopy; SD, standard deviation

As for the efficacy of endoscopic resection, additional surgery was necessary in 2 patients, while 3 received adjuvant chemotherapy or immunotherapy. Overall, 2 local recurrences were documented during a median follow up of 12 months, both of which occurred in the ESD group.

Discussion

This is the first multicenter retrospective study outside northeast Asia that evaluates the feasibility and safety of endoscopic resection of gastric SELs originating from the *muscularis propria*. Our study included cases exclusively involving the deep wall layers, including lesions with extraluminal extension, given the paucity of data concerning their endoscopic management. In our patients, 26.8% of the lesions presented with extramural growth. Intentional full-thickness resection with controlled serosal perforation was performed in 31.7% of cases. *En bloc* resection was achieved in 96%, and endoscopic closure was feasible in the vast majority of cases. The recurrence rate was low (3.7%) during a median follow up of 12 months, consistent with previous publications for endoscopically resected SELs (2.2%), and comparable to the surgical series (approximately 5%) [20]. More specifically, the recurrence rate in GISTs <4 cm ranges from 0-6.7% [21].

No recurrence was observed among patients with leiomyomas or pancreatic rests, aligning with their benign behavior. Overall, the complication rate in our study was 7%, and the majority of

the adverse events were successfully managed endoscopically. There were no fatalities. The efficacy and safety were similar in the STER and ESD groups, although STER was used more frequently to treat leiomyomas, which could possibly reflect anatomical accessibility or even tumor morphology.

According to the current guidelines, endoscopic surveillance is recommended for gastric SELs smaller than 2 cm, while surgical resection is suggested in lesions greater than that size [1,5]. However, recent histopathological studies suggest that even small SELs could have a malignant potential, which can range from approximately 15% in early studies [22] to about 40% in more recent ones [23]. Moreover, almost half of SELs <2 cm are found to be GISTs [24]. Despite these indications, there is no consensus on the optimal management of these small lesions.

Surveillance strategies are imperfect and could come with some downsides. Through repeated endoscopies the cumulative costs rise significantly, diagnosis of a malignancy could be delayed, and the uncertainty could lead patients to become non-compliant or to experience psychological distress [25]. In view of these factors, a therapeutic endoscopic resection may offer an alternative option in selected cases, especially in experienced centers.

In contrast to the 4.4% macroperforation rate requiring surgical closure reported by Joo *et al* (25), in our study a deliberate macroperforation was performed in 26 cases (31.5% in ESD and 32.5% in STER), 24 of which were managed successfully using different endoscopic closure modalities. These modalities included through-the-scope clip placement, loop-and-clip combination, cap-assisted clip closure and endoscopic suturing. In most patients, a CT scan with oral contrast was performed the next day to confirm adequate closure. The majority of the patients were discharged within 3 days, highlighting the safety of the procedure when performed by experienced endoscopists.

The AGREE classification system, an update to the ASGE lexicon, was used to classify the complications [19,26]. Mostly minor events were documented. Two patients required surgical closure of wall defects (Grade III), and 1 patient developed peritonitis post-ESD, which was managed conservatively with through-the-scope and over-the-scope endoscopic clip placement, followed by radiologically guided drainage. This patient's hospital stay was 20 days, which was the longest hospital stay overall, in both groups, and most likely influenced the overall higher mean stay in the ESD group.

Lesions treated with ESD were significantly larger than those in the STER group (26.7 vs. 19.0 mm, P=0.0026). Additionally, tumors in anatomically complex locations, such as the cardia or esophagogastric junction, were resected more frequently via ESD. This fact may have contributed to the longer procedure times and greater risk of adverse events in the ESD group, although the difference in procedure duration was not statistically significant (126 vs. 105 min, P=0.07).

Endoscopic resection can potentially have some advantages over surgery in anatomically challenging areas. Near the esophagogastric junction or pylorus, endoscopic resection could be organ-preserving, whereas conventional surgery could require partial gastrectomy [12]. In our study, 18.3% of lesions were located in the cardia, and through the endoscopic resection a more extensive surgical intervention was most likely avoided. In Fig. 3, we propose an algorithm for the endoscopic resection of SELs arising from the muscle layer.

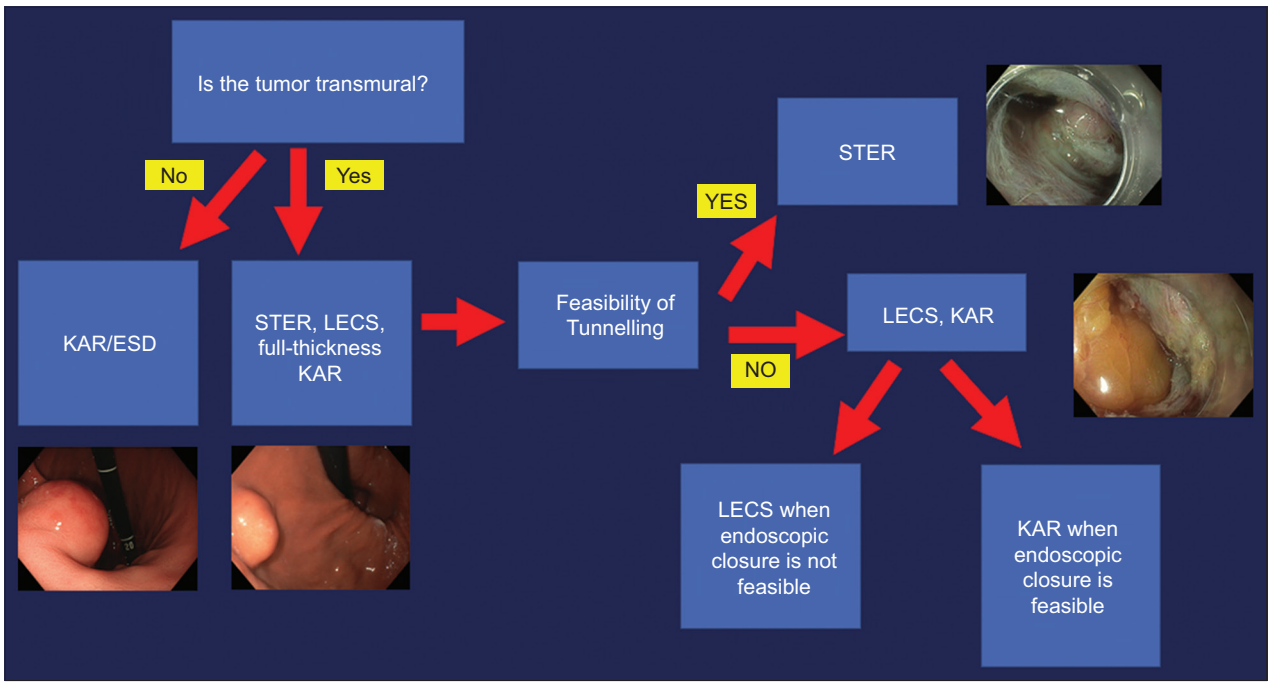

Figure 3 Endoscopic resection strategy for SEL originating from the muscle layer based on the feasibility for tunneling and for endoscopic closure
SEL, subepithelial lesions; KAR, knife assisted resection; ESD, endoscopic submucosal dissection; STER, submucosal tunneling endoscopic resection; LECS, laparoscopic endoscopic cooperative surgery

Interestingly, about one third of the procedures in this study were performed by experienced endoscopists in non-university tertiary care centers, suggesting that advanced endoscopic techniques can be successfully performed outside academic institutions or university hospitals.

The main strengths of this study are the large sample size and the inclusion of multiple centers from different regions, which reflects the real-world heterogeneity in practice and experience of the endoscopist. On the other hand, there are some important limitations, such as the retrospective design of the study and the lack of standardized procedural protocols. Further limitations are the potential selection bias and the variability in follow-up intensity and reporting.

In conclusion, endoscopic resection of gastric subepithelial tumors arising from the *muscularis propria* is a feasible, safe and effective approach, including in selected extraluminal cases, when performed by skilled endoscopists in specialized tertiary centers. Surgical backup should be readily available, particularly in cases involving full-thickness resections. Future prospective studies with longer follow up and risk stratification are needed to define the long-term oncologic outcomes of this minimally invasive approach.

Summary Box

What is already known:

- Gastric subepithelial lesions (SELs) arising from the *muscularis propria* are often managed surgically or with surveillance, in view of their typically low malignant potential
- Endoscopic resection has historically been avoided, because of technical limitations and concerns regarding safety
- Most published data on endoscopic resection of these lesions come from academic centers in China, with limited evidence from other regions

What the new findings are:

- This large multicenter study demonstrates that both endoscopic submucosal dissection and submucosal tunneling endoscopic resection are feasible and safe for gastric SELs arising from the *muscularis propria* in diverse international settings
- High rates of *en bloc* resection and successful closure were achieved, even in lesions with extraluminal growth or extension beyond the serosa
- Procedures were performed effectively, not only in academic but also in non-academic centers, broadening the applicability of these techniques
- Complication rates were low and manageable endoscopically, with no mortality observed

References

1. Sharzehi K, Sethi A, Savides T. AGA clinical practice update on management of subepithelial lesions encountered during routine endoscopy: expert review. *Clin Gastroenterol Hepatol* 2022;**20**: 2435-2443.
2. Hedenbro JL, Ekelund M, Wetterberg P. Endoscopic diagnosis of submucosal gastric lesions. The results after routine endoscopy. *Surg Endosc* 1991;**5**:20-23.
3. Papanikolaou IS, Triantafyllou K, Kourikou A, Rösch T. Endoscopic ultrasonography for gastric submucosal lesions. *World J Gastrointest Endosc* 2011;**3**:86-94.
4. Aghdassi A, Christoph A, Dombrowski F, et al. Gastrointestinal stromal tumors: clinical symptoms, location, metastasis formation, and associated malignancies in a single center retrospective study. *Dig Dis* 2018;**36**:337-345.
5. Deprez PH, Moons LMG, O'Toole D, et al. Endoscopic management of subepithelial lesions including neuroendocrine neoplasms: European Society of Gastrointestinal Endoscopy (ESGE) Guideline. *Endoscopy* 2022;**54**:412-429.
6. Demetri GD, von Mehren M, Antonescu CR, et al. NCCN Task Force report: update on the management of patients with gastrointestinal stromal tumors. *J Natl Compr Cancer Netw* 2010;**8**(Suppl 2):S1-S41.
7. Xu MD, Cai MY, Zhou PH, et al. Submucosal tunneling endoscopic resection: a new technique for treating upper GI submucosal tumors originating from the muscularis propria layer (with videos). *Gastrointest Endosc* 2012;**75**:195-199.
8. Du C, Chai N, Linghu E, et al. Treatment of cardial submucosal tumors originating from the muscularis propria layer: submucosal tunneling endoscopic resection versus endoscopic submucosal excavation. *Surg Endosc* 2018;**32**:4543-4551.
9. Kushnir VM, Keswani RN, Hollander TG, et al. Compliance with surveillance recommendations for foregut subepithelial tumors is poor: results of a prospective multicenter study. *Gastrointest Endosc* 2015;**81**:1378-1384.
10. Casali PG, Blay JY, Abecassis N, et al; ESMO Guidelines Committee, EURACAN and GENTURIS. Electronic address: clinicalguidelines@esmo.org. Gastrointestinal stromal tumours: ESMO-EURACAN-GENTURIS clinical practice guidelines for diagnosis, treatment and follow-up. *Ann Oncol* 2022;**33**:20-33.
11. Chai Y, Lin B, Zhong J, et al. Long-term outcomes of endoscopic therapy versus surgical resection for 2-5 cm gastric gastrointestinal stromal tumors: a population-based comparative study. *Eur J Surg Oncol* 2024;**50**:108262.
12. Zhu S, Liu Z, Zhang J, et al. Endoscopic versus laparoscopic resection of gastrointestinal stromal tumors at the esophagogastric junction using propensity score matching analysis. *Sci Rep* 2025;**15**:15916.
13. Dalal I, Andalib I. Advances in endoscopic resection: a review of endoscopic submucosal dissection (ESD), endoscopic full thickness resection (EFTR) and submucosal tunneling endoscopic resection (STER). *Transl Gastroenterol Hepatol* 2022;**7**:19.
14. Ntourakis D, Mavrogenis G. Cooperative laparoscopic endoscopic and hybrid laparoscopic surgery for upper gastrointestinal tumors: current status. *World J Gastroenterol* 2015;**21**:12482-12497.
15. Mavrogenis G, Chatzis M, Spanomanoli A, Kaklamanis L, Bazerbachi F. Submucosal tunneling endoscopic resection in retroflexion for gastric gastrointestinal stromal tumor of the fundus. *Endoscopy* 2024;**56**:E305-E306.
16. Mavrogenis G, Mitropapas G, Kyriakidou V, Bazerbachi F. Laparoscopic endoscopic cooperative surgery for a gastric glomus tumor previously diagnosed by endoscopic ultrasound fine-needle biopsy. *Ann Gastroenterol* 2020;**33**:219.
17. Kahaleh M, Bhagat V, Dellatore P, et al. Subepithelial tumors: how

does endoscopic full-thickness resection & submucosal tunneling with endoscopic resection compare with laparoscopic endoscopic cooperative surgery? *Endosc Int Open* 2022;**10**:E1491-E1496.
18. von Elm E, Altman DG, Egger M, et al. The STrengthening the Reporting of OBservational studies in Epidemiology (STROBE) statement: guidelines for reporting observational studies. *J Clin Epidemiol* 2008;**61**:344-349.
19. Nass KJ, Zwager LW, van der Vlugt M, et al. Novel classification for adverse events in GI endoscopy: the AGREE classification. *Gastrointest Endosc* 2022;**95**:1078-1085.
20. Park JJ. Long-term outcomes after endoscopic treatment of gastric gastrointestinal stromal tumor. *Clin Endosc* 2016;**49**:232-234.
21. Zhang Y, Mao XL, Zhou XB, et al. Long-term outcomes of endoscopic resection for small (≤ 4.0 cm) gastric gastrointestinal stromal tumors originating from the muscularis propria layer. *World J Gastroenterol* 2018;**24**:3030-3037.
22. Miettinen M, Sobin LH, Lasota J. Gastrointestinal stromal tumors of the stomach: a clinicopathologic, immunohistochemical, and molecular genetic study of 1765 cases with long-term follow-up. *Am J Surg Pathol* 2005;**29**:52-68.
23. Kobayashi R, Hirasawa K, Ozeki Y, et al. Clinical course of small gastric subepithelial lesion less than 20 mm diagnosed by endoscopic ultrasound-guided fine-needle aspiration. *J Gastroenterol Hepatol* 2024;**39**:1285-1290.
24. Hu J, Sun X, Ge N, et al. The necessarity of treatment for small gastric subepithelial tumors (1-2 cm) originating from muscularis propria: an analysis of 972 tumors. *BMC Gastroenterol* 2022;**22**:182.
25. Joo MK, Park JJ, Lee YH, et al. Clinical efficacy and safety of endoscopic treatment of gastrointestinal stromal tumors in the stomach. *Gut Liver* 2023;**17**:217-225.
26. Cotton PB, Eisen GM, Aabakken L, et al. A lexicon for endoscopic adverse events: report of an ASGE workshop. *Gastrointest Endosc* 2010;**71**:446-454.