

# Gastric peroral endoscopic myotomy improves chronic diarrhea in patients with refractory gastroparesis

Maxime Jaccard<sup>a</sup>, Mariola Marx<sup>a</sup>, Elodie Romailier<sup>a</sup>, Meddy Dalex<sup>a</sup>, Marie Phillipart<sup>a</sup>, Fabrice Caillol<sup>b</sup>, Styliani Mantziari<sup>c</sup>, Sébastien Godat<sup>a</sup>

CHUV, Lausanne, Switzerland; Paoli-Calmettes Institute, Marseille, France

## Abstract

**Background** The main symptoms of gastroparesis are early satiety, nausea, vomiting and bloating. In our daily practice, we observed some patients presenting with concomitant chronic alteration of stool frequency. The present study describes retrospectively the impact of gastric peroral endoscopic myotomy (G-POEM) on patients presenting refractory gastroparesis and concomitant chronic diarrhea or constipation.

**Methods** This retrospective study analyzed the clinical course of patients with refractory gastroparesis and concomitant chronic alteration of stool frequency who were consecutively treated with G-POEM between January 2019 and October 2023 in a tertiary referral center.

**Results** Of 107 patients with refractory gastroparesis treated by G-POEM, 11 (10.3%) patients (mean age 60.4±16.2 years, 64% female) had altered bowel frequency for >6 months without any other underlying disease (diarrhea n=10; constipation n=1). Scintigraphy confirmed delayed gastric emptying in 10/11 (91%) of cases. G-POEM was technically feasible in all patients without adverse events during or after endoscopic treatment. The median follow-up period was 170 days (interquartile range [IQR] 33-1002). In 9/11 (81%) patients, G-POEM achieved clinical success with a mean gastroparesis cardinal symptom index (GCSI) of 3.1 (interquartile range [IQR] 2.7-3.4) before, and 0.9 (IQR 0.7-1.7) after the endoscopic treatment. Normalization of bowel movements after G-POEM was observed in 9/11 (81%) of patients. Two patients had partial symptom improvement (loose bowels, but normal frequency), 1 of them without improvement of GCSI and persistent delayed emptying on scintigraphy.

**Conclusion** Gastroparesis may present with concomitant chronic diarrhea that improves after endoscopic treatment by G-POEM.

**Keywords** Gastroparesis, gastric peroral endoscopic myotomy, diarrhea, gastroparesis cardinal symptom index

*Ann Gastroenterol 2025; 38 (XX): 1-7*

Conflict of Interest: Mariola Marx: Fellowship in advanced endoscopy supported by Boston Scientific. The other authors have no conflicts of interest to declare

Correspondence to: Sebastien Godat, MD, Department of Gastroenterology and Hepatology, Centre Hospitalier Universitaire Vaudois (CHUV), University of Lausanne, Rue du Bugnon 44, CH-1011 Lausanne, Switzerland, e-mail: Sebastien.Godat@chuv.ch

These data have been published as an abstract at the ESGE DAYS 2024

Received 16 November 2024; accepted 26 February 2025; published online 28 April 2025

DOI: <https://doi.org/10.20524/aog.2025.0956>

This is an open access journal, and articles are distributed under the terms of the Creative Commons Attribution-NonCommercial-ShareAlike 4.0 License, which allows others to remix, tweak, and build upon the work non-commercially, as long as appropriate credit is given and the new creations are licensed under identical terms.

## Introduction

Gastroparesis is a chronic motility disorder of the stomach characterized by delayed gastric emptying without mechanical outflow obstruction [1]. Recently published large-scale epidemiological studies report a prevalence of 13.8-21.5 per 100,000 persons. The most common etiologies are diabetes mellitus (37.5-57.4%), drugs (11.8-19.6%), and thoracoabdominal surgery (1.1-15.0%). In about 10-40% of patients the underlying cause cannot be identified, and the gastroparesis is referred to as idiopathic. Rare etiologies include connective tissue disorders and neurodegenerative diseases [2-4].

The first-line treatments for gastroparesis are dietary modifications and pharmacological therapy. However, about one third of patients do not have relief with conservative methods and the long-term use of medicaments may lead to

significant side-effects. Gastric peroral endoscopic myotomy (G-POEM) is a minimally invasive third-space endoscopic treatment with short-term clinical success in 70-90% of patients with refractory gastroparesis [5-7].

Typical clinical symptoms of gastroparesis include early satiety, postprandial fullness, nausea, vomiting and bloating and may considerably reduce patients' quality of life [1,8]. However, in our daily praxis, we observed a subgroup of patients with gastroparesis suffering from chronic diarrhea or constipation.

The aim of this study was to retrospectively evaluate the impact of G-POEM on stool frequency in patients presenting with refractory gastroparesis and concomitant chronic diarrhea or constipation.

## Patients and methods

This retrospective study analyzed the clinical course of patients with refractory gastroparesis and chronic alterations of stool frequency treated by G-POEM at a tertiary referral center between January 1, 2018, and October 10, 2023. The study was approved by our institutional ethical review board and human research committee (N°2023-02032). Patients' data were retrieved from the medical folder, including sex, age, body mass index (BMI), comorbidities, etiology of gastroparesis, previous medical treatments and interventions regarding gastroparesis, gastroparesis cardinal symptom index (GCSI), and the presence of diarrhea or constipation. The patients were seen at our outpatient clinic and contacted by telephone to add missing information if needed.

The diagnosis of gastroparesis was based on clinical presentation and imaging studies. Patients underwent gastric emptying scintigraphy (GES) with a radionuclide (<sup>99m</sup>Tc)-labelled low-fat meal (255 kcal). Gastric retention of more than 65% 2 h after eating a low-fat meal, or more than 30% after 3 h, confirms the diagnosis [9].

The GCSI was used to quantify the severity of symptoms, calculated by averaging the mean score of the subscales "post-prandial fullness/early satiety", "nausea/vomiting" and "bloating". Gastroparesis with a GCSI  $\geq 2$  was considered severe [10].

Patients enrolled in the study presented gastroparesis concurrently with chronic diarrhea or constipation. Chronic diarrhea was defined as 3 or more loose stools daily for at least 4 weeks according to the World Health Organization's criteria [11]. Chronic constipation was based on the guidelines of the American College of Gastroenterology: unsatisfactory defecation characterized by infrequent stool, difficult stool passage or both, for at least the previous 3 months [12]. The stool consistency was described using the Bristol stool scale. Type 1 and 2 are abnormally hard stools, whereas type 6 and

7 are considered abnormally loose stools and characteristic of diarrhea. Types 3, 4 and 5 are generally considered to be the most "normal" stool form in cross-sectional surveys of healthy adults [13]. Patients lost to follow up and those with comorbidities other than gastroparesis that might explain constipation or diarrhea were excluded.

## Outcomes

The main objective of the present study was to investigate the effect of G-POEM on the frequency and stool type in patients with refractory gastroparesis and concomitant chronic diarrhea or constipation. Clinical remission of either diarrhea or constipation assessed 3-6 months after G-POEM was defined as a stool frequency of 3 stools/week to 3 stools/day, and a Bristol stool scale between 3 and 5.

Secondary endpoints were the efficacy and complication rate of G-POEM in the abovementioned patient group. Clinical success of G-POEM was defined as a GCSI drop  $\geq 1$  point. In addition, gastric emptying was evaluated before and after the intervention using scintigraphy imaging. Complications were described according to the AGREE classification [14].

## Gastric peroral endoscopic pyloro-antrumomyotomy

All procedures were performed under general anesthesia and CO<sub>2</sub> insufflation using a standard gastroscope with a cap (3.2 mm, Pentax Japan). After submucosal injection of saline solution mixed with indigo carmine (dilution 1:4), a maximum 5 cm incision of the mucosa was performed proximal to the pylorus with a DualKnife™ (Olympus, Japan), preferentially in the posterior part of the antrum. Dissection of the submucosal tunnel towards the pyloric ring was performed with the Triangle Tip electrosurgical knife (Olympus, Japan). Submucosal vessels were coagulated with the Coagrasper Hemostatic Forceps (Olympus, Japan). A complete myotomy of the pylorus and antrum over 2 cm, including the inner circular and oblique layers up to the serosa, was performed using the Triangle Tip Knife (Olympus, Japan). Finally, the mucosal access was closed with endoclips. All patients received a single dose of prophylactic antibiotics during the procedure. They were hospitalized for the surveillance of early complications and discharged the following day after clinical evaluation. A blended diet was recommended for 48 h. Proton pump inhibitors b.i.d. were prescribed for 1 month following endoscopy.

## Statistical analysis

The patient characteristics, technical and clinical success rates, details of the endoscopic procedure, as well as complication rates, were summarized using descriptive statistics: number and percentage for categorical variables; mean, median, standard deviation and interquartile range

<sup>a</sup>Department of Gastroenterology and Hepatology, CHUV, Lausanne, Switzerland (Maxime Jaccard, Mariola Marx, Elodie Romailleur, Meddy Dalex, Marie Phillipart, Sébastien Godat); <sup>b</sup>Department of Gastroenterology, Paoli-Calmettes Institute, Marseille, France (Fabrice Caillol); <sup>c</sup>Department of Visceral Surgery, CHUV, Lausanne, Switzerland (Styliani Mantziari)

(IQR) for continuous variables. Paired data were compared using the Wilcoxon signed-rank test, as the data deviated from a normal distribution. Statistical significance was set at  $P < 0.05$ .

## Results

Between January 1, 2018, and October 10, 2023, a total of 107 patients underwent G-POEM for gastroparesis. Of these, 25 presented with either chronic diarrhea or constipation. Fourteen were excluded because of the presence of comorbidities that might contribute to a delayed or accelerated gastrointestinal transit time (Fig. 1, Table 1).

### Patients' characteristics

The present study included a total of 11 patients diagnosed with concurrent gastroparesis and significant alterations in both stool frequency and consistency (11/107; 10.3%). 63.6% (7/11) of them were women, their mean age was  $60.4 \pm 16.2$  years, and the mean BMI was  $24.5 \pm 5.3$  kg/m<sup>2</sup> (Table 2). Gastroparesis was confirmed by scintigraphy in 10/11 (90.9%) patients. In 1 patient, the diagnosis was based on gastric stasis during gastroscopy and suggestive clinical presentation. The most frequent etiology was post-surgical (54.6%; 6/11), followed by diabetic (27.3%; 3/11) and idiopathic (18.2%; 2/11) gastroparesis. Ten patients (10/11; 90.9%) had chronic diarrhea and 1 patient chronic constipation (1/11; 9.1%).

The initial median GCSI was 3.1 (IQR 2.7-3.4), with a median nausea vomiting subscale score of 3.3 (IQR 2.8-4), a median early satiety subscale of 3.3 (IQR 2.5-4) and a median bloating subscale of 2.5 (IQR 1.8-4). In all 11 patients, gastroparesis was considered severe with a GCSI  $\geq 2$ . The median gastric retention after 2 h was 72% (IQR 66-79).

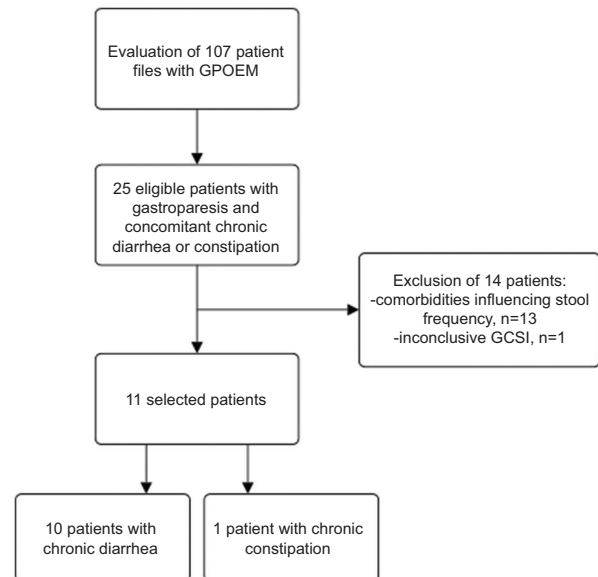
### Impact of G-POEM on stool frequency and consistency

Eight out of 10 (8/10; 80%) patients had complete clinical remission of chronic diarrhea after G-POEM. Their median stool frequency decreased from 5 (IQR 4-5) to 2 (IQR 2-2.8) stools per day, and the median Bristol stool scale from 6 (IQR 6-6.8) to 4 (IQR 4-4) after endoscopic treatment of gastroparesis. These changes were significant ( $P = 0.002$  and  $P = 0.007$ , respectively) (Fig. 2).

Two patients (2/10; 20%) had a partial remission, as their stool frequency normalized but the Bristol stool scale was unchanged.

One patient had chronic constipation with 1 bowel movement every 10 days and a Bristol stool scale of 2. After G-POEM, the stool frequency and consistency normalized (1 stool per day; Bristol stool scale 4).

In total, 9/11 patients (81.8%) had complete normalization of diarrhea or constipation after G-POEM for treatment of gastroparesis. Two patients (2/10; 20%) showed partial



**Figure 1** Flowchart patient inclusion

GCSI, gastroparesis cardinal symptom index; G-POEM, gastric peroral endoscopic myotomy

**Table 1** Patient exclusion

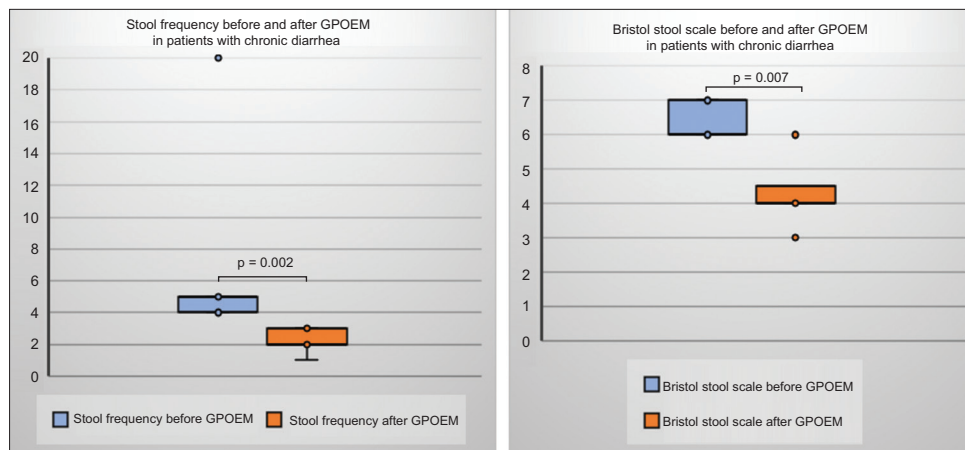
Exclusion criteria	No. of patients (n=14)
Uninterpretable GCSI due to neurocognitive disorder	2
Remission of chronic diarrhea or constipation before G-POEM	4
Neuroendocrine tumor	1
Lactose intolerance	2
Pancreatic insufficiency	1
Small bowel bacterial overgrowth	1
Gastrothorax	1
Colectomy	1
Dumping syndrome	1

GCSI, gastroparesis cardinal symptom index; G-POEM, gastric peroral endoscopic myotomy

remission, with a normalized stool frequency but unchanged Bristol stool scales of 6 and 7. In 1 of them, the endoscopic treatment was also unable to relieve the gastroparesis, as the post-procedural GCSI and gastric emptying scintigraphy remained pathological.

### Efficacy of G-POEM on gastroparesis

All G-POEM procedures were completed successfully, without technical complications or periprocedural adverse events.



**Figure 2** Stool frequency and Bristol stool scale in patients with chronic diarrhea before and after G-POEM  
G-POEM, gastric peroral endoscopic myotomy

**Table 2** Clinical characteristics of included patients (n=11)

Characteristics	Value
Age, mean in years (SD)	60.4±16.2
Women, n (%)	7 (63.6)
BMI, mean in kg/m <sup>2</sup> (SD)	24.5±5.3
Etiology of gastroparesis, n (%)	
Idiopathic	2/11 (18.2)
Diabetes	3/11 (27.3)
Post-surgery	6/11 (54.6)
Preoperative GES, median gastric retention after 2 h in % (IQR)	72 (66-79)
Previous treatment of gastroparesis, n (%)	
None	4/11 (36.4)
Medicaments	5/11 (45.5)
Prior intervention	3/11 (27.3)
Pyloric botulinum toxin injection	2/11 (18.2)
G-POEM	1/11 (9.1)
Patients with chronic diarrhea, n (%)	10/11 (90.9)
Median stool frequency per day (IQR)	5 (4-5)
Median Bristol stool chart (IQR)	6 (6-6.8)
Patients with chronic constipation, n (%)	1/11 (9.1)
Median stool frequency per day	0.1
Median Bristol stool scale	2
GCSI before G-POEM, median (IQR)	
Total GCSI	3.1 (2.7-3.4)
Nausea vomiting subscore	3.3 (2.8-4)
Early satiety/fullness subscore	3.3 (2.5-4)
Bloating subscore	2.5 (1.8-4)

BMI, body mass index; GCSI, gastroparesis cardinal symptom index; GES, gastric emptying scintigraphy; G-POEM, gastric peroral endoscopic myotomy; IQR, interquartile range; SD, standard deviation

Clinical success, defined as a  $\geq 1$  point decrease of the GCSI, was achieved in 81.8% (9/11) of patients (Table 3). Complete remission of gastroparesis was confirmed by gastric emptying scintigraphy in 7/9 patients (77.8%). The median GCSI decreased significantly from 3.1 (IQR 2.67-3.4) to 0.9 (IQR 0.7-1.7) after G-POEM ( $P=0.001$ ). The median subscore scores for nausea/vomiting, early satiety and bloating were

**Table 3** GCSI before and after G-POEM

GCSI before G-POEM	GCSI after G-POEM	Delta
2.4	0.5	1.9
3.7	0.8	2.9
3.6	0.7	2.9
3.4	2.3	1.1
3.1	0.9	2.2
3.2	0.8	2.4
2.5	0	2.5
2.3	1	1.3
3.1	2.8	0.3
3.4	2.8	0.6
2.8	1	1.8

GCSI, gastroparesis cardinal symptom index; G-POEM, gastric peroral endoscopic myotomy

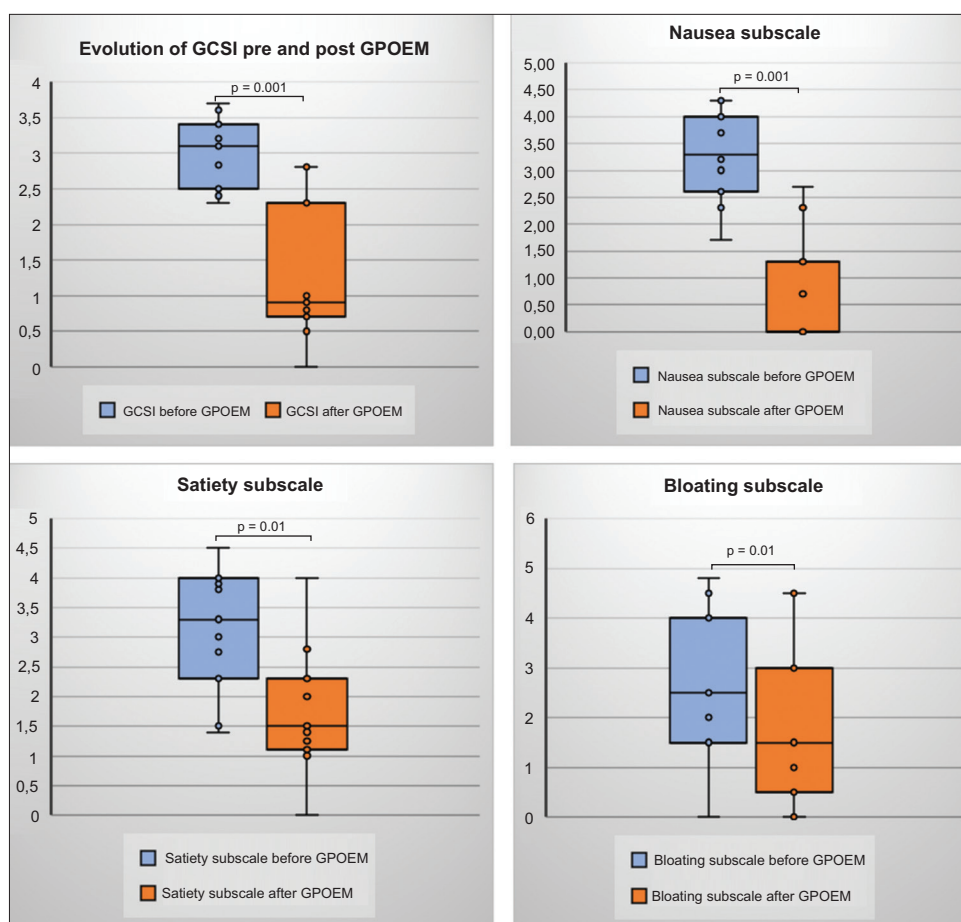
also significantly lower after endoscopic treatment ( $P=0.001$ ,  $P=0.01$  and  $P=0.01$ , respectively; Fig. 3).

Three of the 11 patients (27.3%) had a GCSI  $\geq 2$  after G-POEM, with preprocedural GCSI scores of 3.4, 3.4 and 3.1. One of them had clinical remission according to clinical criteria and chronic diarrhea disappeared. However, the post-interventional GES remained pathological. Among the 2 patients with clinical treatment failure (GCSI decrease by  $<1$  point), 1 patient had normalized gastric emptying scintigraphy and showed complete clinical remission of diarrhea after G-POEM.

#### Adverse events and long-term follow up

The median hospital stay after G-POEM was 1 day (IQR 1-1). There were no early or delayed adverse events associated with the endoscopic procedure.

During the median follow-up period of 170 days (IQR 33-1002), 1 patient presented recurrent diarrhea, but



**Figure 3** Complete GCSI and its subscales before and after G-POEM  
GCSI, gastroparesis cardinal symptom index; G-POEM, gastric peroral endoscopic myotomy

refused further workup. In the remaining patients, symptom improvement remained stable throughout the observation period.

## Discussion

The present study analyzed the impact of G-POEM on stool frequency in 11 individuals diagnosed with gastroparesis and concomitant disorders of the gastrointestinal transit.

To date, many studies have focused on the clinical manifestation and evaluation of gastroparesis [10,15]. To our knowledge, diarrhea and constipation have never been investigated as symptoms of gastroparesis. A 3-5% of the global population suffers from chronic diarrhea and up to 15% are diagnosed with chronic constipation [12,16]. Among the study population described here, the prevalence of concomitant diarrhea in patients with gastroparesis was found to be higher (9.4%), suggesting that diarrhea may be considered a symptom of gastroparesis. The association of gastroparesis and chronic constipation seems less reliable.

The results of the present study also showed that G-POEM may be an effective treatment for these chronic alterations of stool frequency, as 9/11 patients (81.8%) had complete normalization of diarrhea or constipation. In the remaining 2 patients with chronic diarrhea clinical remission was considered partial, with a normalized stool frequency after G-POEM, but unchanged Bristol stool scales of 6 and 7.

The underlying pathophysiology of diarrhea in patients with gastroparesis is not known. There may be several mechanisms causing an increase in stool frequency. Gastric outlet obstruction is known to cause hypergastrinemia with increased acid secretion. Increased acid exposure in the small bowel causes morphologic and inflammatory changes, resulting in malabsorption. Additionally, the low pH may inactivate pancreatic lipase and cause bile salts to precipitate, which can result in malabsorption of fat and steatorrhea [17]. Furthermore, an inadequate gastric bolus ejection may lead to a disproportionate release of bile acids. A small quantity of chyme in the duodenum stimulates the secretion of cholecystokinin, which will lead to bile secretion. Consequently, the ratio of bile excretion to gastric bolus output



in the duodenum is elevated in individuals with gastroparesis. An excess of free bile acids in the ileum may saturate the mucosal reabsorption capabilities and directly stimulate the ileal and colonic mucosa. This stimulation enhances the mucosa permeability, water secretion (through the activation of cystic fibrosis transmembrane conductance regulator channels), lubrication (by increased mucus secretion) and colonic motility, in a way analogous to bile acid malabsorption syndrome [18]. However, in order to confirm this hypothesis, detailed stool analysis needs to be performed to calculate the fecal osmotic gap and the biliary acid concentration. Endoscopic myotomy may help to restore the balance between bile acid secretion and bolus output of the stomach, and thus relieve diarrhea.

In addition, impaired gastric emptying is usually associated with related motility abnormalities, which may independently predispose to small bowel bacterial overgrowth, characterized by bloating, diarrhoea and malabsorption [19].

Concerning the classical gastroparesis symptoms, the present results confirm the findings of previous studies [15,20]. Clinical success of G-POEM based on GCSI was achieved in 81.8% of patients. Endoscopic myotomy significantly improved the nausea, satiety and bloating subscale. However, 3 patients still presented severe gastroparesis (GCSI  $\geq 2$ ) after G-POEM and 2 of them had no clinical success, as the GCSI decreased to  $<1$  point. Gastric emptying scintigraphy remained pathological in 1 of these patients but showed an absence of gastroparesis in the other.

This study was limited by its retrospective nature and small sample size, which is not representative of the whole population of patients with gastroparesis and chronic disorders of the gastrointestinal transit. The variable timespan, ranging from 3-6 months between the endoscopic procedure and the first postprocedural evaluation, should also be considered.

Future research needs larger prospective studies with comprehensive stool analyses to understand the etiology and underlying mechanisms of diarrhea in gastroparesis. A causal association between gastroparesis and constipation lacks clear evidence and needs further investigation.

Despite the abovementioned limitations, our results reveal a new clinical symptom of gastroparesis, going beyond the known upper gastrointestinal tract-associated spectrum. As is the case for classical gastroparesis symptoms, diarrhea improves after endoscopic treatment.

In conclusion, a subgroup of patients with gastroparesis present concomitant diarrhea at a rate higher than in the general population. This finding suggests that diarrhea may be considered a symptom of gastroparesis. Patients with a clinically successful G-POEM have shown a normalization of their stool frequency. The underlying pathophysiological mechanism must be clarified and further investigations are needed, with a complete diagnostic workup of chronic diarrhea before endoscopic treatment.

## Summary Box

### What is already known:

- Gastroparesis is a chronic motility disorder of the stomach characterized by delayed gastric emptying without mechanical outflow obstruction
- Typical clinical symptoms of gastroparesis include early satiety, postprandial fullness, nausea, vomiting and bloating
- The European Society of Gastrointestinal Endoscopy recommends gastric peroral endoscopic myotomy (G-POEM) as a minimally invasive third-space endoscopic treatment for patients with refractory gastroparesis

### What the new findings are:

- A subgroup of patients with gastroparesis present concomitant diarrhea at a rate higher than the general population, suggesting that diarrhea may be considered a symptom of gastroparesis
- Gastroparesis-related diarrhea may be more common than previously recognized, with 9.4% of gastroparesis patients experiencing chronic diarrhea, emphasizing the need for further exploration of this association
- Clinically successful G-POEM may lead to a complete normalization of stool frequency and significantly improve the patient's quality of life

## References

1. Parkman HP, Hasler WL, Fisher RS; American Gastroenterological Association. American Gastroenterological Association technical review on the diagnosis and treatment of gastroparesis. *Gastroenterology* 2004;**127**:1592-1622.
2. Ye Y, Yin Y, Huh SY, Almansa C, Bennett D, Camilleri M. Epidemiology, etiology, and treatment of gastroparesis: real-world evidence from a large US national claims database. *Gastroenterology* 2022;**162**:109-121.
3. Ye Y, Jiang B, Manne S, et al. Epidemiology and outcomes of gastroparesis, as documented in general practice records, in the United Kingdom. *Gut* 2021;**70**:644-653.
4. Soykan I, Sivri B, Sarosiek I, Kiernan B, McCallum RW. Demography, clinical characteristics, psychological and abuse profiles, treatment, and long-term follow-up of patients with gastroparesis. *Dig Dis Sci* 1998;**43**:2398-2404.
5. McCurdy GA, Gooden T, Weis F, et al. Gastric peroral endoscopic pyloromyotomy (G-POEM) in patients with refractory gastroparesis: a review. *Therap Adv Gastroenterol* 2023;**16**:17562848231151289.
6. Su A, Conklin JL, Sedarat A. Endoscopic therapies for gastroparesis. *Curr Gastroenterol Rep* 2018;**20**:25.
7. Weusten BLAM, Barret M, Bredenoord AJ, et al. Endoscopic management of gastrointestinal motility disorders - part 1:

- European Society of Gastrointestinal Endoscopy (ESGE) Guideline. *Endoscopy* 2020;**52**:498-515.
8. Parkman HP, Wilson LA, Yates KP, et al; NIDDK/NIH Clinical Gastroparesis Consortium. Factors that contribute to the impairment of quality of life in gastroparesis. *Neurogastroenterol Motil* 2021;**33**:e14087.
  9. Abell TL, Camilleri M, Donohoe K, et al; American Neurogastroenterology and Motility Society and the Society of Nuclear Medicine. Consensus recommendations for gastric emptying scintigraphy: a joint report of the American Neurogastroenterology and Motility Society and the Society of Nuclear Medicine. *J Nucl Med Technol* 2008;**36**:44-54.
  10. Revicki DA, Camilleri M, Kuo B, Szarka LA, McCormack J, Parkman HP. Evaluating symptom outcomes in gastroparesis clinical trials: validity and responsiveness of the Gastroparesis Cardinal Symptom Index-Daily Diary (GCSI-DD). *Neurogastroenterol Motil* 2012;**24**:456-463, e215-6.
  11. World health organization. Diarrhoeal disease. 2024. Available from: <https://www.who.int/news-room/fact-sheets/detail/diarrhoeal-disease> [Accessed 7 March 2025].
  12. Ford AC, Moayyedi P, Lacy BE, et al. American College of Gastroenterology monograph on the management of irritable bowel syndrome and chronic idiopathic constipation. *Am J Gastroenterol* 2014;**109** Suppl 1:S2-S26.
  13. Blake MR, Raker JM, Whelan K. Validity and reliability of the Bristol Stool Form Scale in healthy adults and patients with diarrhoea-predominant irritable bowel syndrome. *Aliment Pharmacol Ther* 2016;**44**:693-703.
  14. Nass KJ, Zwager LW, van der Vlugt M, et al. Novel classification for adverse events in GI endoscopy: the AGREE classification. *Gastrointest Endosc* 2022;**95**:1078-1085.
  15. Mekaroonkamol P, Dacha S, Wang L, et al. Gastric peroral endoscopic pyloromyotomy reduces symptoms, increases quality of life, and reduces health care use for patients with gastroparesis. *Clin Gastroenterol Hepatol* 2019;**17**:82-89.
  16. Abdullah M, Firmansyah MA. Clinical approach and management of chronic diarrhea. *Acta Med Indones* 2013;**45**:157-165.
  17. Hauser SC, Sweetser SR, Leise MD, et al. Mayo Clinic Gastroenterology and Hepatology Board Review. Oxford University Press; 2024.
  18. Camilleri M. Bile acid diarrhea: prevalence, pathogenesis, and therapy. *Gut Liver* 2015;**9**:332-339.
  19. Clarke JO. SIBO in Gastroparesis: sci-fi or science fact? *Dig Dis Sci* 2014;**59**:510-512.
  20. Ragi O, Jacques J, Branche J, et al. One-year results of gastric peroral endoscopic myotomy for refractory gastroparesis: a French multicenter study. *Endoscopy* 2021;**53**:480-490.