Annals of Gastroenterology (2024) **37,** 1-5

Pathology results of endoscopic ultrasound-guided tissue acquisition in retroperitoneal masses: a multicenter study

Mariana Quintanar-Martínez[a], Maria del Carmen Manzano-Robleda[b,c], Enrique Murcio-Pérez[d], Gustavo López-Arce[e], Isaac Bartnicki-Navarrete[d], Luis Uscanga[f], Angélica Hernández-Guerrero[b], Jorge López-Cossio[g], Alvaro Villalobos-Garita[h], Jorge Perales-Oliva[c], José Vargas-Jimenez[h], Félix Téllez-Ávila[i]

Instituto Nacional de Ciencias Médicas y Nutrición Salvador Zubirán, Ciudad de México, México; Instituto Nacional de Cancerología, Ciudad de México, México; Medica Sur Clinic and Foundation, Ciudad de México, México; National Medical Center Century XXI, IMSS, Ciudad de México, México; Hospital Ángeles Centro Sur, Queretaro, México; Hospital del Prado, Tijuana, Baja California, México; Hospital Calderón Guardia/Clínica Biblíca, San José Costa Rica; University of Arkansas for Medical Sciences, USA

Abstract

Background Malignant etiologies are found in 70-80% of symptomatic retroperitoneal masses. Histology is required for diagnosis and treatment. Information about endoscopic ultrasound (EUS)-guided tissue acquisition (EUS-GTA) is scant for retroperitoneal masses. This study aimed to assess the pathology results of EUS-GTA for diagnosing retroperitoneal masses.

Methods This retrospective, multicenter study involved patients from 5 care centers. All patients with retroperitoneal masses who underwent EUS evaluation were enrolled. We recorded demographic and clinical characteristics, location and size of the mass, type of needle (FNA/FNB), and complications related to the procedure.

Results A total of 43 patients were included. The median age was 50.5 (range: 23-83) years, and 22 (51.2%) were female. The initial symptom was abdominal pain in 23 (52.3%) cases and weight loss in 11 (25%). Initial imaging was by computed tomography in 33 (75%) patients. Diagnosis with EUS-GTA was reached in 67.5% (29/43) cases. The most frequent histological diagnosis was carcinoma, in 25.5% (11/43). A malignant etiology was found in 31 (72%): 20 were primary tumors from the retroperitoneum, and 11 were metastases. In patients with metastasis, surgery was avoided and medical treatment was indicated. No adverse events were reported.

Conclusion EUS and EUS-GTA can frequently provide accurate tissue diagnosis and significantly impact the subsequent management.

Keywords Endoscopic ultrasound, retroperitoneal mass, fine-needle aspiration, fine-needle biopsy

Ann Gastroenterol 2024; 37 (1): 1-5

Conflict of Interest: None

Correspondence to: Félix Ignacio Téllez-Ávila, MD, PhD, Division of Gastroenterology and Hepatology, University of Arkansas for Medical Sciences, 4301 West Markham Street, Little Rock, AR 72205, Arkansas, USA, e-mail: felixtelleza@gmail.com

Received 3 September 2023; accepted 30 October 2023; published online 20 December 2023

DOI: https://doi.org/10.20524/aog.2024.0846

Introduction

The retroperitoneum is an area that contains multiple gastrointestinal organs, lymph nodes, and vascular structures. A diverse array of pathologies may manifest within this anatomical region, encompassing benign conditions as well as the more prevalent occurrence of primary or metastatic malignant tumors [1]. Given their location, retroperitoneal tumors can cause a diagnostic and therapeutic problem. To make an appropriate diagnosis, a tissue sample must be obtained using fine-needle aspiration (FNA), guided either by abdominal ultrasound or by contrast-enhanced tomography. Because of the location of the retroperitoneum and the consequent difficulty of access, these modalities carry complications [1].

Given the proximity of the endoscopic ultrasound (EUS) probe to the gastrointestinal wall, retroperitoneal lesions have become more accessible, and a safer approach to tissue acquisition for these types of tumors can be made. However, only limited information has been published on EUS tissue acquisition in retroperitoneal tumors [2-6]. This study evaluated the pathology results of EUS-guided tissue acquisition (EUS-GTA) in patients with non-hepato-pancreatic-biliary or non-adrenal retroperitoneal lesions.

Patients and methods

This was a retrospective study of data collected prospectively from electronic and paper records of adult patients (older than 18 years) with EUS-TGA of retroperitoneal masses. Based on the computed tomography (CT) scan, magnetic resonance imaging (MRI) or EUS findings, patients with masses from adrenal glands, kidneys, ureters or pancreas were excluded. Patients were seen from January 2006 to December 2019. Patients from 5 referral centers in 2 countries were included. The local Institutional Review Board evaluated and authorized the protocol (REF. 3579).

All patients had complete blood count and prothrombin time before the procedure. Patients were continuously monitored throughout the procedure. Patients were placed in the left decubitus position. One anesthetist sedated the patients using a combination of midazolam, propofol and fentanyl. EUS-FNA was performed using a FUJI EG-530UT linear array echoendoscope with an SU-8000 console (Fujifilm Corporation, Minato-Ku, Tokyo, Japan) or an OLYMPUS GF UC140 EUM2 ultrasound gastroscope by 1 of 5 echo endoscopists. All patients were observed for at least 3 hours after the procedure to monitor possible complications.

Standard Echo Tip Ultra 22-G or 19-G needles (Cook Medical, Inc., Winston Salem, North Carolina, USA) were used for FNA, and Acquire needles calibers 19-G, 22-G, or 25-G (Boston Scientific, Inc., Ireland) for FNB. Procedures via D2 were performed using 25-G needles. Those in a different position (D1 or transgastric route) were carried out using a 19-G or 22-G needle, according to the physician's preference. After 2014, patients underwent EUS-GTA using the fanning technique. Before 2014, no evidence was available about this technique [7].

[a]Department of Gastrointestinal Endoscopy, Instituto Nacional de Ciencias Médicas y Nutrición Salvador Zubirán, Ciudad de México, México (Mariana Quintanar-Martínez); [b]Department of Endoscopy, Instituto Nacional de Cancerología, Ciudad de México, México (Maria del Carmen Manzano-Robleda, Angélica Hernández-Guerrero); [c]Gastroenterology Department, Medica Sur Clinic and Foundation, Ciudad de México, México (Maria del Carmen Manzano-Robleda, Jorge Perales-Oliva); [d]Department of Endoscopy, National Medical Center Century XXI, IMSS, Ciudad de México, México (Enrique Murcio-Pérez, Isaac Bartnicki-Navarrete); [e]Hospital Ángeles Centro Sur, Queretaro, México (Gustavo López-Arce); [f]Department of Gastroenterology, Instituto Nacional de Ciencias Médicas y Nutrición Salvador Zubirán, Ciudad de México, México (Luis Uscanga); [g]Hospital del Prado, Tijuana, Baja California, México (Jorge López-Cossio); [h]Department of Gastroenterology and Digestive Endoscopy, Hospital Calderón Guardia/Clínica Biblíca, San José Costa Rica (Alvaro Villalobos-Garita José Vargas-Jimenez); [i]Division of Gastroenterology and Hepatology, University of Arkansas for Medical Sciences, USA (Félix Téllez-Ávila)

EUS-GTA technique

First, the transducer was brought into a stable position. The needle was then introduced into the biopsy channel, and when it was inserted completely the Luer-lock handle was firmly screwed into the biopsy channel. The stylet was slightly retracted, the needle was positioned into the mass, negative pressure was connected, and the biopsy needle was moved forward into the lesion under real-time ultrasound control. The syringe piston was locked into this position for permanent suction. The needle was moved back and forth 10-15 times inside the lesion under complete ultrasonic control. With the needle tip still in the lesion, suction was released, and the needle was removed from the working channel.

All specimens were fixed in formalin and processed for histological and cytological analysis. In each center, a single expert pathologist evaluated the tissue samples. The cytological diagnoses were then categorized as positive for malignancy, benign/reactive process, or non-diagnostic. Material reported as suspicious for malignancy, or atypical cells indeterminate for malignancy, were considered negative (failures). The final diagnosis (the gold standard) was based on the results from the surgical specimen, and follow up for at least 6 months in non-operated cases was achieved via global clinical and radiological assessment.

Complications were defined according to the American Society for Gastrointestinal Endoscopy's lexicon [8]. Immediate complications (intraprocedural and in the recovery area) were evaluated in all patients.

Statistical analysis

The results were evaluated using mean and standard deviation, or absolute and relative frequencies. According to the variable, differences between groups were tested using the chi-square or Mann-Whitney *U* test. A 2-tailed P-value <0.05 was considered significant. To evaluate diagnostic yield, the sensitivity and specificity, and positive and negative predictive values, were calculated based on the result of the gold standard. All analyses were conducted using SPSS 20 for Mac.

Results

Sixty-six patients with retroperitoneal masses were detected, and 23 were excluded (Fig. 1). Thus, 43 patients were included in the final analysis. The patients' median age was 50.5 (range: 23-83) years, and 22 (51.2%) were female. EUS-GTA was

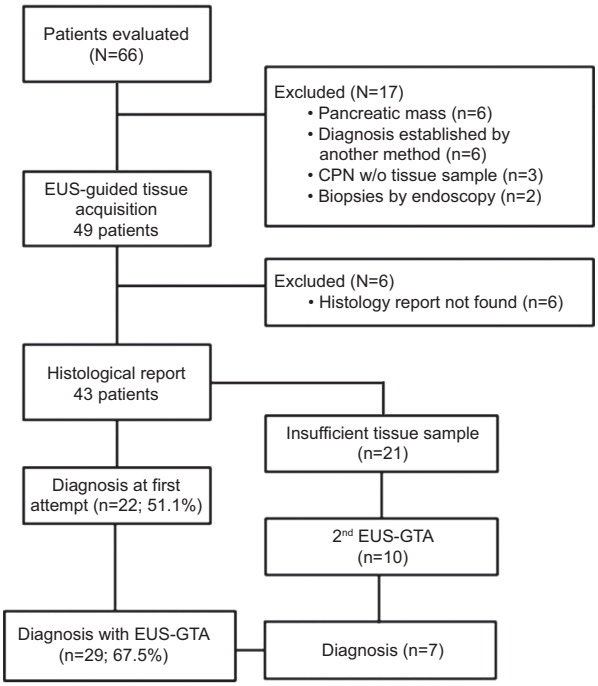

Figure 1 Flowchart of the patients included in the study
EUS-GTA, EUS-guided tissue acquisition; CPN, celiac plexus neurolysis

performed in all these 43 patients (100%). A histological report from the EUS-guided tissue samples was available in all cases. Table 1 shows the characteristics of the included population. The mean size of the masses was 61.8±30 mm (median 60 mm, range: 18-150 mm). The most frequent histological diagnosis was adenocarcinoma/carcinoma in 14/43 (32.6%), followed by lymphoma in 10 (23.2%). Table 1 shows all the diagnoses obtained with EUS-TGA. In total, 31 (72%) patients had a malignant etiology: 17 were primary tumors from the retroperitoneum, and 14 were metastases. In these 14 patients with metastases surgery was avoided and medical treatment was started.

The positive pathological result rate for the first EUS procedure was 51.1% (22/43). Ten patients had a second EUS-GTA procedure and a diagnosis was achieved in 7 of them, for an overall diagnostic yield of 67.5% (29/43). FNA needles were used in 21 (48.8%) patients and FNB needles in 16 (37.2%). In 6 patients this information was unavailable. The caliber of the needles was 19 G in 10 (23.3%) patients, 22 G in 24 (55.8%) patients, and 25 G in 5 (11.6%) cases. In 4 (14%) cases the information was unavailable. The median number of passes was 2 (range: 1-7).

In 14/43 (32.5%) patients it was impossible to obtain the diagnosis by EUS-GTA: 4 underwent percutaneous biopsy, 4 surgical laparoscopy, 1 patient died before an extra procedure, and 5 patients were lost to follow up. A diagnosis was obtained in 8 of these patients: 4 had lymphoma, 2 retroperitoneal fibrosis associated with IgG4 disease, 1 liposarcoma, and 1 granulomatous lymphadenitis. Table 2 shows the univariate analysis to evaluate characteristics associated with diagnostic EUS-GTA.

No adverse events associated with EUS-GTA were reported. No mortality related to endoscopic procedures was reported.

Table 1 Clinical characteristics of the patients included in this study

Characteristics	n (%)
Female sex	22 (51.2)
Age, median (min-max)	50.5 (23-83)
Evolution, months, median (min-max)	5 (1-72)
Hemoglobin, g/dL	13.6 (5.1-17.5)
Platelets, x10^9/L	251 (92-580)
Initial symptom	
Abdominal pain	22 (51.2)
Weight loss	10 (23.3)
Incidental finding	3 (7)
Final histological diagnosis with EUS-GTA	
Adenocarcinoma/carcinoma	14 (32.6)
Poorly differentiated carcinoma (unknown origin)	6
Poorly differentiated adenocarcinoma (unknown origin)	4
Gallbladder adenocarcinoma (phenotype)	1
Endometrioid adenocarcinoma (phenotype)	1
Renal cancer (phenotype)	1
Pancreatobiliary (phenotype)	1
Lymphoma	10 (23.3)
Retroperitoneal fibrosis	2 (4.7)
Sarcoma	2 (4.7)
Tuberculosis	1 (2.3)
Non-diagnostic	14 (32.6)
Biopsy by a different method before EUS-GTA	5 (11.6)

EUS-GTA, endoscopic ultrasound-guided tissue acquisition

Discussion

According to our results, EUS and EUS-GTA can frequently provide accurate tissue diagnosis, help clarify the diagnosis, and significantly impact subsequent management. Retroperitoneal masses are uncommon findings in general practice, and information about these cases is scarce. When these patients are seen in clinical practice, it is common for physicians to have questions about the best way to obtain tissue for diagnosis. Previously, image-guided or surgical interventions were the most common options. Tissue acquisition can be performed percutaneously, based on guidance from US and CT [9]. However, a randomized comparison between EUS-FNA vs. CT- or US-guided tissue samples for malignant pancreatic tumors has revealed better results for EUS [10]. EUS has emerged as an essential resource for obtaining tissue from all organs surrounding the gastrointestinal tract, including the retroperitoneal area [6] (Fig. 2). Because of this, in some institutions EUS-TGA has become the first-line option for obtaining tissue samples in most of these cases. The present study shows evidence of the utility of EUS-GTA in patients with retroperitoneal masses. EUS is an ambulatory procedure, with low risk and high diagnostic yield, that has been widely probed in different scenarios, mainly pancreaticobiliary [11-13], though evidence in other non-

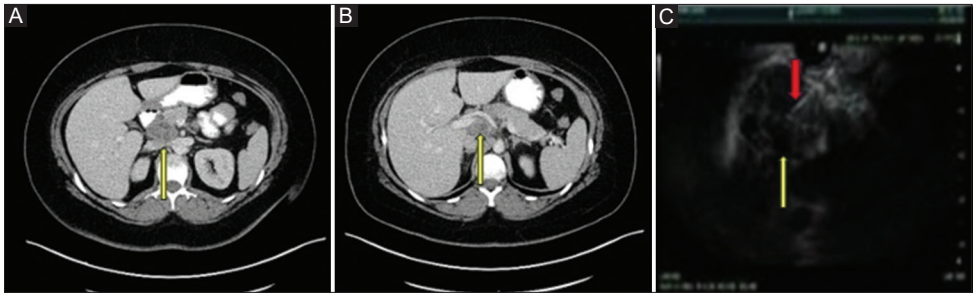

Figure 2 Retroperitoneal mass: (A) oral phase; (B) venous phase; (C) EUS-FNB. Yellow arrow: mass. Red arrow: FNB needle
EUS, endoscopic ultrasound; FNB, fine-needle biopsy

Table 2 Univariate analysis to evaluate characteristics associated with a diagnostic EUS-GTA

Characteristic	Non-diagnostic n=14	Diagnostic n=29	P-value
Female sex	8 (57)	14 (48.2)	0.58
Malignant lesions	8 (57)	26 (89.6)	0.07
Lesions≥4 cm	7 (50)	18 (62)	0.36
FNB needle	5 (35.7)	11 (37.9)	0.66
≥3 passes	4 (28.5)	11 (37.9)	0.38

EUS-GTA, EUS-guided tissue acquisition; FNB, fine-needle biopsy

pancreatic scenarios has been reported [14,15].

Similarly to other reports [4,9], malignant lesions were the most common etiology for the retroperitoneal mass in this series. In all previous reports but one [4], kidney, pancreas or adrenal gland lesions were included. We excluded those patients in order to get a more homogenous sample. For patients with renal, adrenal or pancreatic masses, the clinician frequently does not have questions about the next step (take biopsies or surgery); moreover, as in kidney masses, patients are seen by other specialists other than gastroenterologists. However, patients who have CT scan reports of "retroperitoneal mass" with "unknown" origin represent a big issue for the clinician. Previous studies have reported that sarcomas are the most frequent primary retroperitoneal tumors, with lymphomas in second place [4]. Our findings are different as regards that point. In our study, malignant carcinomas were the tumors most frequently diagnosed (32%), followed by lymphomas (22%). The difference could be related to results from different populations, or to changes in epidemiology after almost 30 years [5]. The patients included in this study were Hispanic, and may differ from those in previous reports [4]. However, it is important to consider that the Hispanic population in the USA is currently almost 20% of the total, making up the largest minority.

Symptoms of retroperitoneal neoplasms include abdominal discomfort, fatigue, weight loss, occasionally fever or pain radiating to the back and thighs, and symptoms resulting from compression of adjacent organs. In our series, abdominal pain and weight loss were present in about 80% of the cases. Only in 3 patients was the finding of the retroperitoneal mass an incidental finding (in all 3 it was revealed by a CT scan). All included patients had undergone previous imaging before EUS, mainly CT scans (n=33) or MRI (n=7). In contrast, only 5 (11.6%) patients had a biopsy by a different method before EUS-GTA. This could be related to the fact that all patients were seen in referral centers where EUS is an available resource, and physicians are aware of the potential for access to the retroperitoneum using EUS. Furthermore, information about the excellent performance of EUS-GTA in retroperitoneal organs, mainly the pancreas, is widely available, including information from our center [11,12,16,17].

In most cases, EUS-TGA has become the first-line option for obtaining tissue samples in these institutions. Moreover, it is well known that CT often has difficulty visualizing some retroperitoneal lesions; thus, CT-FNA cannot be expected to have a higher yield when visualization of the lesion in question is problematic. Here, it should be emphasized that there are no clinical guidelines with recommendations about the best method for obtaining tissue samples in patients with retroperitoneal masses.

The diagnostic yield obtained in this report was not as excellent as it might be for other retroperitoneal organs, such as the pancreas. This could be related to cytological diagnosis in non-pancreatic retroperitoneal tumors, which can be challenging for cytopathologists. In most of the malignancies we detected in the retroperitoneal space, the final determination of malignancy may need a complete histological examination of the resected specimen. However, being able to get a presurgical diagnosis could be very important, because some patients may need medical treatment (such as lymphomas or metastatic carcinomas) instead of surgery.

Identifying factors that could predict success in getting a diagnostic tissue with EUS-GTA presents a challenge. In this study, we were not able to identify any of these factors. "Malignancy" in the histology was the only factor with a trend towards statistical significance in our analysis, but it was not reached. Interestingly, the use of FNB vs. FNA needles did not show differences. This could be related to the sample size or the technique used during the procedures. Unfortunately, this was a retrospective study from different centers, and we do not have information about the specific technique used in each patient.

As we mentioned, sample size and the study design could be considered the main limitations of this study. However, to our knowledge, this report represents the largest sample reported

of patients with retroperitoneal masses who underwent EUS-GTA. Designing a prospective study with appropriate subgroups to study factors such as the type of needle or the technique used (wet suction, fanning technique, slow pull, etc.) could be very difficult in this group of patients, given their uncommon pathology. Another limitation is that not all our patients had IgG4 levels determined. The earliest patients included were seen starting in 2006, at which time IgG4 determination was unavailable in our countries. Only patients seen in the last ~5 years had IgG4 determination available. Rapid on-site evaluation (ROSE) proved helpful in cases where EUS-FNA was used; however, ROSE is not needed since FNB became available. We recommend using FNB needles plus macroscopic on-site evaluation in retroperitoneal masses [18]. Other techniques, such as elastography or contrast during EUS, have not been evaluated in cases of retroperitoneal masses; however, we consider that any of these could change the need for tissue for the correct diagnosis.

In conclusion, our results show that EUS-GTA can frequently provide accurate tissue diagnosis, help clarify the diagnosis, and significantly impact management. The information in this study could be used for future guidelines on this topic.

Summary Box

What is already known:

- The retroperitoneum is an area that contains multiple gastrointestinal organs, lymph nodes and vascular structures
- Because it is difficult to obtain tissue samples, retroperitoneal tumors can cause a problem in diagnosis
- A tissue sample must be obtained by abdominal ultrasound or contrast-enhanced tomography to make a diagnosis; however, these modalities carry inherent complications, given the inability to follow the needle track properly

What the new findings are:

- This report represents the largest sample of patients with retroperitoneal masses who underwent endoscopic ultrasound-guided tissue acquisition (EUS-GTA)
- Malignant lesions were the most common etiology for retroperitoneal masses in this series
- EUS-GTA can frequently provide accurate tissue diagnosis, help clarify the diagnosis, and significantly impact the patient's subsequent management
- No adverse events or mortality associated with EUS-GTA were reported

References

1. Catalano MF, Sial S, Chak A, et al. EUS-guided fine needle aspiration of idiopathic abdominal masses. *Gastrointest Endosc* 2002;**55**:854-858.
2. Kaffes AJ, Chen RY, Tam W, et al. A prospective multicenter evaluation of a new side-port endoscopic ultrasound-fine-needle aspiration in solid upper gastrointestinal lesions. *Dig Endosc* 2012;**24**:448-451.
3. Thosani N, Ferguson K, Buryanek J, Lesslie D, Spinn MP. A rare case of incidental retroperitoneal seminoma diagnosed by endoscopic ultrasound-guided fine-needle aspiration. *Endosc Ultrasound* 2014;**3**:66-67.
4. Erickson RA, Tretjak Z. Clinical utility of endoscopic ultrasound and endscopic ultrasound-guided fine needle aspiration in retroperitoneal neoplasms. *Am J Gastroenterol* 2000;**95**:1188-1194.
5. Black T, Guy CD, Burbridge RA. Retroperitoneal cystic lymphangioma diagnosed by endoscopic ultrasound-guided fine needle aspiration. *Clin Endosc* 2013;**46**:595-597.
6. Anand D, Barroeta JE, Gupta PK, Kochman M, Baloch ZW. Endoscopic ultrasound guided fine needle aspiration of non-pancreatic lesions: an institutional experience. *J Clin Pathol* 2007;**60**:1254-1262.
7. Bang JY, Magee SH, Ramesh J, Trevino JM, Varadarajulu S. Randomized trial comparing fanning with standard technique for endoscopic ultrasound-guided fine-needle aspiration of solid pancreatic mass lesions. *Endoscopy* 2013;**45**:445-450.
8. Cotton PB, Eisen GM, Aabakken L, et al. A lexicon for endoscopic adverse events: report of an ASGE workshop. *Gastrointest Endosc* 2010;**71**:446-454.
9. Mangal N, Sharma VK, Verma N, Agarwal AK, Sharma SP, Aneja S. Ultrasound guided fine needle aspiration cytology in the diagnosis of retroperitoneal masses: A study of 85 cases. *J Cytol* 2009;**26**:97-101.
10. Horwhat JD, Paulson EK, McGrath K, et al. A randomized comparison of EUS-guided FNA versus CT or US-guided FNA for the evaluation of pancreatic mass lesions. *Gastrointest Endosc* 2006;**63**:966-975.
11. Pouw RE, Barret M, Biermann K, et al. Endoscopic tissue sampling - Part 1: Upper gastrointestinal and hepatopancreatobiliary tracts. European Society of Gastrointestinal Endoscopy (ESGE) Guideline. *Endoscopy* 2021;**53**:1174-1188.
12. Polkowski M, Jenssen C, Kaye P, et al. Technical aspects of endoscopic ultrasound (EUS)-guided sampling in gastroenterology: European Society of Gastrointestinal Endoscopy (ESGE) Technical Guideline - March 2017. *Endoscopy* 2017;**49**:989-1006.
13. Téllez-Ávila FI, Bernal-Méndez AR, Guerrero-Vázquez CG, Martínez-Lozano JA, Ramírez-Luna M. Diagnostic yield of EUS-guided tissue acquisition as a first-line approach in patients with suspected hilar cholangiocarcinoma. *Am J Gastroenterol* 2014;**109**:1294-1296.
14. Téllez-Ávila FI, Duarte-Medrano G, Lopez-Arce G, et al. EUS-guided tissue samples for the diagnosis of patients with a thickened gastric wall and prior negative endoscopic biopsies. *Acta Gastroenterol Belg* 2019;**82**:359-362.
15. Manthopoulou E, Ramai D, Ioannou A, et al. Endoscopic ultrasound-guided tissue acquisition beyond the pancreas. *Ann Gastroenterol* 2023;**36**:257-266.
16. Téllez-Ávila FI, Martínez-Lozano JA, Rosales-Salinas A, et al. Repeat endoscopic ultrasound fine needle aspiration after a first negative procedure is useful in pancreatic lesions. *Endosc Ultrasound* 2016;**5**:258-262.
17. Ramírez-Luna MA, Zepeda-Gómez S, Chávez-Tapia NC, Téllez-Avila FI. Diagnostic yield and therapeutic impact of fine-needle aspiration biopsies guided by endoscopic ultrasound in pancreatic lesions. *Rev Invest Clin* 2008;**60**:11-14.
18. Leung KEL, Lemaistre AI, Fabien FF, et al. Macroscopic onsite evaluation using endoscopic ultrasound fine needle biopsy as an alternative to rapid onsite evaluation. *Endosc Int Open* 2019;**7**:E189-E194.