

White globe appearance is an endoscopic predictive factor for synchronous multiple gastric cancer

Teppe Masunaga^a, Naohiro Yoshida^a, Shinichiro Akiyama^a, Gen Sugiyama^a, Hirokazu Hirai^a, Saori Miyajima^a, Shigenori Wakita^a, Yosuke Kito^a, Hiroyoshi Nakanishi^a, Kunihiro Tsuji^a, Kazuhiro Matsunaga^a, Shigetsugu Tsuji^a, Kenichi Takemura^a, Kazuyoshi Katayanagi^b, Hiroshi Minato^b, Hisashi Doyama^a

Ishikawa Prefectural Central Hospital, Ishikawa, Japan

Abstract

Background White globe appearance (WGA) is a small white lesion with a globular shape identified during magnifying endoscopy with narrow-band imaging. However, the association between WGA and synchronous multiple gastric cancer (SMGC) remains unclear.

Methods Consecutive patients who underwent endoscopic submucosal dissection for gastric cancer (GC) between July 2013 and April 2015 at our institution were eligible for this study. We excluded patients with a history of gastric tumor or gastrectomy. Patients who had more than 2 GCs in their postoperative pathological evaluation were classified as SMGC-positive, and patients who had at least 1 WGA-positive GC were classified as WGA-positive patients. The primary outcome was a comparison of the prevalence of WGA in patients classified as SMGC-positive and SMGC-negative. Univariate and multivariate analyses were performed using the following variables: WGA, age, sex, atrophy, and *Helicobacter pylori* (*H. pylori*) status.

Results There were 26 and 181 patients classified as SMGC-positive and SMGC-negative, respectively. Univariate analysis revealed that WGA-positive classification (50% vs. 23%, $P=0.008$) and male sex (88% vs. 66%, $P=0.02$) were significant factors associated with SMGC classification, while age ≥ 65 years (81% vs. 81%, $P>0.99$), severe atrophy (46% vs. 46%, $P>0.99$), and *H. pylori* positivity (69% vs. 65%, $P=0.8$) were not. In the multivariate analysis, only WGA-positive classification (odds ratio 2.78, 95% confidence interval 1.16-6.67; $P=0.02$) was a significant independent risk factor for SMGC.

Conclusions Our exploratory study showed the possibility of WGA as a predictive factor for SMGC. In cases of WGA-positive gastric cancer, careful examination might be needed to diagnose SMGC.

Keywords White globe appearance, gastric cancer, endoscopic submucosal dissection, synchronous multiple gastric cancer

Ann Gastroenterol 2021; 34 (1): 1-5

^aDepartment of Gastroenterology (Tepei Masunaga, Naohiro Yoshida, Shinichiro Akiyama, Gen Sugiyama, Hirokazu Hirai, Saori Miyajima, Shigenori Wakita, Yosuke Kito, Hiroyoshi Nakanishi, Kunihiro Tsuji, Kazuhiro Matsunaga, Shigetsugu Tsuji, Kenichi Takemura, Hisashi Doyama); ^bDepartment of Diagnostic Pathology (Kazuyoshi Katayanagi, Hiroshi Minato), Ishikawa Prefectural Central Hospital, Ishikawa, Japan

Conflict of Interest: None

Correspondence to: Naohiro Yoshida, Department of Gastroenterology, Ishikawa Prefectural Central Hospital, Ishikawa, Japan, e-mail: naohilow@yahoo.co.jp

Received 4 August 2020; accepted 16 September 2020; published online 7 December 2020

DOI: <https://doi.org/10.20524/aog.2020.0565>

Introduction

Endoscopic submucosal dissection (ESD) is currently widely performed for early gastric cancer (GC) without lymph node metastasis. The long-term outcomes of ESD are comparable to those of surgery for early GC [1]. ESD is a minimally invasive treatment and allows for most of the gastric mucosa to be preserved. However, there remains a risk of GC development and endoscopists must be careful regarding the presence of synchronous GC. According to previous studies, the incidence of synchronous multiple GC (SMGC) in patients who undergo endoscopic resection, including ESD, ranges from 5.8-20.1% [2-7]. In addition, 19% of patients with SMGC were not diagnosed before the initial ESD, which can be considered as a missed cancer diagnosis [2]. Missed SMGC

demands additional treatment, which imposes an economic burden. Therefore, it is important to detect SMGC when the initial GC is diagnosed; for that reason, clinically useful predictive factors for SMGC have been sought.

Several clinicopathological characteristics for multiple GC have been reported. Male sex and old age are risk factors for multiple GC [4,6,8-10]. Although severe atrophy, intestinal metaplasia, xanthoma, and low pepsinogen levels resulting from chronic gastritis have been reported as risk factors, *Helicobacter pylori* (*H. pylori*) status as another risk factor remains controversial [4,5,7,9,10]. Regarding the histological type, differentiated type has been identified as a risk factor for multiple GC [3,11].

On the other hand, white globe appearance (WGA) was previously reported as an endoscopic marker for GC. WGA is defined as a small white lesion with a globular shape (<1 mm) present underneath the gastric epithelium and identified during magnifying endoscopy with narrow-band imaging (M-NBI) examination (Fig. 1). It was correlated with the finding of intraglandular necrotic debris, defined as eosinophilic material with necrotic epithelial fragments within the lumen of a dilated gland [12-14]. However, no studies have examined the association of WGA with SMGC. The purpose of this exploratory study was to investigate the possibility of WGA as a predictive factor for SMGC.

Patients and methods

Study design

This retrospective observational study was conducted at the Ishikawa Prefectural Central Hospital, a tertiary referral

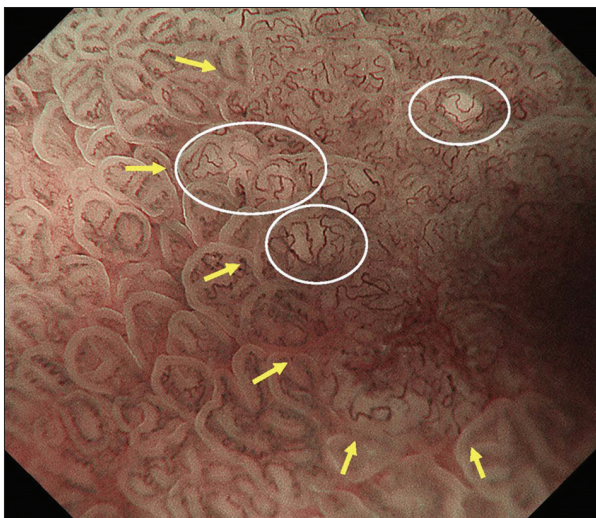


Figure 1 A representative endoscopic image of white globe appearance (WGA) using magnifying endoscopy with narrow-band imaging. Multiple small white lesions with globular shape classified as WGA (white circles) were present near the lesion demarcation line (yellow arrows). WGA intensified from the margins to the center and the lesion was overlaid by microvessels. This lesion was endoscopically resected and diagnosed as gastric cancer

center in Japan, in accordance with the Strengthening the Reporting of Observational Studies in Epidemiology (STROBE) guidelines [15], and the Declaration of Helsinki. The institutional review board of Ishikawa Prefectural Central Hospital approved this study.

Patients

Consecutive patients who had undergone ESD for GC between July 2013 and April 2015 at our institution were eligible for this study. The indications of ESD were as follows: differentiated intramucosal adenocarcinoma without ulceration regardless of size; differentiated intramucosal adenocarcinoma with ulceration ≤ 3 cm in size; and undifferentiated intramucosal adenocarcinoma without ulceration ≤ 2 cm in size. All the resected specimens were investigated histologically, and GC was confirmed. We excluded patients with a history of gastric tumor or gastrectomy.

Data evaluation

GC was defined as C4 (mucosal high-grade neoplasia) or C5 (submucosal invasion by carcinoma), according to the revised Vienna classification [16]. GC was macroscopically and histologically classified according to the Japanese Classification of Gastric Carcinoma [17]. If lesions had 2 or more components, the largest component was recorded. Patients who had more than 2 GCs in their postoperative pathological evaluation were classified as SMGC-positive. SMGC was also defined in accordance with Moertel's criteria as follows: each lesion must be of pathologically proved malignancy; all lesions must be clearly separated by intervals of microscopically normal gastric wall; the possibility that one of the lesions represents a local extension or metastatic tumor must be ruled out beyond any reasonable doubt [18].

The presence of WGA was determined retrospectively by M-NBI images, taken as a detailed examination for lesions treated by ESD. Lesions which had one or more WGA inside the GC demarcation line were classified as WGA-positive. For patients with multiple GCs, those with at least one WGA-positive GC were classified as WGA-positive patients. The M-NBI pictures used in this study were reviewed and the presence of WGA was determined by 2 endoscopists (HD and TM).

Severe atrophy was defined as O-II or O-III according to the Kimura-Takemoto classification system [19]. The status of *H. pylori* infection was evaluated by the rapid urease test, 13C urea breath test, histology, and serology. If any of the tests yielded a positive result, *H. pylori* infection was considered to be present.

Outcome measures

The primary outcome was a comparison of the prevalence of WGA in patients classified as SMGC-positive and

SMGC-negative. Univariate and multivariate analyses were performed using the following variables: WGA, age, sex, atrophy, and *H. pylori* status. We also investigated the characteristics of WGA-positive GC and the relevance to SMGC per GC.

Statistical analysis

Fisher's exact test was used to compare categorical variables. Risk factors for SMGC were examined by multivariate analysis using a logistic regression model. Differences with $P < 0.05$ were considered statistically significant. All statistical analyses were performed using EZR (Saitama Medical Center, Jichi Medical University, Saitama, Japan), a graphical user interface for R (The R Foundation for Statistical Computing, Vienna, Austria). More specifically, it is a modified version of R commander designed to add statistical functions frequently used in biostatistics [20].

Results

Among the 264 patients who underwent ESD for GC between July 2013 and April 2015, 14 patients with a history of gastrectomy and 43 with a history of GC were excluded. Consequently, a total of 207 patients with 244 GCs were analyzed (Fig. 2). The median age was 71 years (range 40-91).

There were 26 patients classified as SMGC-positive of whom 16 had double cancer, 9 triple cancer, and 1 patient quadruple cancer.

There were 55 WGA-positive patients with 64 WGA-positive GCs, corresponding to a prevalence of 26% (64/244). Table 1 shows the clinical characteristics of the WGA-positive patients and GC. Of these patients 85% were male (47/55). The macroscopic type was 0-IIc in 77% of lesions (49/64) and the location was the middle third in 62% of lesions (40/64). Regarding the histological type, 95% of lesions (61/64) were well-to-moderately differentiated tubular adenocarcinoma. One lesion was a poorly differentiated adenocarcinoma and 1 was a signet-ring cell carcinoma; this lesion contained components of a moderately differentiated tubular adenocarcinoma. One lesion was signet-ring cell carcinoma without other components.

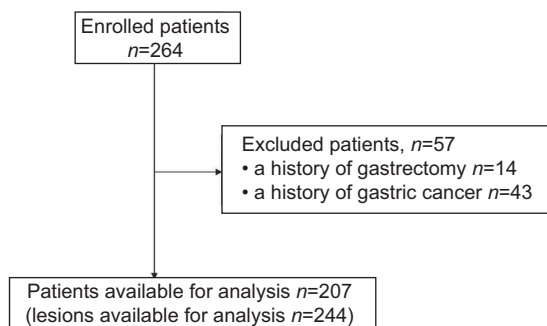


Figure 2 Flowchart of enrolled patients

Table 2 shows a comparison of clinical characteristics between SMGC-positive and SMGC-negative. The prevalence of male patients was significantly higher in the SMGC-positive group than in the SMGC-negative group (23/26[88%] vs. 120/181[66%], $P=0.02$). In addition, WGA positivity was significantly higher in patients classified as SMGC-positive than in patients classified as SMGC-negative (13/26[50%] vs. 42/181[23%], $P=0.008$). Table 3 shows the SMGC multivariate analysis outcomes. Only WGA positivity (odds ratio 2.78, 95% confidence interval 1.16-6.67; $P=0.02$) was found to be significant independent risk factors for SMGC.

Among the 13 patients classified as WGA-positive and SMGC-positive, 9 patients had double cancer (2 patients had 2

Table 1 Clinical characteristics of 55 WGA-positive patients and 64 WGA-positive gastric cancers

Characteristics	Value
Sex, number (%)	
Male	47 (85)
Female	8 (15)
Age, years, median (range)	71 (50-88)
Tumor size in mm, median (range)	13 (3-36)
Macroscopic type, number (%)	
0-I	0 (0)
0-IIa	11 (17)
0-IIb	4 (6)
0-IIc	49 (77)
0-III	0 (0)
Location, number (%)	
Upper third	14 (22)
Middle third	40 (62)
Lower third	10 (16)
Type of ulceration, number (%)	
Open	2 (3)
Scar	1 (2)
None	61 (95)
Histological type, number (%)	
HGA	0 (0)
tub1	47 (73)
tub2	14 (22)
sig	2 (3)
por	1 (2)
Tumor depth, number (%)	
T1a (mucosa)	55 (86)
T1b (submucosa)	9 (14)

HGA, high-grade adenoma; por, poorly differentiated adenocarcinoma; sig, signet-ring cell carcinoma; tub1, well-differentiated tubular adenocarcinoma; tub2, moderately differentiated tubular adenocarcinoma; WGA, white globe appearance

Table 2 Comparison of clinical characteristics between SMGC-positive and SMGC-negative

Characteristics	Total	SMGC (+)	SMGC (-)	OR (95%CI)	P-value
	(n=207)	(n=26)	(n=181)		
Age ≥65 years, n (%)	167 (81)	21 (81)	146 (81)	1.35 (0.34-3.66)	>0.99
Male, n (%)	143 (69)	23 (88)	120 (66)	3.88 (1.11-20.96)	0.02
Severe atrophy, n (%)	96 (46)	12 (46)	84 (46)	0.99 (0.39-2.45)	>0.99
<i>H. pylori</i> infection, n (%)	135 (65)	18 (69)	117 (65)	1.23 (0.48-3.46)	0.8
WGA positive, n (%)	55 (27)	13 (50)	42 (23)	3.29 (1.29-8.37)	0.008

SMGC, synchronous multiple gastric cancer; WGA, white globe appearance; OR, odds ratio; CI, confidence interval; *H. pylori*, *Helicobacter pylori*

Table 3 Multivariate analysis for SMGC

Characteristics	OR (95%CI)	P-value
Age ≥65 years	1.19 (0.40-3.55)	0.76
Male sex	3.21 (0.90-11.5)	0.07
Severe atrophy	0.87 (0.37-2.06)	0.75
<i>H. pylori</i> infection	1.29 (0.51-3.25)	0.60
WGA positive	2.78 (1.16-6.67)	0.02

SMGC, synchronous multiple gastric cancer; WGA, white globe appearance; OR, odds ratio; CI, confidence interval; *H. pylori*, *Helicobacter pylori*

lesions with WGA, while 7 patients had 1 lesion with WGA and another without WGA), 4 patients had triple cancer (3 patients had all 3 lesions with WGA, while 1 patient had 2 lesions with WGA and another without WGA). Among the 7 patients with double cancer who had only one lesion with WGA, 5 patients had WGA in the larger lesion. In the lesion-based viewpoint, the proportion of GCs with WGA in SMGC-positive was 35% (22/63) and that of GCs with WGA in SMGC-negative was 23% (42/181; $P=0.095$).

Discussion

Our exploratory study showed the possibility of WGA as a predictive factor for SMGC. In addition to the result of the primary endpoint, the result of the lesion-based analysis, which showed that the tendency for the proportion of GCs with WGA in SMGC-positive to be higher than that in SMGC-negative, was considered to support the suggestion that WGA could be an independent risk factor for SMGC. WGA has been found to have high specificity for diagnosing GC [13]. Although further confirmatory studies are necessary, the results of this study could enhance the clinical significance of WGA.

It has been speculated that WGA may correspond to the endoscopic visualization of the apoptotic-necrotic phenomenon [12]. We hypothesized that this phenomenon may be related to carcinogenesis. However, why WGA, a lesion feature, can predict SMGC in the whole stomach was unclear. More studies of the molecular biological evaluation of WGA lesions are still needed.

Accurate detection of SMGC before treatment including ESD is important. Endoscopic examination should be performed without overlooking SMGC, since missed SMGC usually increases the financial burden imposed on patients and institutions because of the need for additional treatment and re-admission. Previous reports showed that 19-32% of SMGC cases were missed [2,21]. Considering that missed GCs tend to occur when esophagogastroduodenoscopy is not performed sufficiently thoroughly [22], it is recommended that enough time is taken to observe the stomach of patients with risk factors for SMGC to reduce the number of missed SMGC.

WGA detection is easy and highly reproducible [23]. WGA may be identified using M-NBI, but occasionally also using conventional white-light endoscopy. In addition, the largest SMGC lesions, which should be easily detected, tended to show WGA in the present study. Thus, WGA could be a clinically useful predictive marker for SMGC. Previous reports showed that male sex and old age are risk factors for multiple GC [4,6,8-10]. In the present multivariate analysis, male sex and older age were not significant independent risk factors for SMGC. Severe atrophy, intestinal metaplasia, xanthoma, and low pepsinogen levels related to chronic gastritis were previously found to be risk factors for multiple GC [4,5,7,9,10]. Although we evaluated the relationship between SMGC and atrophy in this study, these 2 features were not associated. Whether *H. pylori* status was associated with multiple GC remains controversial [4,5,7,9,10]. The present study found that *H. pylori* status was not related to SMGC.

In this study, the prevalence of WGA was 26%. This result was similar to previous reports that showed that WGA was present in approximately 21% of GCs [12,13]. WGA implies the presence of a glandular structure. In other words, when a GC has WGA, it includes components of well-to-moderately differentiated tubular adenocarcinoma. Accordingly, 98% (63/64) of WGA-positive GCs had such components in the present study.

The study had some limitations. First, the number of patients enrolled in this exploratory study was not enough to ensure the clinical usefulness of WGA. Second, this exploratory study might have overestimated the odds ratio of WGA-positive in SMGC-positive; verification by a prospective study is required. Third, we only enrolled patients with an indication for ESD for GC. Thus, there was a selection bias in this study. Advanced cancer, deep submucosal invasive cancer, and undifferentiated

type cancer therefore tended to be excluded. Fourth, we did not analyze the presence of metachronous cancer. Additional studies including long-term clinical outcomes are needed. Finally, because we examined the factors related to SMGC according to patient features, we could not evaluate the relationship between SMGC and GC characteristics.

In summary, we identified a possibility that patients with WGA-positive GC tended to have SMGC and that WGA was an independent risk factor for SMGC. In cases of WGA-positive GC, more careful examination might be needed to avoid missing SMGC.

Summary Box

What is already known:

- It is important not to overlook synchronous multiple gastric cancer (SMGC) when the initial gastric cancer (GC) is diagnosed
- White globe appearance (WGA) is an endoscopic marker with high specificity for diagnosing GC

What the new findings are:

- WGA could be a predictive factor for SMGC
- In cases of WGA-positive GC, more careful examination might be needed

References

1. Kim YL, Kim YW, Choi JJ, et al. Long-term survival after endoscopic resection versus surgery in early gastric cancers. *Endoscopy* 2015;**47**:293-301.
2. Kato M, Nishida T, Yamamoto K, et al. Scheduled endoscopic surveillance controls secondary cancer after curative endoscopic resection for early gastric cancer: a multicentre retrospective cohort study by Osaka University ESD study group. *Gut* 2013;**62**:1425-1432.
3. Nasu J, Doi T, Endo H, Nishina T, Hirasaki S, Hyodo I. Characteristics of metachronous multiple early gastric cancers after endoscopic mucosal resection. *Endoscopy* 2005;**37**:990-993.
4. Jang MY, Cho JW, Oh WG, et al. Clinicopathological characteristics of synchronous and metachronous gastric neoplasms after endoscopic submucosal dissection. *Korean J Intern Med* 2013;**28**:687-693.
5. Lim JH, Kim SG, Choi J, Im JP, Kim JS, Jung HC et al. Risk factors for synchronous or metachronous tumor development after endoscopic resection of gastric neoplasms. *Gastric Cancer* 2015;**18**:817-823.
6. Lee HJ, Lee YJ, Lee JY, et al. Characteristics of synchronous and metachronous multiple gastric tumors after endoscopic submucosal dissection of early gastric neoplasm. *Clin Endosc* 2018;**51**:266-273.
7. Park SY, Lim SO, Ki HS, et al. Low pepsinogen I level predicts multiple gastric epithelial neoplasias for endoscopic resection. *Gut Liver* 2014;**8**:277-281.
8. Jeong SH, An J, Kwon KA, et al. Predictive risk factors associated with synchronous multiple early gastric cancer. *Medicine (Baltimore)* 2017;**96**:e7088.
9. Nitta T, Egashira Y, Akutagawa H, et al. Study of clinicopathological factors associated with the occurrence of synchronous multiple gastric carcinomas. *Gastric Cancer* 2009;**12**:23-30.
10. Shibukawa N, Ouchi S, Wakamatsu S, Wakahara Y, Kaneko A. Gastric xanthoma is a predictive marker for metachronous and synchronous gastric cancer. *World J Gastrointest Oncol* 2017;**9**:327-332.
11. Park CH, Kim EH, Kang JH, et al. Low incidence of synchronous or metachronous tumors after endoscopic submucosal dissection for early gastric cancer with undifferentiated histology. *PLoS One* 2016;**11**:e0147874.
12. Doyama H, Yoshida N, Tsuyama S, et al. The “white globe appearance” (WGA): a novel marker for a correct diagnosis of early gastric cancer by magnifying endoscopy with narrow-band imaging (M-NBI). *Endosc Int Open* 2015;**3**:E120-E124.
13. Yoshida N, Doyama H, Nakanishi H, et al. White globe appearance is a novel specific endoscopic marker for gastric cancer: A prospective study. *Dig Endosc* 2016;**28**:59-66.
14. Watanabe Y, Shimizu M, Itoh T, Nagashima K. Intraglandular necrotic debris in gastric biopsy and surgical specimens. *Ann Diagn Pathol* 2001;**5**:141-147.
15. von Elm E, Altman DG, Egger M, Pocock SJ, Gøtzsche PC, Vandenbroucke JP; STROBE Initiative. Strengthening the reporting of observational studies in epidemiology (STROBE) statement: guidelines for reporting observational studies. *BMJ* 2007;**335**:806-808.
16. Dixon MF. Gastrointestinal epithelial neoplasia: Vienna revisited. *Gut* 2002;**51**:130-131.
17. Japanese Gastric Cancer Association. Japanese classification of gastric carcinoma: 3rd English edition. *Gastric Cancer* 2011;**14**:101-112.
18. Moertel CG, Barga JA, Soule EH. Multiple gastric cancers; review of the literature and study of 42 cases. *Gastroenterology* 1957;**32**:1095-1103.
19. Kimura K, Takemoto T. An endoscopic recognition of the atrophic border and its significance in chronic gastritis. *Endoscopy* 1969;**1**:87-97.
20. Kanda Y. Investigation of the freely available easy-to-use software ‘EZ’ for medical statistics. *Bone Marrow Transplant* 2013;**48**:452-458.
21. Pimenta-Melo AR, Monteiro-Soares M, Libânio D, Dinis-Ribeiro M. Missing rate for gastric cancer during upper gastrointestinal endoscopy: a systematic review and meta-analysis. *Eur J Gastroenterol Hepatol* 2016;**28**:1041-1049.
22. Kawamura T, Wada H, Sakiyama N, et al. Examination time as a quality indicator of screening upper gastrointestinal endoscopy for asymptomatic examinees. *Dig Endosc* 2017;**29**:569-575.
23. Omura H, Yoshida N, Hayashi T, et al. Interobserver agreement in detection of “white globe appearance” and the ability of educational lectures to improve the diagnosis of gastric lesions. *Gastric Cancer* 2017;**20**:620-628.