

Anal self-massage in the treatment of acute anal fissure: a randomized prospective study

Fabio Gaj^a, Ivano Biviano^b, Laura Candeloro^b, Jacopo Andreuccetti^c

Umberto I Policlinic of Rome, Sapienza University, Rome; San Camillo Hospital, Trento, Italy

Abstract

Background An anal fissure (AF) is a tear in the epithelial lining of the anal canal. This is a very common condition, but the choice of treatment is unclear. The use of anal dilators is effective, economic, and safe. The aim of the study was to compare the efficacy of two conservative treatments, the use of anal dilators or a finger for anal dilatation, in reducing anal pressure and resolving anal fissures.

Methods Fifty patients with a clinical diagnosis of AF were randomly assigned to one of the treatments, self-massage of the anal sphincter (group A, 25 patients) or passive dilatation using dilators (group B, 25 patients). All patients were evaluated at baseline, at the end of treatment, and after 12 weeks and 6 months. Pain was measured using a visual analog scale.

Results After the treatment, 60% of patients treated with dilators and 80% of patients treated with anal self-massage using a finger showed disappearance of their anal fissures. A comparison between signs and symptoms reported by the patients in the two groups showed a statistically significant reduction in anal pain (group A, $P=0.0001$; group B, $P=0.0001$) and bleeding after defecation (group A, $P=0.001$, group B, $P=0.001$). At 6 months after treatment, a significantly greater reduction in anal pain was observed in Group A compared to Group B ($P=0.02$).

Conclusion The use of anal self-massage with a finger appears to induce a better resolution of acute anal fissure than do anal dilators, and in a shorter time.

Keywords Anal fissure, anal massage, anal dilator, proctologic disease, anal pain

Ann Gastroenterol 2017; 30 (4): 1-4

Introduction

The anal fissure is an extremely common proctologic disease, but the choice of the most appropriate therapy is still difficult. Because of the high rate of recurrence that afflicts conservative therapy and the risk of serious complications, such as bowel incontinence and bleeding that can affect surgical therapy, it is not yet possible to determine which the best treatment is.

The conservative treatment of anal fissure relies on the observation of hygienic-dietary measures, obtaining a

regular bowel movement, and the use of muscle relaxants or anesthetics. This approach is effective in 50% of patients in the short term [1]; the recurrence rate ranges from 18% to 27% at 5 years [2,3]. The use of nitroglycerine creams or botulinum toxin appears to be a palliative treatment, with rapid loss of effectiveness, and it is often poorly tolerated because of unpleasant side effects [4-8]. In the past, in our prospective randomized trial [9], passive anal dilatation was effective in inducing remission within 4 weeks in 80% of patients. However, two retrospective studies showed a recurrence rate of 50% [10,11] and a rather long time of therapy (about 30 days), often poorly tolerated by patients. Therefore, our group has developed a new therapeutic approach that involves anal self-massage by the patient. The purpose of this study was to evaluate the effectiveness of anal self-massage in the treatment of anal fissure, comparing it to traditional therapy with dilators.

^aDepartment of General Surgery and Organ Transplant, Umberto I Policlinic of Rome, Sapienza University, Rome (Fabio Gaj);

^bDepartment of Medicine and Medical Specialties, Umberto I Policlinic of Rome, Sapienza University of Rome (Ivano Biviano, Laura Candeloro); ^cGeneral and Mini-Invasive Surgery, "San Camillo" Hospital, Trento (Jacopo Andreuccetti), Italy

Conflict of Interest: None

Correspondence to: Ivano Biviano, MD, Department of Medicine and Medical Specialties, Policlinico Umberto I, Sapienza University of Rome, 00161 Italy, Tel.: +39 064 997 8384, e-mail: ivano.biviano@uniroma1.it

Received 17 January 2017; accepted 06 April 2017; published online 10 May 2017

DOI: <https://doi.org/10.20524/aog.2017.0154>

Patients and methods

Fifty patients suffering from acute anal fissure were enrolled in this prospective randomized study. Patients were referred to the pelvic floor unit of the Policlinico Umberto I Hospital and to the Jewish Hospital in Rome between June 2012 and June

2014. All patients agreed to be included in the study and gave their signed, informed consent to randomization. Inclusion criteria were age ranging from 18 to 70 years, presence of anal pain during bowel movements, detection of acute posterior anal fissure. The fissure was defined as “acute” in the case of an ulceration that developed within one month in the anoderm, without the typical signs of chronic fissure (presence of sentinel tag, fibrous induration of the side edges, and exposure of the fibers of the internal anal sphincter) [12]. Exclusion criteria were concomitant anal pathology (anorectal fistulae, abscesses), previous surgery on the pelvic floor, inflammatory bowel disease, and therapy with nitrates.

The patients were randomized using a number table to treatment with self-massage of the anal sphincter (group A, 25 patients) or passive dilatation of the anal sphincter using dilators (group B, 25 patients). The anal self-massage consisted in the introduction of the patient's own index finger into the anal canal (with lubricant cream) for 10 min twice a day for the first 2 days of treatment (Fig. 1); the patient was then instructed to perform a circular motion with the finger for 10 min twice a day for a further 5 days (Fig. 2). The passive anal dilatation was performed using a 20 mm Dilatan® dilator (Enterprises Sapimed, Alessandria) twice a day for at least 10 min for 5 days, and subsequently with a 23 mm Dilatan®, twice a day for at least 10 min for 5 days. Finally a 27 mm Dilatan® was used twice a day for at least 10 min for 20 days. To facilitate the introduction of the Dilatan®, patients used the same lubricant cream used by the patients in Group A.

Patients were evaluated before treatment by digital rectal examination performed with the patient in the left lateral position (at rest and during different times of functional decline and straining). Patients were also administered a personal questionnaire about their quality of life (analyzing the results according to the Agachan-Wexner score) [13]. The intensity of pain was assessed by visual analog scale (VAS).

At the end of treatment, all patients underwent a clinical reevaluation (physical examination, rectal examination) and interviews with a standardized questionnaire regarding medical history, information on symptoms such as itching, anal pain, anal burning, bleeding, quality of life, and the VAS scale for pain. Follow up was scheduled at the end of the treatment and at 3 and 6 months. During follow up, the following variables were taken into account: anal fissure epithelialization, pain, bleeding, side effects, quality of life and recurrence at 6 months. Treatment success was defined as complete healing of the anal fissure or partial epithelialization associated with at least a 50% reduction in pain score at the end of treatment.

Statistical analysis

The collected data were stored on a floppy disk by creating a database using the Excel® program (Microsoft Office). Descriptive continuous variables are expressed as mean and standard deviation (SD). Comparisons between groups were performed, according to the distribution of the patients, using the Fisher test (χ^2) for dichotomous variables, considering a P-value ≤ 0.05 as the limit for statistical significance.

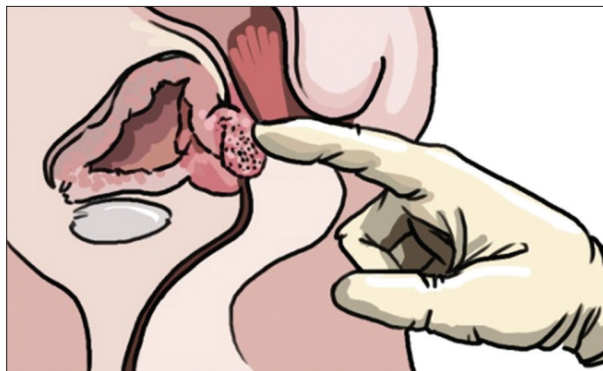


Figure 1 Introduction of the patient's own index finger into the anal canal for 10 min twice a day for the first 2 days

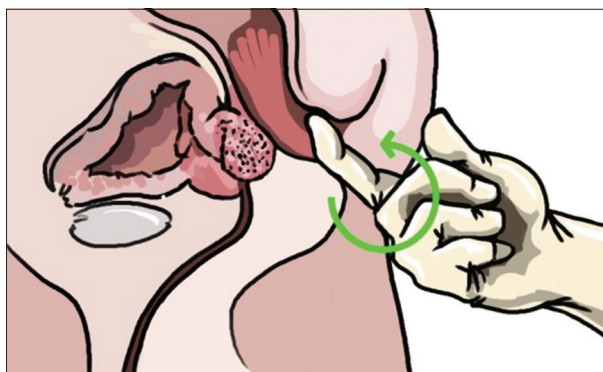


Figure 2 Circular motion of the finger for 10 min twice a day for a further 5 days

Results

Of the 50 patients enrolled, 27 were women and 23 men, with a mean age of 38.6 ± 12.3 years (range 18-56). All patients had an acute posterior anal fissure. The most frequent signs and symptoms were anal pain (50 patients, 100%), with an average intensity of 8 on a VAS scale from 0 (no pain) to 10 (maximum pain bearable); bleeding during defecation (42 patients, 84%), anal itching (10 patients, 20%) and anal burning (16 patients, 32%). Bowel movements were normal in 34 patients, 12 patients complained of constipation and 4 reported diarrhea. There were no side effects in any of the two groups. The analysis of the questionnaire on quality of life showed an average of 6 on a scale of 0-10. Table 1 summarizes the characteristics of patients and the symptoms and signs before treatment.

At the end of the treatment, 20 patients in group A (anal self-massage) and 15 in group B showed resolution of symptoms and disappearance of the anal fissure. At 3 months after the end of treatment, no patient in group A had recurrence of the disease, whereas 2 relapses were observed in group B. The subsequent evaluation was at 6 months. Recurrence was observed in one patient in group A and in 3 patients in group B.

The average quality of life was similar, being 9 in group A and 8 in group B. Table 2 summarizes the characteristics of patients and symptoms after treatment, and at 3 and 6 months after the procedure.

Comparison between the signs and symptoms reported by the patients in the two groups before treatment, at the end, at 3 and 6 months, showed a statistically significant reduction in anal pain (group A, $P=0.0001$; group B, $P=0.0001$) and bleeding after defecation (group A, $P=0.001$, group B, $P=0.001$); anal itching (group A, $P=0.3$; group B, $P=0.7$) and anal burning (group A, $P=0.1$; group B, $P=0.5$) decreased in both groups, but the reduction observed was not statistically significant. The analysis of the VAS score showed a progressive decrease during the follow up, but there were no significant differences in the two groups. At 6 months after treatment, a significant difference in terms of reduction in anal pain was observed between the two groups (A vs. B, $P=0.02$). There was no significant difference in the other symptoms.

Discussion

The anal fissure is a longitudinal lesion of the skin of the anal canal, located at the back of the anal sphincter in 90% of cases. The cause of this disease still remains unclear, although it is considered that an increase in the internal anal sphincter tone may lead to a local reduction in the blood flow, causing damage especially posteriorly, where the perfusion is physiologically lower than in the other areas of the anal canal. From this perspective, the anal fissure can be regarded as an ischemic disease [14-16]. Hard stools can be the primary cause of this

complex background. Therefore, a first therapeutic approach is habit regularization, especially as a preventive maneuver. Once, however, the anal fissure has presented, the choice of therapy to be implemented cannot be simple: noninvasive treatment, represented by the use of nitroglycerin-based creams or calcium channel antagonists, is often burdened with side-effects such as headache. Moreover, the long-term efficacy of these medical treatment has not been proven [17-20].

Regarding the use of botulinum toxin, a still expensive approach, the dose and the site of injection have still to be defined clearly, and its long-term efficacy is not supported by clinical evidence [21]. Lateral internal sphincterotomy, although ensuring the best results, with a rate of long-term success above 90%, presents the non-negligible risk of fecal incontinence [22,23]. For this reason, a few years ago our team developed a noninvasive treatment for anal fissure that provided for the passive and progressive dilatation of the anal canal using dilators, achieving a success rate of 90% at the end of treatment and of 80% at 12 weeks compared with topical nitroderivatives, but in a smaller sample [9].

However, this method required a long application time and duration of treatment for effective results. To overcome these limitations, we developed a new therapeutic approach: anal self-massage performed by the patient. Our study showed that this treatment presents a success rate of 80%, with a recurrence rate of 5% at 6 months, whereas treatment with anal dilators presented a success rate of 44%, with a recurrence rate of 56%. These results show the long-term superiority in the effectiveness of the massage method. At the end of both treatments, we obtained a statistically significant reduction in anal pain and bleeding, though the reduction in anal itching and burning did not reach statistical significance. It is possible that anal itching and anal burning are less specific symptoms of anal fissure and represent accompanying symptoms, especially due to the presence of hemorrhoids. This new approach represents an evolution of anal dilators. The success rates are higher and the rate of recurrence is lower compared with anal dilator therapy. In addition, the duration of the therapy is drastically reduced: 7 days versus 30. Through anal self-massage, the patient modulates the action of dilating, making the therapy more effective and performing real biofeedback compared to therapy with anal dilators. This approach also has a significantly lower cost.

Our hypothesis is that the massage of the anal sphincter, in addition to the passive dilatation obtained by the finger,

Table 1 Patient characteristics

Characteristics	Patients (%)		
Age (Mean±SD, range)	38.6±12.3 (18-56)		
Sex (%)			
Female	27 (64)		
Male	23 (36)		
Clinical presentation (%)	Group A	Group B	Total
Anal pain	25 (100)	25 (100)	50 (100)
Bleeding during defecation	22 (88)	20 (80)	42 (84)
Anal itching	4 (16)	6 (24)	10 (20)
Anal burning	7 (28)	9 (36)	16 (32)

Table 2 Signs and symptoms of patients at the end of their treatment, and at 3 and 6 months after treatment

Signs and symptoms	At the end of treatment n (%)		P	At 3 months n (%)		P	At 6 months n (%)		P
	Group A	Group B		Group A	Group B		Group A	Group B	
Anal pain	4 (16)	11 (44)	NS	5 (20)	12 (48)	NS	5 (20)	14 (56)	0.02
Bleeding	3 (12)	7 (28)	NS	3 (12)	7 (28)	NS	3 (12)	8 (28)	NS
Anal itching	1 (4)	4 (16)	NS	2 (8)	5 (20)	NS	2 (8)	5 (20)	NS
Anal burning	2 (8)	6 (24)	NS	2 (8)	6 (24)	NS	2 (8)	8 (32)	NS

Summary Box

What is already known:

- The widely held belief is that internal anal sphincter hypertonicity is a determining factor in the development of an anal fissure
- Surgical interventions have had consistently higher success rates (approximately 89%) than any form of medical therapy, but are expensive and have a substantial risk of long-term anal incontinence
- The use of anal dilators is effective, economic, and safe
- Uncontrolled anal dilatation is not recommended because of the risk of anal incontinence

What the new findings are:

- Anal self-massage can be an effective treatment in the management of acute anal fissure
- The method is cheap, provides a simple solution to the problem, and offers higher success rates than conventional dilators, without the risk of anal continence

induces a relaxation of the hypertrophic and hyper-contracted anal sphincter, through a negative central feedback mechanism. From this perspective, the tactile sensitivity of the finger would have a key role.

However, the sample of the population analyzed in this study do not fully describe the applicability of the method. In fact, all randomized patients of the study could have performed anal self-massage, but problems could arise in some patients, such as the frail elderly, morbidly obese, or those with functional limitations (neurological diseases, orthopedic diseases, muscular diseases, etc.).

Another consideration is that cultural differences make it impossible to apply the method in certain socio-cultural contexts. In these patients this method should not be proposed because of poor compliance.

In conclusion, in our study, both treatments, anal self-massage and anal dilators, were equally effective in inducing and maintaining remission of anal fissure. However, anal self-massage involves lower treatment times and costs. To the best of our knowledge, this is the first study in the literature to describe and compare these techniques for the treatment of anal fissure.

References

1. Lund JN, Scholefield JH. Aetiology and treatment of anal fissure. *Br J Surg* 1996;**83**:335-344.

2. Shub HA, Salvati EP, Rubin RJ. Conservative treatment of anal fissure: an unselected, retrospective and continuous study. *Dis Colon Rectum* 1978;**21**:582-583.

3. Hananel N, Gordon PH. Re-examination of clinical manifestations and response to therapy of fissure-in-ano. *Dis Colon Rectum* 1997;**40**:229-233.

4. Altomare DF, Rinaldi M, Milito G, et al. Glyceryl trinitrate for chronic anal fissure—healing or headache? Results of a multicenter, randomized, placebo-controlled, double-blind trial. *Dis Colon Rectum* 2000;**43**:174-179.

5. American Gastroenterological Association. American Gastroenterological Association medical position statement: Diagnosis and care of patients with anal fissure. *Gastroenterology* 2003;**124**:233-234.

6. Bacher H, Mischinger HJ, Werkgartner G, et al. Local nitroglycerin for treatment of anal fissures: an alternative to lateral sphincterotomy? *Dis Colon Rectum* 1997;**40**:840-845.

7. Carapeti EA, Kamm MA, McDonald PJ, Chadwick SJ, Melville D, Phillips RK. Randomised controlled trial shows that glyceryl trinitrate heals anal fissures, higher doses are not more effective, and there is a high recurrence rate. *Gut* 1999;**44**:727-730.

8. Hyman NH, Cataldo PA. Nitroglycerin ointment for anal fissures: effective treatment or just a headache? *Dis Colon Rectum* 1999;**42**:383-385.

9. Gaj F, Trecca A, Crispino P. Efficacy of anal dilators in the treatment of acute anal fissure. A controlled clinical trial. *Chir Ital* 2006;**58**:761-765.

10. Fries B, Rietz KA. Treatment of fissure in ano. *Acta Chir Scandinavica* 1964;**128**:312-315

11. Giovaninetti GD, Manzi M, Marchi L, et al. Use of anal dilators in the conservative therapy of anal rhagades. *Chir Ital* 1986;**38**:666-670.

12. Higuero T. Update on the management of anal fissure. *J Visc Surg* 2015;**152**:S37-S43.

13. Agachan F, Chen T, Pfeifer J, Reissman P, Wexner SD. A constipation scoring system to simplify evaluation and management of constipated patients. *Dis Colon Rectum* 1996;**39**:681-685.

14. Perry GG. Fissure in ano—a complication of anusitis. *South Med J* 1962;**55**:955-957.

15. Nothmann BJ, Schuster MM. Internal anal sphincter derangement with anal fissures. *Gastroenterology* 1974;**67**:216-220.

16. Klosterhalfen B, Vogel P, Rixen H, Mittermayer C. Topography of the inferior rectal artery: a possible cause of chronic, primary anal fissure. *Dis Colon Rectum* 1989;**32**:43-52.

17. Schouten WR, Briel JW, Auwerda JJ, De Graaf EJ. Ischaemic nature of anal fissure. *Br J Surg* 1996;**83**:63-65.

18. Nelson RL, Thomas K, Morgan J, Jones A. Non surgical therapy for anal fissure. *Cochrane Database Syst Rev* 2012;**(2)**:CD003431.

19. Lund JN, Scholefield JH. A randomised, prospective, double-blind, placebo-controlled trial of glyceryl trinitrate ointment in treatment of anal fissure. *Lancet* 1997;**349**:11-14.

20. Chrysos E, Xynos E, Tzovaras G, Zoras OJ, Tsiaoussis J, Vassilakis SJ. Effect of nifedipine on rectoanal motility. *Dis Colon Rectum* 1996;**39**:212-216.

21. Kocher HM, Steward M, Leather AJ, Cullen PT. Randomized clinical trial assessing the side-effects of glyceryl trinitrate and diltiazem hydrochloride in the treatment of chronic anal fissure. *Br J Surg* 2002;**89**:413-417.

22. Gui D, Cassetta E, Anastasio G, Bentivoglio AR, Maria G, Albanese A. Botulinum toxin for chronic anal fissure. *Lancet* 1994;**344**:1127-1128.

23. Nelson RL. Operative procedures for fissure in ano. *Cochrane Database Syst Rev* 2010;**(1)**:CD002199.