

Tubercular versus Crohn's ileal strictures: role of endoscopic balloon dilatation without fluoroscopy

Surinder Singh Rana, Deepak Kumar Bhasin, Chalapathi Rao, Kartar Singh

Post Graduate Institute of Medical Education and Research (PGIMER), Chandigarh, India

Abstract

Background Benign ileal strictures can cause considerable morbidity and they have been conventionally treated with surgery. The aim of this study was to report our experience of endoscopic balloon dilatation (EBD) in patients with terminal ileal strictures because of Crohn's disease and tuberculosis.

Methods Over the last 8 years, 9 patients (6 males; mean age 39.7 ± 13.2 years) with benign terminal ileal strictures were treated by EBD using a colonoscope and through-the-scope controlled radial expansion balloon dilators.

Results The etiology of benign ileal stricture was Crohn's disease in 5 and tuberculosis in 4 patients. All the patients with Crohn's disease had no or partial response to 4 weeks of steroid therapy and there were no mucosal ulcerations on ileoscopy. Three patients with ileal strictures due to tuberculosis underwent dilatation after completion of the antitubercular therapy (ATT) while one patient required dilatation 3 months after starting ATT. All patients had single ileal stricture with length of stricture ranging from 0.6-1.8 cm. EBD was successful in all 9 patients with a median number of dilating sessions required of 2 (range: 1-5 sessions). Patients with Crohn's disease required more endoscopic sessions as compared to patients with tuberculosis but this difference was not statistically significant (mean number of session being 3.0 ± 1.58 vs. 1.75 ± 0.5 sessions respectively; $p=0.1$). One patient with ileal tuberculosis had enterolith proximal to the stricture that could be removed with dormia. There were no complications of the endoscopic procedure.

Conclusions EBD is an effective, safe, and minimally invasive treatment modality for benign ileal strictures.

Keywords Tuberculosis, Crohn's disease, balloon dilatation, steroids, enterocolitis

Ann Gastroenterol 2013; 26 (1): 1-5

Introduction

Strictures of the small bowel can be caused by various benign and malignant causes. The benign causes of small bowel strictures include inflammatory, ischemic and post-radiation strictures and the common inflammatory causes are Crohn's disease and intestinal tuberculosis [1]. Medical therapy including steroids can help improve the symptoms in inflammatory strictures by decreasing the inflammation,

but is not effective in patients with scarred fibrosed strictures. These scarred strictures have been conventionally treated by surgery [2]. However, surgery is associated with morbidity and the majority of patients with Crohn's disease will require repeat operation owing to recurrence of strictures [2].

The advent of endoscopic balloon dilatation (EBD) ushered in an era of nonsurgical management of benign strictures in the upper gastrointestinal tract and studies done over the last two decades have confirmed the safety and efficacy of EBD in various benign upper gastrointestinal strictures [3-5]. EBD has also been used for treatment of ileal, colonic and anastomotic strictures because of Crohn's disease, however experience is limited [6-8]. Likewise, experience with EBD for benign ileocolonic strictures due to tuberculosis is limited to case reports [9,10], and in addition EBD for ileocolonic strictures is done under combined endoscopic and radiological guidance. We describe our experience of EBD performed only under endoscopic guidance without the use of fluoroscopy in 9 patients with terminal ileal strictures because of various benign etiologies.

Department of Gastroenterology, Post Graduate Institute of Medical Education and Research (PGIMER), Chandigarh, India

Conflict of Interest: None

Correspondence to: Dr Surinder S Rana, Department of Gastroenterology, PGIMER, Chandigarh, 160012 India, Tel.: +91 172 2749123, Fax: +91 172 2744401, e-mail: drsurinderrana@yahoo.co.in, drsurinderrana@gmail.com

Received 8 October 2012; accepted 8 November 2012

Materials and methods

We retrospectively analyzed data from nine consecutive patients with terminal benign ileal strictures who were referred to us over an 8-year period and were treated with EBD. All the patients during this study period were offered endoscopic dilatation as the first-line therapy. All patients had obstructive symptoms especially recurrent colicky abdominal pain refractory to medical treatment [steroids in patients with Crohn's disease and at least one month of anti-tubercular therapy (ATT) in patients with ileal tuberculosis]. All these patients had documented terminal ileal stricture less than 5 cm in length with no intestinal fistula on barium examination. The etiology of ileal stricture was determined by the results of a combination of clinical, endoscopic, histopathological and microbiological tests. An informed consent was obtained from all the patients. A detailed history was taken from the patients as well as their attendants to exclude ingestion of nonsteroidal anti-inflammatory drugs. A detailed ileocolonoscopy examination was performed in all patients prior to dilatation, and multiple biopsies were taken from the strictured area to exclude malignancy and also to exclude active ulcerations that would have precluded endoscopic dilatation. Patients with Crohn's disease had no or low inflammatory disease activity.

The patients were prepared for ileocolonoscopy with 4 L of polyethylene glycol solution. All the dilations were carried out using a through-the-scope (TTS) balloon (controlled radial

expansion, CRE balloon; Microvasive Endoscopy, Boston Scientific, Natick, MA), after premedication with intravenous midazolam (Fulsed, Ranbaxy, Mumbai, India) and n-hyoscine butyl bromide (Buscopan, Cadila Healthcare, Goa, India). All the procedures were done under endoscopic guidance without the use of fluoroscopy. The diameter of the balloon was selected by the endoscopist based on his assessment of the severity of the stenosis as determined by barium examination findings as well as the endoscopy findings. The selected balloon was negotiated across the narrowed segment under endoscopic guidance and was positioned approximately equally on either side of the narrowing as determined on endoscopic vision. The balloon was inflated by using a water-filled syringe mounted on a pressure gun (Alliance inflation device, Boston Scientific) as per the manufacturer's instructions. The CRE balloon was inflated to incremental diameters and kept at each diameter for 30-90 sec. After dilatation, the patient was observed for 4 h and any abdominal pain, gastrointestinal bleeding, tachycardia, or fall in blood pressure was noted. If the patient remained asymptomatic for 6 h, clear liquids were allowed, followed by an oral diet 24 h after dilatation. Dilatation was repeated at 2-week intervals until dilatation was done using a 15-mm-diameter balloon. A liquid or mashed semisolid diet was allowed until dilation of 12 mm was achieved; thereafter, a normal diet was allowed. The endpoint of dilation was achieved when dilatation could be achieved with a 15-mm balloon and the patient had improvement in obstructive symptoms. All the patients were followed up regularly for recurrence of obstructive symptoms

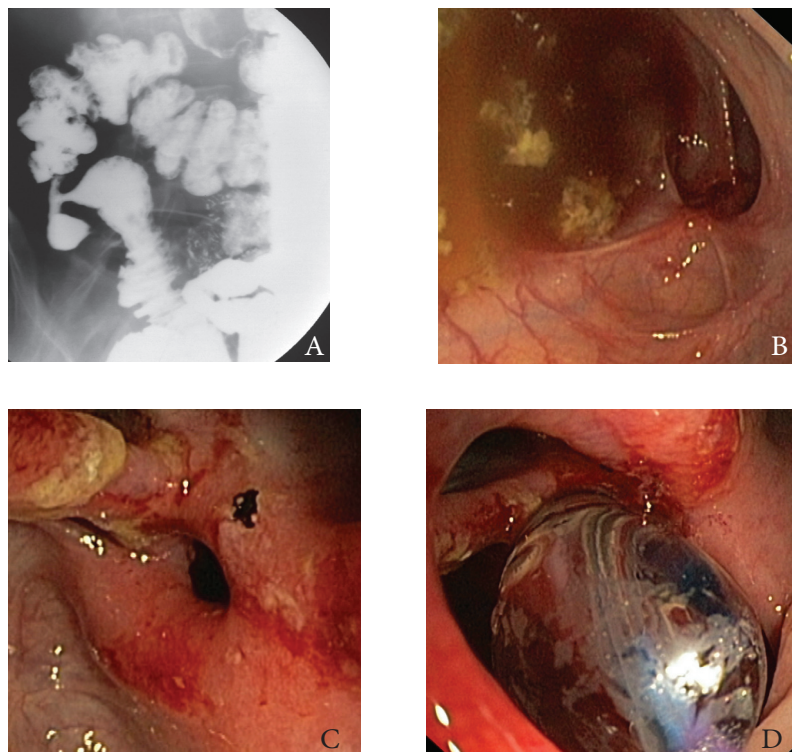


Figure 1 (A) Barium examination: short stricture in terminal ileum with deformed cecum (B) Colonoscopy in patient with treated ileocecal tuberculosis showing scarred areas in cecum (C) Ileocecal narrowing (D) Balloon dilatation of the ileocecal narrowing

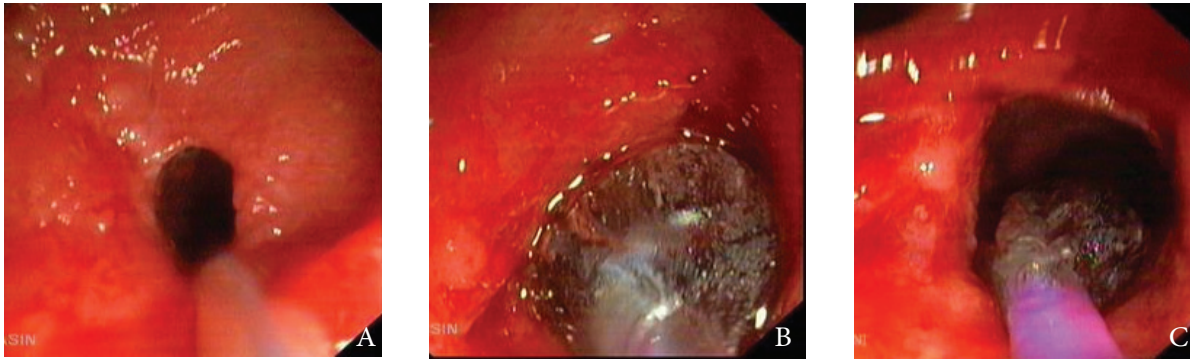


Figure 2 (A) Ileal stricture in patient with Crohn's disease (B) Balloon dilatation (C) Post-dilatation the stricture has opened up

and if required, were offered repeat EBD or surgery depending upon the clinical indications.

Statistical analysis

The descriptive data were presented as percentages for categorical variables and mean \pm SD for quantitative variables. The number of endoscopic sessions required for dilatation was compared between the two groups using *t* test.

Results

Over the last 8 years, 9 patients (6 males; mean age 39.7 ± 13.2 years) with benign terminal ileal strictures were treated by EBD using a colonoscope and TTS CRE balloon dilators. The etiology of benign ileal stricture was Crohn's disease in 5 and tuberculosis in 4 patients. The location of the ileal stricture was adjacent to the ileocecal area in 5 patients and in the terminal ileum within 10 cm of the ileocecal area in the remaining 4 patients. All the patients with Crohn's disease had no or partial response to 4 weeks of steroid therapy and there

were no mucosal ulcerations on ileoscopy. Three patients with ileal strictures due to tuberculosis underwent dilatation after completion of the ATT while one patient required dilatation 3 months after the onset of ATT. All patients had recurrent colicky abdominal pain refractory to medical therapy. The endoscope could not be negotiated across the stricture in any patient prior to dilatation.

All patients had a single ileal stricture with length of stricture ranging from 6 mm to 1.8 cm. Endoscopic balloon dilatation was successful in all 9 patients with a median number of dilating sessions required of 2 (range: 1-5 sessions). The colonoscope was negotiable across the stricture in all the patients following EBD with a 15 mm balloon. Patients with Crohn's disease required more endoscopic sessions (Fig. 1) as compared to patients with tuberculosis (Fig. 2) but this difference was not statistically significant (mean number of session being 3.0 ± 1.58 vs. 1.75 ± 0.5 sessions respectively; $p=0.1$). One patient with ileal tuberculosis had an enterolith proximal to the stricture that could be removed with dormia. There were no complications of the endoscopic procedure. There was no recurrence of symptoms in successfully treated patients of ileal tuberculosis and three patients of Crohn's disease over a follow-up period of 6 to 56 months. However, two patients with Crohn's disease had recurrence of stricture along with

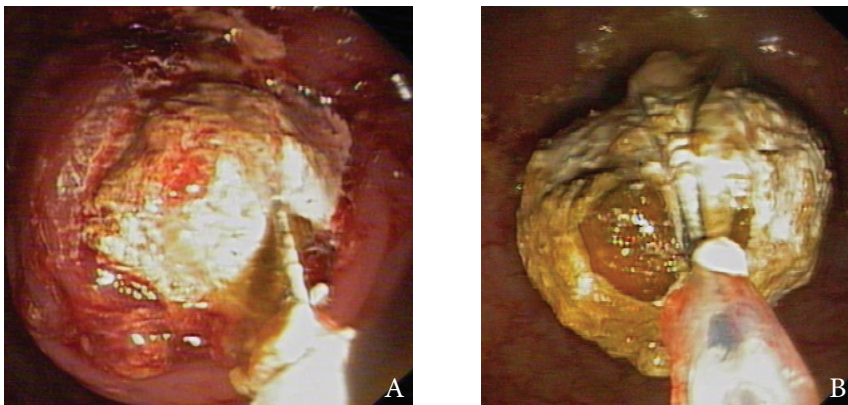


Figure 3 (A) Enterolith proximal to ileal stricture being removed by dormia basket after dilatation (B) Enterolith grasped by dormia basket and pulled into colon

symptoms. One of these patients was successfully treated with repeat dilatation whereas the other patient required surgery.

Discussion

Most experience with EBD in patients with ileal stricture is limited to patients with Crohn's disease and there is limited experience of EBD in patients with benign ileal strictures because of other etiologies [6-10]. Also, EBD for ileocolonic strictures is done under combined endoscopic and radiological guidance. In this study, we have demonstrated that EBD done only under endoscopic guidance without the use of fluoroscopy is also safe and effective in patients with terminal ileal strictures because of Crohn's disease as well as intestinal tuberculosis. In our study, the procedure was technically successful in all 9 patients and fluoroscopy was not used for dilatation in any patient. The wire-guided CRE balloon was placed across the stricture under endoscopic guidance.

Earlier studies done in patients with Crohn's disease have demonstrated EBD to be an effective alternative to surgery [6-8]. A review of the studies on EBD for strictures in Crohn's disease reported a technical success rate of 90%, and a surgical recurrence rate of 27.6% after a median follow up of 21 months [11]. However, factors influencing the outcome after EBD are not clear and studies have shown that technically successful dilation as suggested by ability to achieve an endoscopically passable residual stricture, a stricture length <4 cm and absence of ulcer in the stricture are factors predicting good outcome [12]. In the current study, all the patients had short strictures with no mucosal ulcerations and colonoscopy was negotiable across the stricture in all the patients following EBD.

Also, studies comparing the effectiveness of various diameters of the balloon as well as differences in duration of the EBD are lacking. In the current study, the maximum diameter of the balloon used was 15 mm and the CRE balloon was inflated to incremental diameters and kept at each diameter for 30-90 sec. In earlier studies on the role of EBD in patients with ileocolonic Crohn's disease, balloons with a diameter of 18-25 mm have been used. But, it has been demonstrated that the ability to achieve an endoscopically passable residual stricture is independent of the balloon's diameter [6-8,10-14]. In the current study, we also have demonstrated that a colonoscope could be negotiated across the stricture in all the patients following EBD with a 15 mm CRE balloon.

The experience of EBD in patients with ileal tuberculosis is limited to a few case reports [9,10]. In the current study of 4 patients with ileal tuberculosis, we have shown that EBD is safe and effective. Moreover, patients with tuberculosis required fewer endoscopic sessions as compared to patients with Crohn's disease but this difference was not statistically significant (mean number of session being 1.75 ± 0.5 vs. 3.0 ± 1.58 sessions respectively; $p=0.1$). Most of the patients with ileal tuberculosis respond well to ATT alone with one of the study demonstrating that ~90% patients become asymptomatic on

ATT alone with stricture disappearing in 70% of patients [15]. However, the stricture persisted in 30% of patients with some of these patients requiring surgery for bowel obstruction. It is in these subgroups of patients that EBD may be an effective alternative to surgery.

Studies have assessed the long-term efficacy of EBD in Crohn's disease also with majority of studies suggesting high recurrence rates. Thienpont *et al* reported the need for repeat dilation in 46% or surgery in 24% of patients during a follow up of 5.8 years following EBD [16]. Similarly, Hassan *et al* in a systematic review reported that 22% of patients required two dilation procedures, while 19% required more than two dilations, with surgery being ultimately required in 42% of patients [17]. In the current study also, 2/5 (40%) patients had recurrence of symptoms along with stricture formation with one patient requiring surgery. These high recurrence rates possibly do not reflect the failure of the dilatation method but rather the natural history of Crohn's disease as none of the patients with treated tubercular stricture had recurrence.

EBD has been shown to be safe with hemorrhage and perforation being the most significant complications reported. These complications have usually been reported while using large diameter balloons (25 mm) [14]. In the current study, using 15 mm balloons we did not encounter any significant complication following EBD. Small sample size and being a retrospective analysis are the limitations of the current study.

In conclusion, EBD using a 15 mm balloon without fluoroscopy is an effective, safe, and minimally invasive treatment modality for benign ileal strictures of various etiologies and patients with Crohn's disease needed more endoscopic sessions as compared to patients with tuberculosis.

Summary Box

What is already known:

- Endoscopic balloon dilatation (EBD) is safe and effective treatment modality for ileal strictures because of Crohn's disease
- EBD for ileocolonic strictures is usually done under combined endoscopic and radiological guidance

What the new findings are:

- EBD using a 15 mm balloon without fluoroscopy is an effective, safe, and minimally invasive treatment modality for benign ileal strictures of various etiologies including both Crohn's disease and tuberculosis
- Patients with Crohn's disease needed more number of endoscopic sessions as compared to patients with tuberculosis

References

1. Van Buren G 2nd, Teichgraeber DC, Ghorbani RP, Souchon EA. Sequential stenotic strictures of the small bowel leading to obstruction. *World J Gastroenterol* 2007;**13**:5391-5393.
2. Legnani PE, Kornbluth A. Therapeutic options in the management of strictures in Crohn's disease. *Gastrointest Endosc Clin N Am* 2002;**12**:589-603.
3. Benjamin SB, Cattau EL, Glass RL. Balloon dilation of the pylorus: therapy for gastric outlet obstruction. *Gastrointest Endosc* 1982;**28**:253-254.
4. Kuwada SK, Alexander GL. Long-term outcome of endoscopic dilation of non-malignant pyloric stenosis. *Gastrointest Endosc* 1995;**41**:15-17.
5. Rana SS, Bhasin DK, Chandail VS, et al. Endoscopic balloon dilatation without fluoroscopy for treating gastric outlet obstruction because of benign etiologies. *Surg Endosc* 2011;**25**:1579-1584.
6. Blomberg B, Rolny P, Jarnerot G. Endoscopic treatment of anastomotic strictures in Crohn's disease. *Endoscopy* 1991;**23**:195-198.
7. Breysem Y, Janssens JF, Coremans G, Vantrappen G, Hendrickx G, Rutgeerts P. Endoscopic balloon dilation of colonic and ileocolonic Crohn's strictures: long-term results. *Gastrointest Endosc* 1992;**38**:142-147.
8. Couckuyt H, Gevers AM, Coremans G, Hiele M, Rutgeerts P. Efficacy and safety of hydrostatic balloon dilatation of ileocolonic Crohn's strictures: a prospective long term analysis. *Gut* 1995;**36**:577-580.
9. Akarsu M, Akpınar H. Endoscopic balloon dilatation applied for the treatment of ileocecal valve stricture caused by tuberculosis. *Dig Liver Dis* 2007;**39**:597-598.
10. Bhasin DK, Sharma BC, Dhavan S, Sethi A, Sinha SK, Singh K. Endoscopic balloon dilation of ileal stricture due to tuberculosis. *Endoscopy* 1998;**30**:S44.
11. Steinecker K, Gleichmann D, Neumayer U, Glaser HJ, Tonus C. Long-term results of endoscopic balloon dilatation of lower gastrointestinal tract strictures in Crohn's disease: A prospective study. *World J Gastroenterol* 2009;**15**:2623-2627.
12. Ferlitsch A, Reinisch W, Puspok A, et al. Safety and efficacy of endoscopic balloon dilation for treatment of Crohn's disease strictures. *Endoscopy* 2006;**38**:483-487.
13. Wibmer AG, Kroesen AJ, Grone J, Buhr HJ, Ritz JP. Comparison of strictureplasty and endoscopic balloon dilatation for stricturing Crohn's disease—review of the literature. *Int J Colorectal Dis* 2010;**25**:1149-1157.
14. Gustavsson A, Magnuson A, Blomberg B, Andersson M, Halfvarson J, Tysk C. Endoscopic dilation is an efficacious and safe treatment of intestinal strictures in Crohn's disease. *Aliment Pharmacol Ther* 2012;**36**:151-158.
15. Anand BS, Nanda R, Sachdev GK. Response of tuberculous stricture to antituberculous treatment. *Gut* 1988;**29**:62-69.
16. Thienpont C, D'Hoore A, Vermeire S, et al. Long-term outcome of endoscopic dilatation in patients with Crohn's disease is not affected by disease activity or medical therapy. *Gut* 2010;**59**:320-324.
17. Hassan C, Zullo A, De Francesco V, et al. Systematic review: endoscopic dilatation in Crohn's disease. *Aliment Pharmacol Ther* 2007;**26**:1457-1464.