

Hassab's operation for bleeding gastric varices

Michael Mitsis^a, Konstantinos H. Katsanos^b, Michael Fatouros^a, Epameinondas V. Tsianos^b

Medical School of Ioannina, Greece

Catastrophic bleeding from gastric varices rupture is a life-threatening emergency. In many instances a Sengstaken-Blakemore balloon tube cannot stop the bleeding and this area is also beyond the field of sclerotherapy. Surgery seems the only definite therapy, which may offer chances for survival, no recurrent bleeding and no hepatic encephalopathy [1].

Herein we present a 67-year-old patient with alcoholic cirrhosis and concomitant hepatocellular carcinoma who was admitted due to massive upper gastrointestinal tract bleeding.

The patient was diagnosed seven years ago with severe alcoholic cirrhosis and with esophageal grade I varices. Despite medical recommendations the patient continued to drink heavily and was not compliant at all with medical treatment with beta-blockers. Furthermore the patient missed his regular follow up at the outpatient clinic. One year ago and due to continuous epigastric pain the patient was referred to the emergency department. He was admitted and diagnosed with inoperable hepatocellular carcinoma. The patient refused any kind of palliative medical therapy for his cancer and was discharged with proton pump inhibitors and beta-blockers.

On admission the patient was actively vomiting large amounts of fresh blood and was in hypovolemic shock with blood pressure at 70/40 mmHg and heart rate at 140 bpm. Hemoglobin on admission was 6.2 g/dL and platelet count at 47,000/mm³. Emergency transfusion was performed but hypovolemic shock was not managed and the patient was massively vomiting blood.

Endoscopy on emergency showed esophageal grade II varices and gastric varices (Fig. 1) with active bleeding (GOV-2 in the Sarin classification). Hassab's operation (or Hassab-Paquet procedure) was successfully performed and on the six-month follow up the patient had an acceptable quality of life.

The radical resection procedures such as terminal esophagectomy, proximal gastrectomy or cardiectomy and the stapler technique to resect *en bloc* the tortuous gastric varices, interrupt the normal esophago-gastric continuity and are too invasive

for cirrhotic patients with co-morbidities. Hassab's operation in the management of bleeding varices consists basically of gastro-esophageal decongestion and splenectomy. Perhiatal devascularization of lower esophagus, complete separation of the stomach from its bed, ligation of the left gastric artery at the lesser curvature, peritonization of greater curvature and suction drainage of the splenic bed are essential technical points. Hassab's operation is effective in controlling bleeding by portal vein flow restoration and in hepatic encephalopathy correction

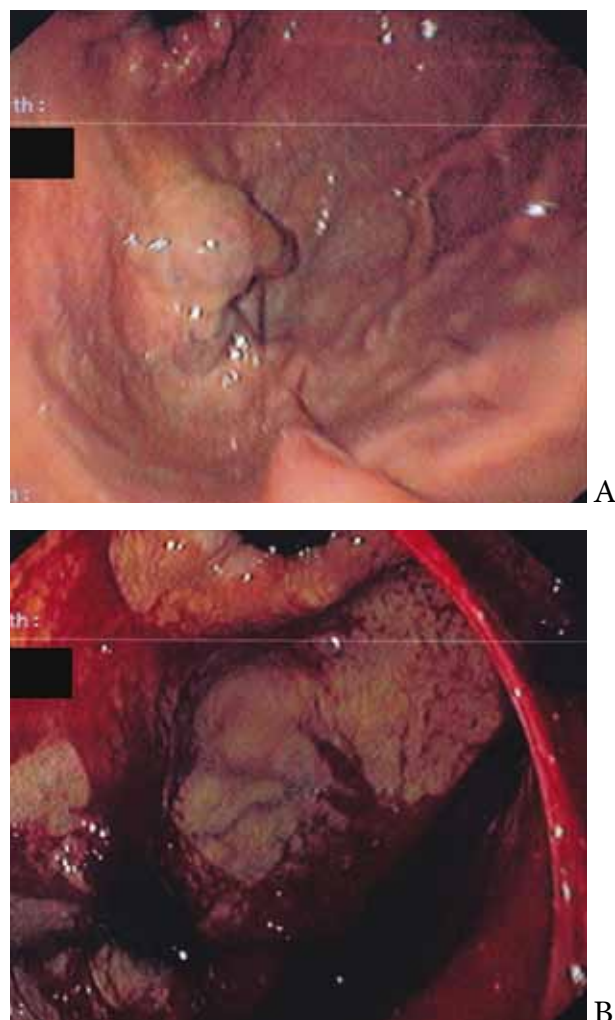


Figure 1 Gastric varices in a cirrhotic patient with concomitant hepatocellular carcinoma located at the greater curvature of the fundus of the stomach (A). A view of the same varices with active massive bleeding (B)

^aDepartment of Surgery (Michael Mitsis, Michael Fatouros);

^b1st Department of Internal Medicine & Hepato-Gastroenterology Unit (Konstantinos H. Katsanos, Epameinondas V. Tsianos), Medical School of Ioannina, Greece

Conflict of Interest: None

Correspondence to: Prof. Epameinondas V. Tsianos, MD, Ph.D, FEBGH, AGAF, Professor of Internal Medicine, Department of Internal Medicine, Medical School, University of Ioannina, Leoforos Panepistimiou, 45110 Ioannina, Tel: ++30-26510-07501, Fax:++30-26510-07016, e-mail: etsianos@uoi.gr

Received 21 December 2011; accepted 9 January 2012

by ligation of a massive splenorenal shunt with better quality of life and survival and no or minimal encephalopathy [2].

Doppler color flow imaging for demonstrating changes in portal hemodynamic after Hassab procedure showed that the operation can decrease blood flow in the gastrosplenic region and enhance liver perfusion [3,4].

Of note, a study demonstrated a hospital mortality of 16.5% and an overall mortality of 29.5%. The results of that study indicated also that immediate sclerotherapy of bleeding oesophageal varices improved the prognosis, but it should be undertaken only in centers equipped for emergency endoscopy by an experienced immediately available team [5].

Several modifications of the Hassab procedure have been described including an interesting case of a 36-year-old man with posthepatic liver cirrhosis and recurrent thrombocytopenia associated with symptomatic enlargement of an accessory spleen. Two years after splenectomy and gastroesophageal devascularization with accessory splenectomy and cholecystectomy the patient's platelet count was normalized and no further variceal bleeding was observed on follow up [6]. A modified Hassab procedure in the management of bleeding esophageal varices may be applied with a modified gastroesophageal decompression, and splenectomy can be performed in patients who need immediate surgical intervention for variceal bleeding [7].

Finally, it has been demonstrated that Hassab's operation, in addition to hepatectomy, might reduce the risk of variceal hemorrhage after hepatectomy in cirrhotic patients with hepatocellular carcinoma [8].

Therapy of cirrhotic and massively bleeding patients with hepatocellular cancer is difficult and treatment options consist of palliation methods aiming to escape the immediate and sometimes inevitable fatal outcome in the vast majority of cases. Recently, the Baveno V consensus definitions on variceal bleeding and failure to control bleeding, clearly state that the development of hypovolemic shock and a 3 g drop in Hb (9% drop of Ht) within any 24-h period, if no transfusion is administered, are signs of alarm. Treatment of acute bleeding from varices and upper endoscopy must be attempted as soon as possible after admission, preferably within 12 h. The Baveno V consensus clearly states that the choice of treatment should be based on local resources and expertise, patient preference and characteristics, side effects, and contra-indications and for patients who have bled from isolated gastric varices type I (IGV1) or gastro-oesophageal

varices type 2 (GOV2) N-butyl-cyanoacrylate or TIPS are recommended. On patients in whom beta-blockers are contraindicated or fail and who cannot be managed by non-shunt therapy, TIPS or surgical shunts should be considered. However, treatment of gastric varices represents an area requiring further study [9].

To conclude, we herein presented a case of a patient with life-threatening bleeding gastric varices who was successfully operated with the Hassab procedure. We believe that careful patient selection, collaboration of gastroenterologists and surgeons and prompt decision regarding the timing of operation may optimize survival and quality of life of these patients.

References

1. Yu TJ, Cheng KK, Lai ST, et al. A new operation for the management of gastric varix bleeding. *Zhonghua Yi Xue Za Zhi* 1989;**43**:49-56.
2. Hassab MA. Gastro-esophageal decompression and splenectomy GEDS (Hassab), in the management of bleeding varices. Review of literature. *Int Surg* 1998;**83**:38-41.
3. Zhou YB. Doppler color flow imaging for demonstrating changes in portal hemodynamic after Hassab procedure. *Zhonghua Wai Ke Za Zhi* 1992;**30**:295-296.
4. Mishin I, Ghidirim G, Gagauz I, Zastavitsky G. Portal vein flow restoration and hepatic encephalopathy correction by ligation of a massive splenorenal shunt and splenectomy during Hassab-Paquet procedure. *J Gastrointest Liver Dis* 2007;**16**:120-121.
5. Paquet KJ, Kalk JF, Koussouris P. Immediate sclerotherapy of acute hemorrhaging esophageal varices in emergency endoscopy. A prospective study. *Dtsch Med Wochenschr* 1986;**111**:668-671.
6. Mishin I, Ghidirim G. Accessory splenectomy with gastroesophageal devascularization for recurrent hypersplenism and refractory bleeding varices in a patient with liver cirrhosis: report of a case. *Surg Today* 2004;**34**:1044-1048.
7. Wu YK, Wang YH, Tsai CH, Yung JC, Hwang MH. Modified Hassab procedure in the management of bleeding esophageal varices—a two-year experience. *Hepatogastroenterology* 2002;**49**:205-207.
8. Sugo H, Fujiwara N, Yoshimoto J, Miwa K, Ishizaki Y. Additional Hassab's operation for esophagogastric varices in cirrhotic patients with resectable hepatocellular carcinoma. *Hepatogastroenterology* 2008;**55**:1686-1690.
9. de Franchis R, Baveno V Faculty. Revising consensus in portal hypertension: Report of the Baveno V consensus workshop on methodology of diagnosis and therapy in portal hypertension. *J Hepatol* 2010;**53**:762-768.