

Balloon dilatation of ileo-colonic anastomosis in Crohn's disease

Konstantinos H. Katsanos^a, Paul J. Rutgeerts^b, Gert Van Assche^b, Epameinondas V. Tsianos^a

^aUniversity Hospital of Ioannina Greece, ^bKatholic University of Leuven, Belgium

Endoscopic dilatation of Crohn's disease-related strictures is an alternative to surgical resection in selected patients. In addition, post-surgical stenosis is not infrequent in patients undergoing ileo-colonic anastomosis.

Dilatation of ileo-colonic anastomosis is performed with a through the scope balloon (TTS diameter 18mm) and requires general anesthesia, endoscopic experience and careful patient evaluation [1]. Complications include sealed perforations, retroperitoneal perforations and intraperitoneal perforations [2].

Dilatation time must not exceed 2 minutes in total. For mild stenosis the 1-step procedure is advised with 7Atm for 2 min. For severe stenosis the 3-step procedure is advised starting with 3.5 Atm (1min), then 5Atm (0.5 min) and finally 7Atm (0.5 min).

The largest ever reported experience with 237 dilatations in 138 patients confirms that long-term efficacy of endoscopic dilatation of Crohn's disease outweighs the complication risk. Neither active disease at the time of dilatation nor medical therapy afterwards predicts recurrent dilatation or surgery [3].

The patient presented herein was diagnosed with Crohn's disease and developed post-surgery severe stenosis at the ileo-colonic anastomosis. Despite many attempts the scope could not pass through this stenosis. Magnetic resonance imaging confirmed a 3cm long stenosis. On an outpatient basis and under general anesthesia a 3-step procedure was successfully applied and the insertion of the colonoscope at the neo-terminal ileum was then possible (Fig. 1).

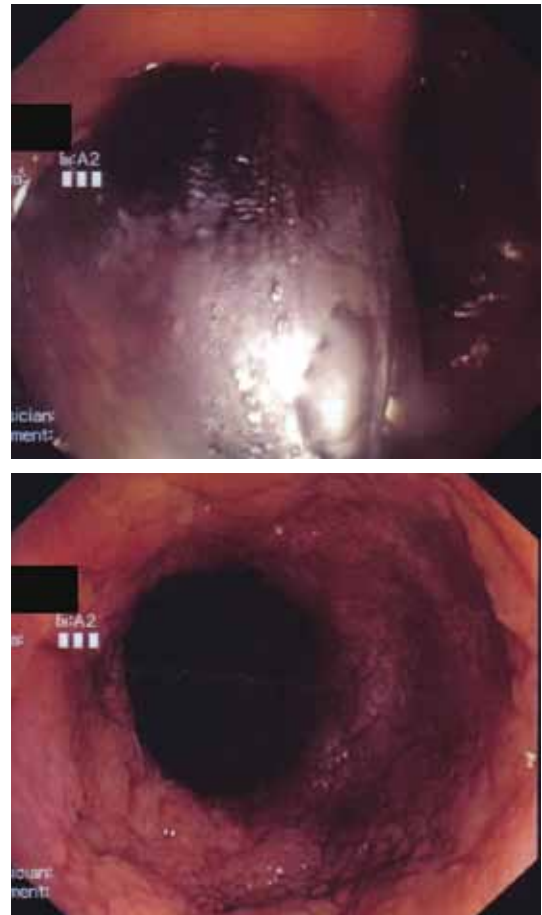


Figure 1 Balloon dilatation of ileo-colonic anastomosis in a patient with Crohn's disease

^a1st Department of Internal Medicine & Hepato-Gastroenterology Unit, Medical School, University of Ioannina, Greece (Konstantinos H. Katsanos, Epameinondas V. Tsianos);

^bDepartment of Gastroenterology, University Hospital Gasthuisberg, Catholic University of Leuven, Belgium (Paul J. Rutgeerts, Gert Van Assche)

Conflict of Interest: None

Correspondence to: Prof. Epameinondas V. Tsianos, MD, PhD, FEBGH, AGAF, Professor of Internal Medicine, Department of Internal Medicine, Medical School, University of Ioannina, Leoforos Panepistimiou, 45 110 Ioannina, Greece
Tel:++30-26510-07501, Fax:++30-26510-07016,
e-mail: etsianos@uoi.gr

Received 7 December 2011; accepted 2 January 2012

References

1. Van Assche G, Vermeire S, Rutgeerts P. Endoscopic therapy of strictures in Crohn's disease. *Inflamm Bowel Dis* 2007;**13**:356-358.
2. Couckuyt H, Gevers AM, Coremans G, Hiele M, Rutgeerts P. Efficacy and safety of hydrostatic balloon dilatation of ileocolonic Crohn's strictures: a prospective longterm analysis. *Gut* 1995;**36**:577-580.
3. Thienpont C, D'Hoore A, Vermeire S, et al. Long-term outcome of endoscopic dilatation in patients with Crohn's disease is not affected by disease activity or medical therapy. *Gut* 2010;**59**:320-324.